



LIVE

Surgey

Dr. Jung-Hyun Park

2024. 05. 17 (FRI.)



[Case Preview]

Immediate implant placement
and immediate loading with bone OSTEON™ Xeno Collagen

Patient Information

Age : 49

Sex : Male

Chief Complaint

My gums are generally not good.

I think my teeth are shaking

Past Dental History

He hasn't received dental treatment for 10 years.

Present illness

Severe Periodontitis

Severe Bone loss on #14 #15 #16 #17#24
#26 #27

Severe mobility on #31 #32 #41 #42 #43

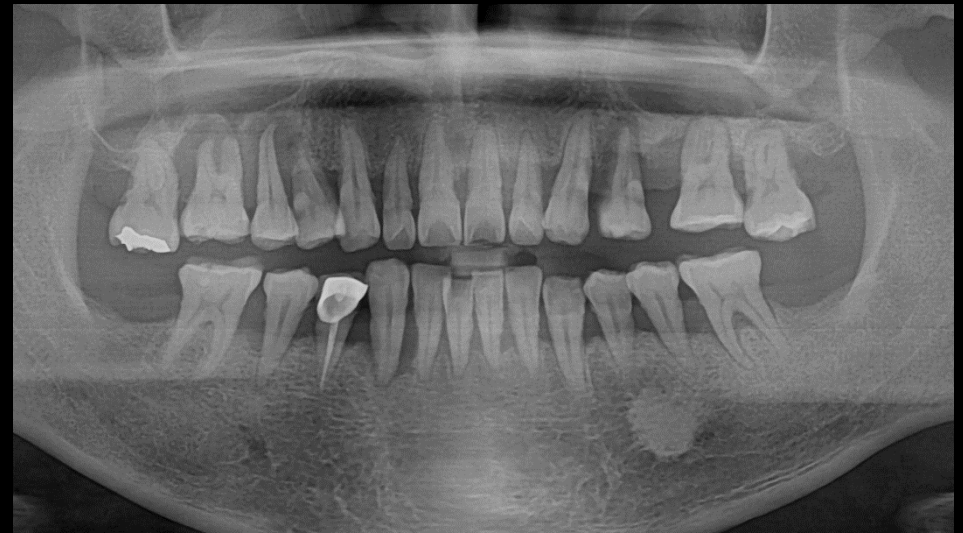
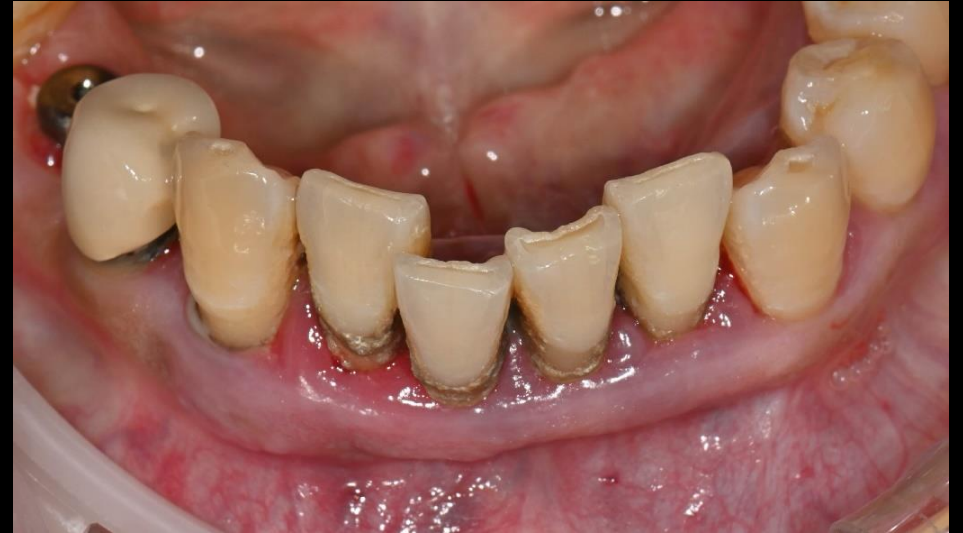Today's Surgery Plan

Surgical Plan

- Extraction on #31,#32 #41,#42,#43
- Implant placement on #32, #43
- Bone graft on extraction socket of #32,#43

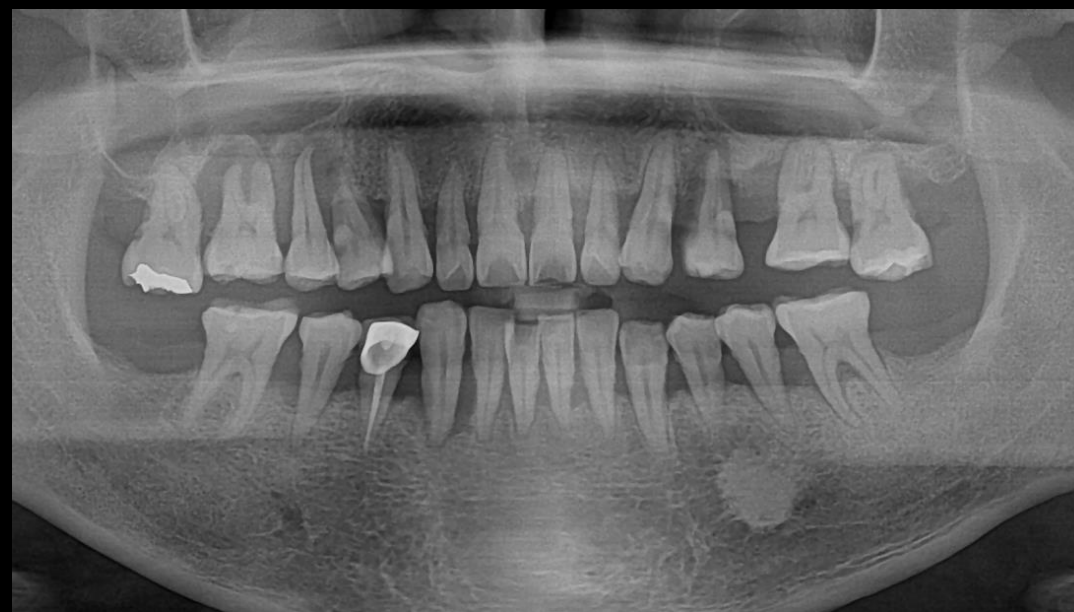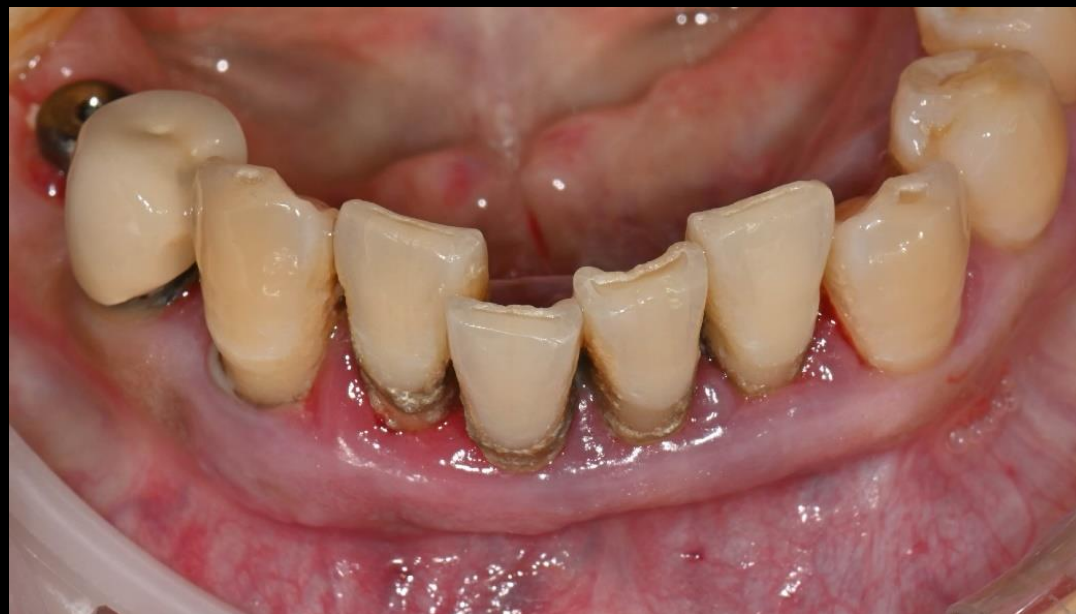Prosthetic Plan

- 5 unit bridge of #32= #43 on 2 implant #32,#43



Pt. Byun (49/Male)

Oral exam

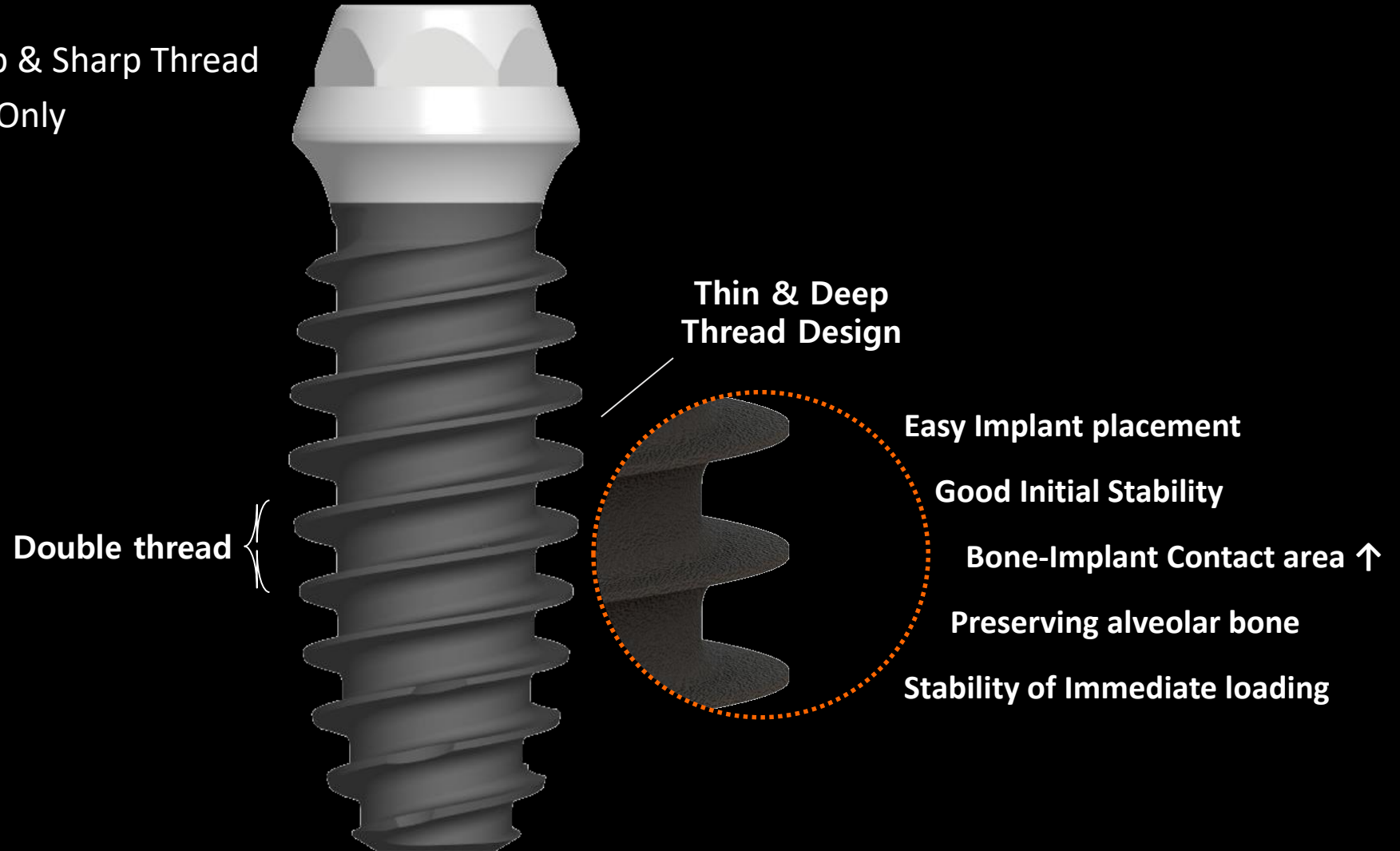


bright Tissue Level

For **Simplify Surgical Procedure**

- Thin, Deep & Sharp Thread
- Final Drill Only

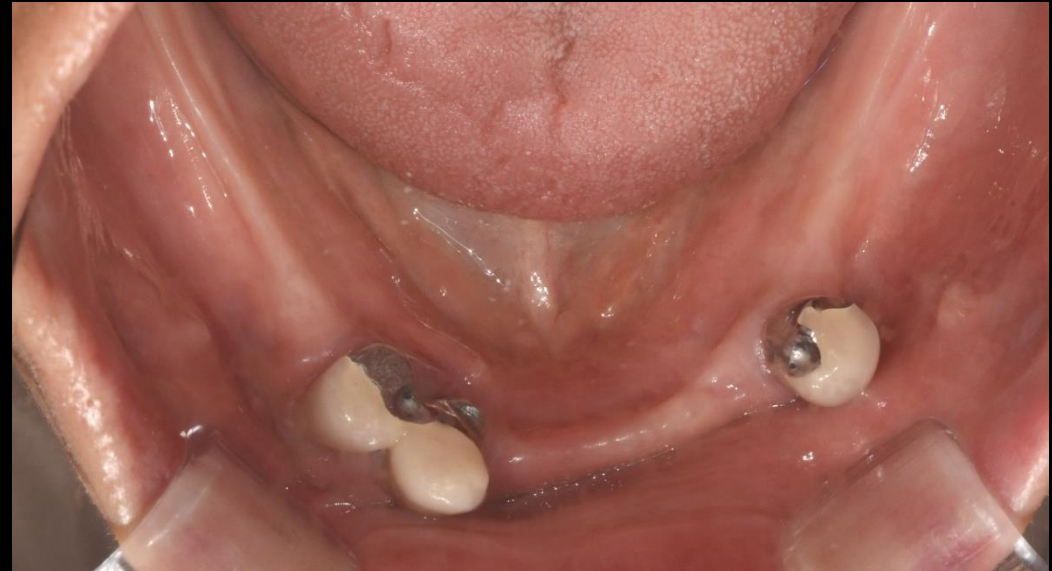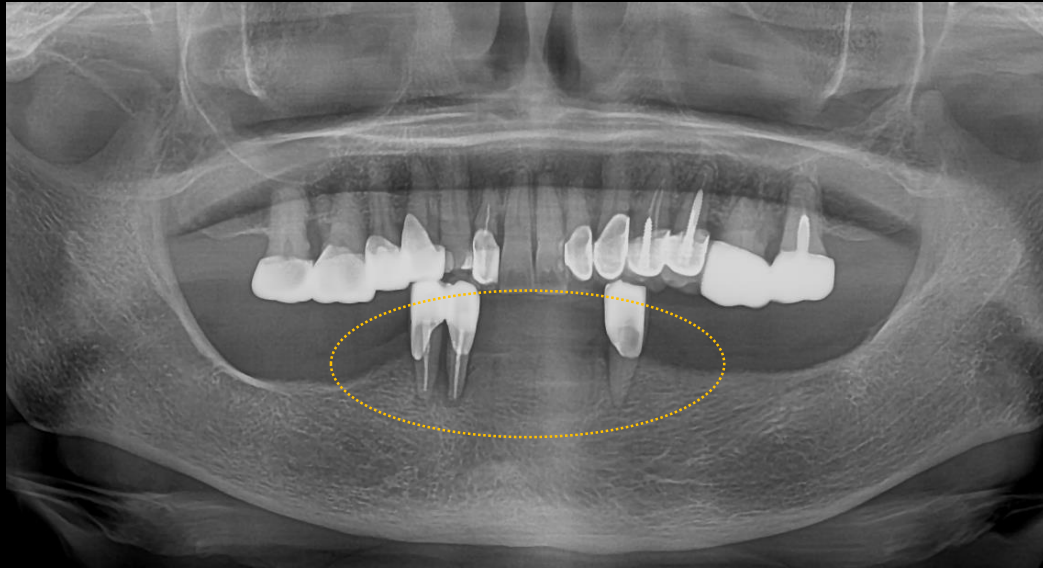
For **Simplify Prosthetic Procedure**



Similar case

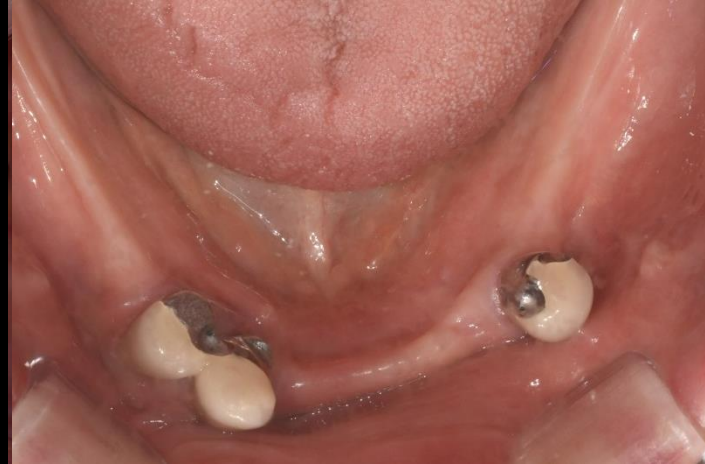Implantation on narrow and short ridge with **bright** Tissue Level

Pre-op

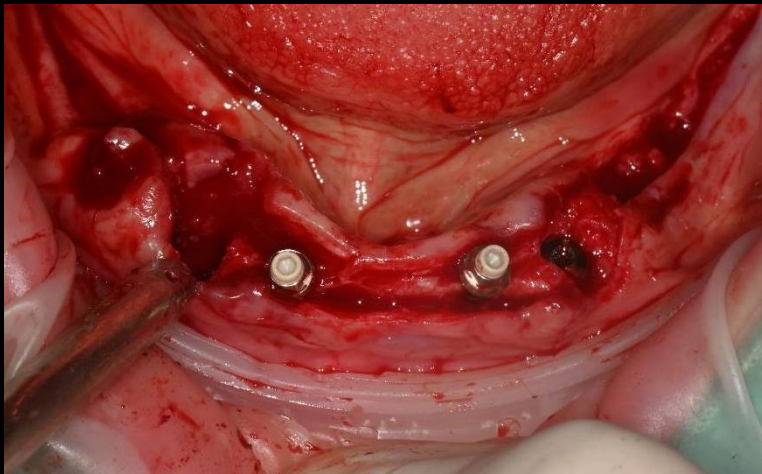


Similar case

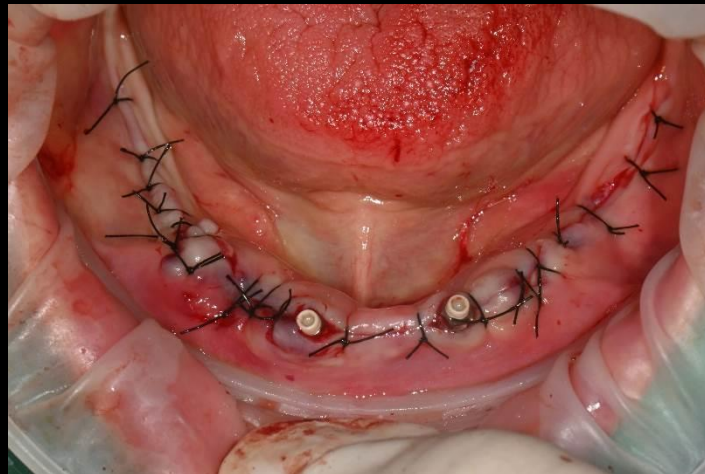
Implantation on narrow ridge with **bright Tissue Level**



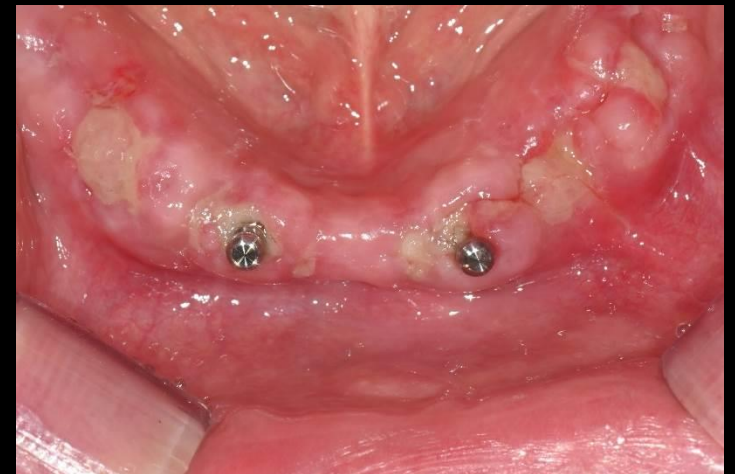Pre-op



op



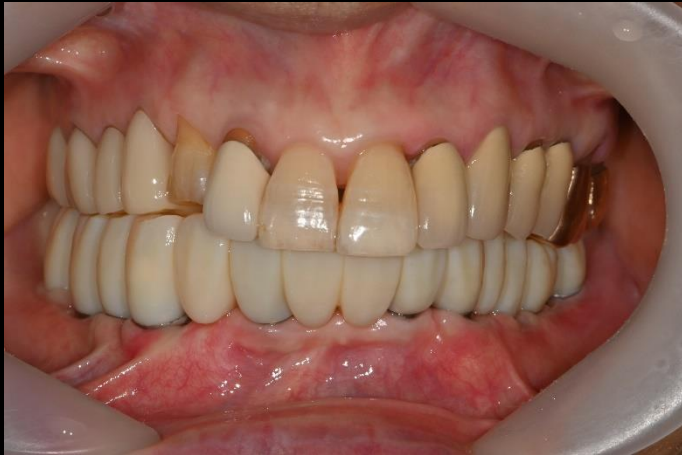Post-op



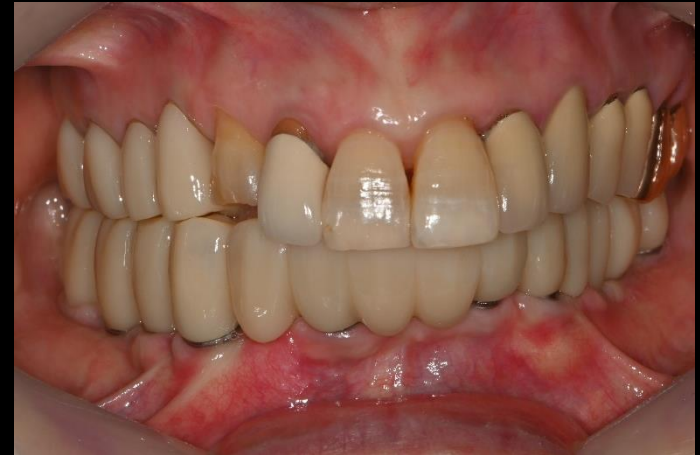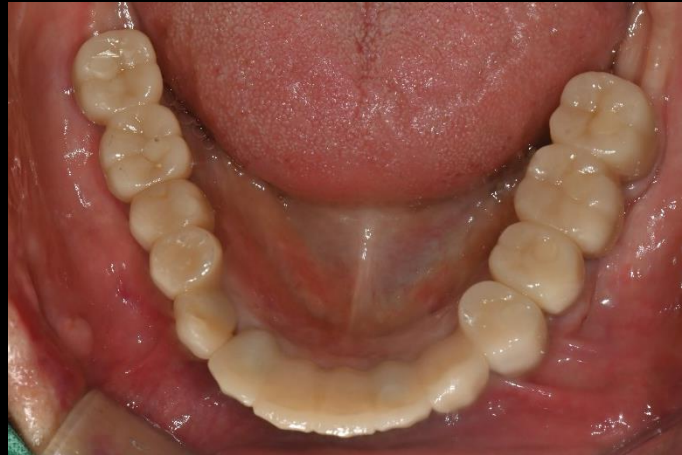3 weeks later

Similar case

Implantation on narrow ridge with **bright** Tissue Level



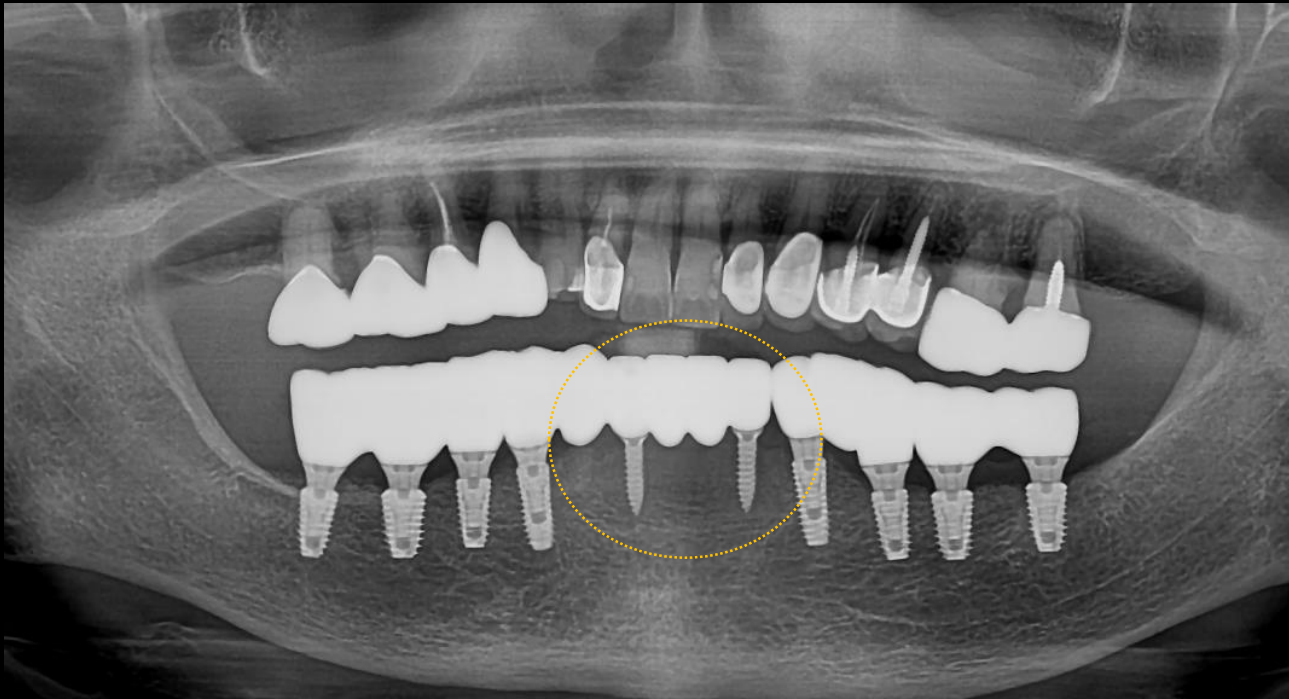
Provisionalization



Final Prosthesis

Similar case

Implantation on narrow and short ridge with **bright** Tissue Level



Final Prosthesis

- Fully digital technique (modeless)
- Copy of temporary prosthesis

