



LIVE & Follow up

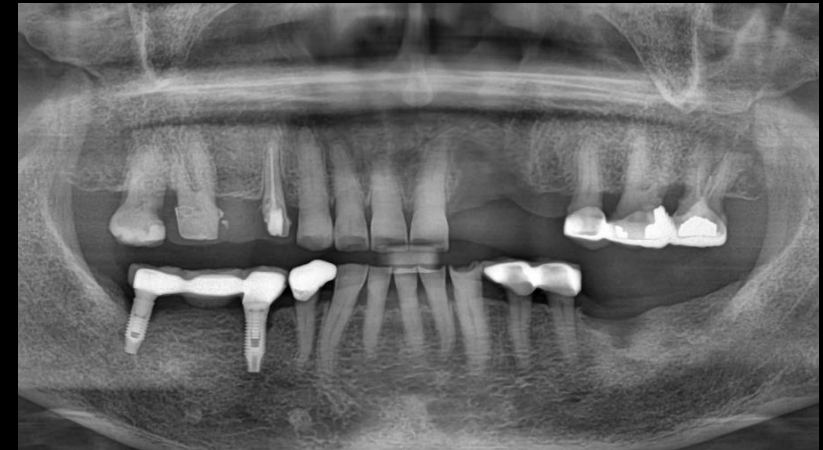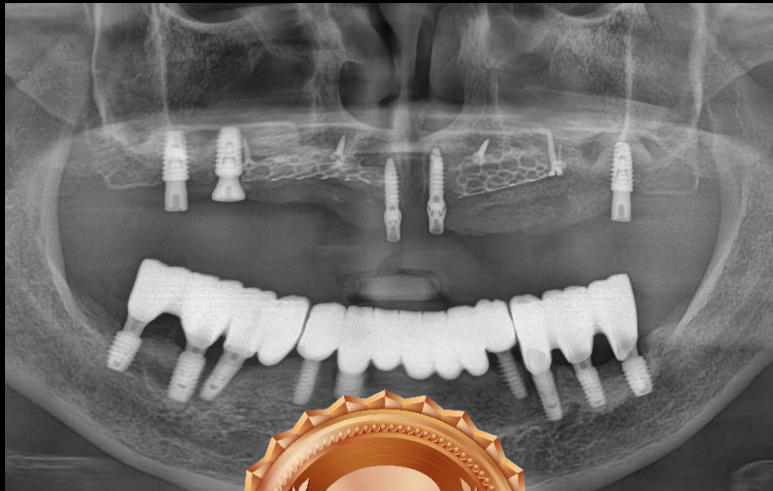RATINGS AWARD 2023

Moderator Dr. Sang-Chul Lim

2024.02.02. (Fri)

 **LIVE** & Follow up

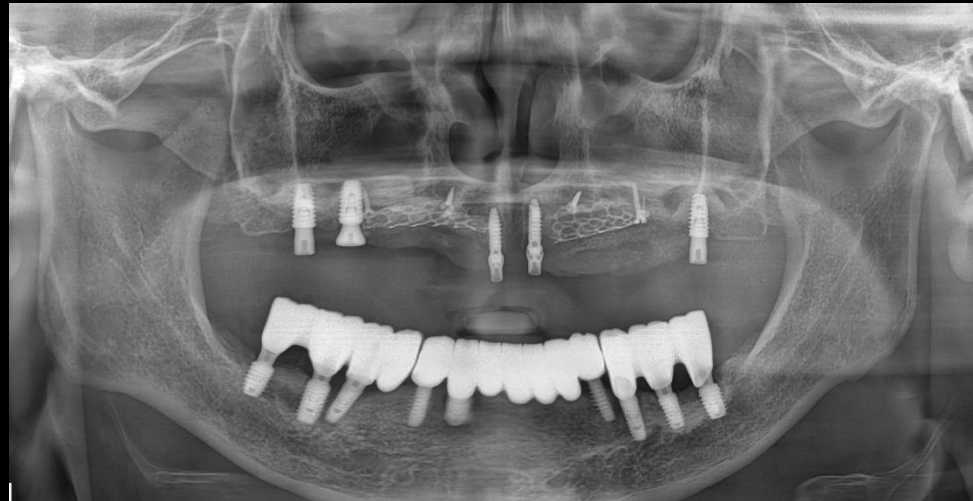
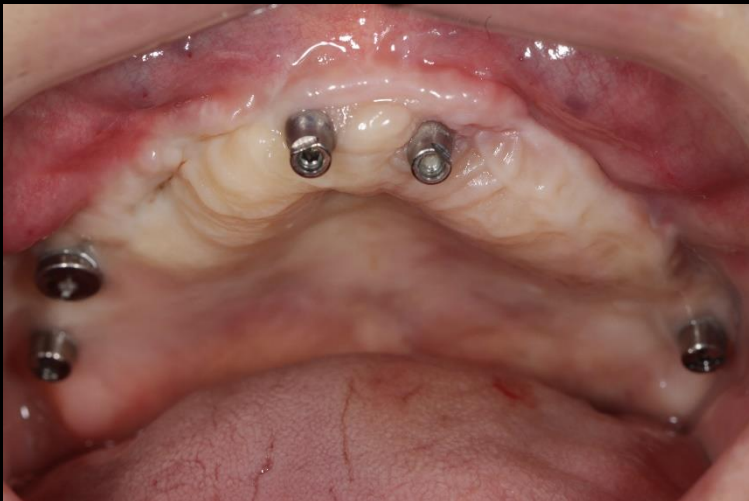2023 Ratings Best 3



LIVE & Follow up 3rd Ratings

Aired on June 2nd

Overcoming severely defective ridge with Staged process concept



Dr. SM Chung

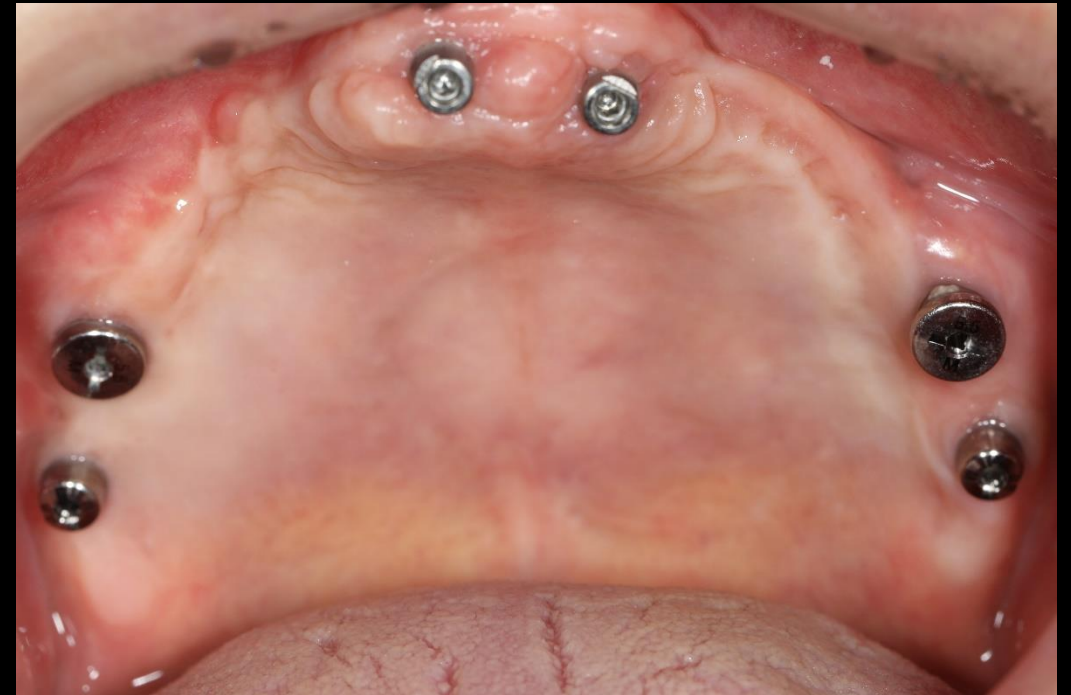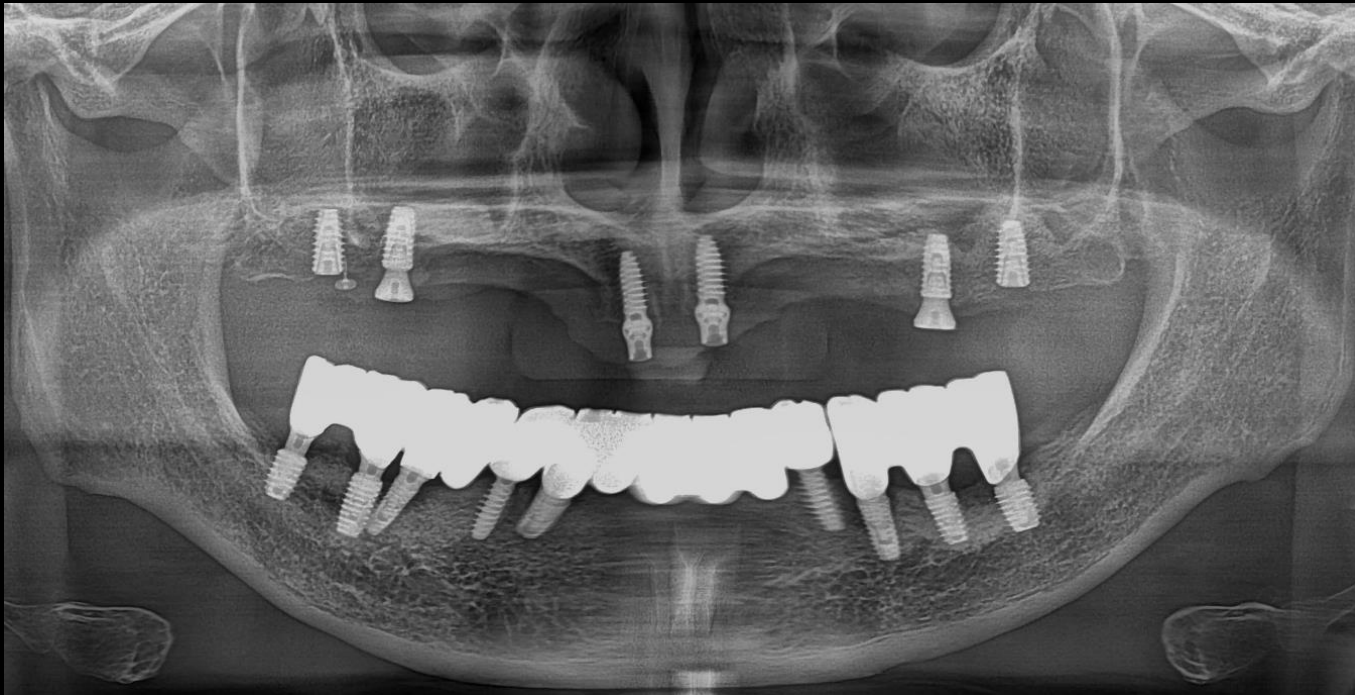
Aired on June 2nd

3rd Re-view

Overcoming severely defective ridge with Staged process concept

Past Dental History

Maxillary GBR using mesh plate



Pre-op

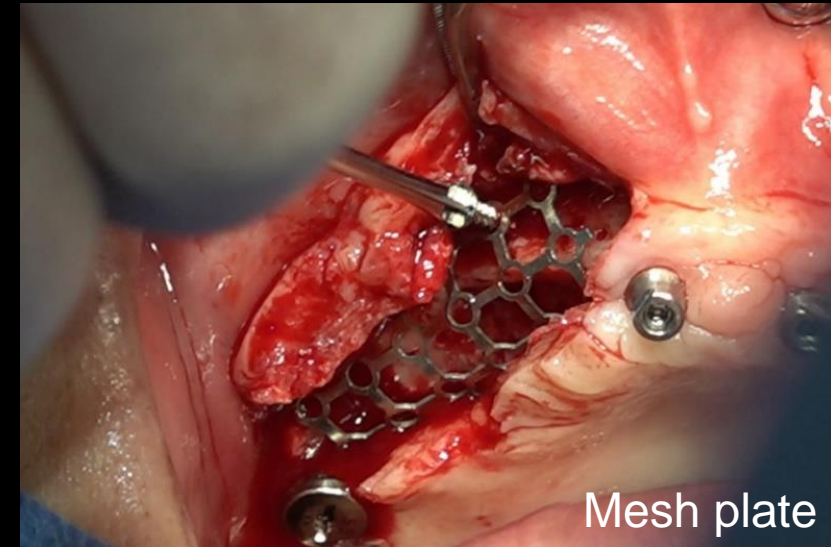
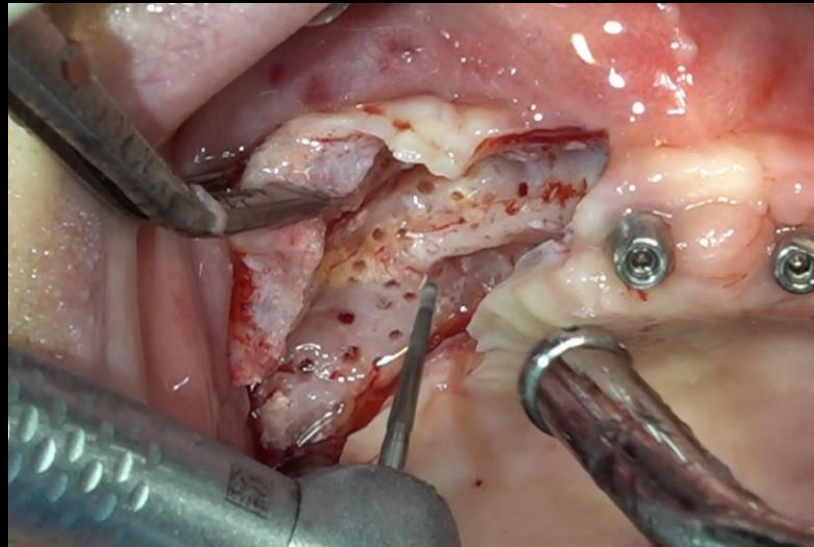
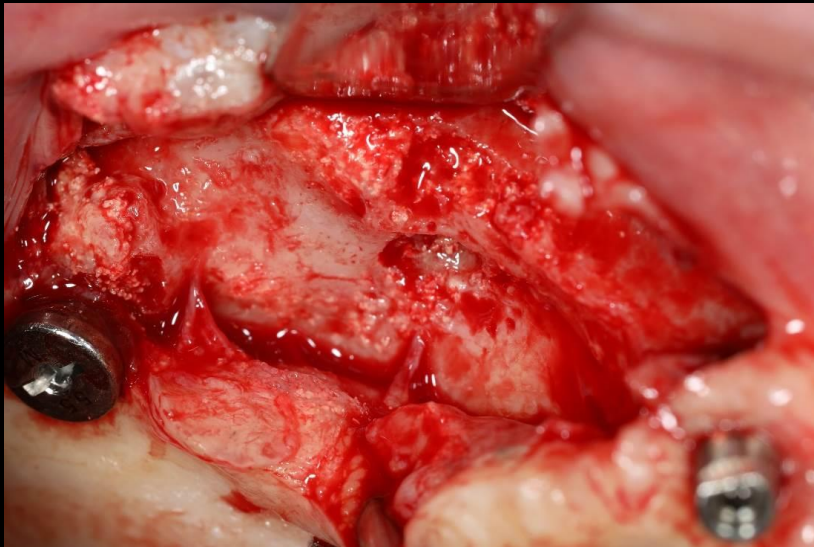
Aired on June 2nd

3rd Re-view

Overcoming severely defective ridge with Staged process concept

Past Dental History

Maxillary GBR using mesh plate



Mesh plate

#10 Surgery

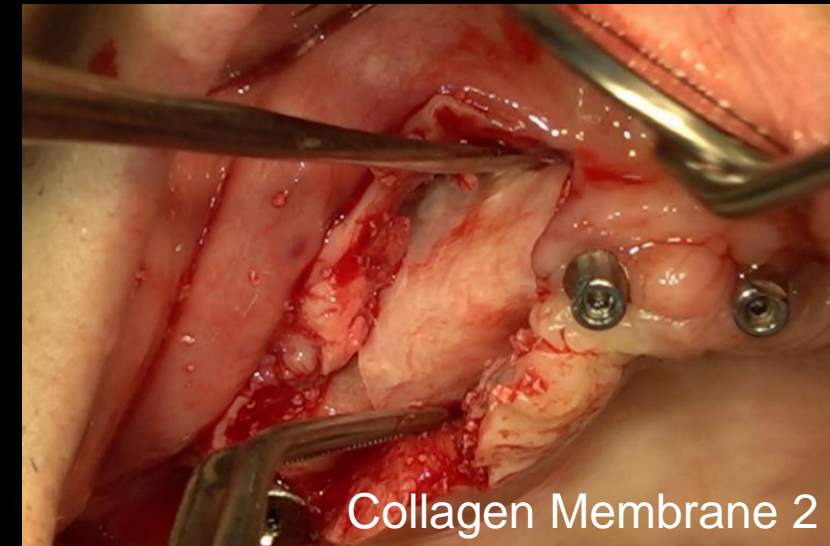
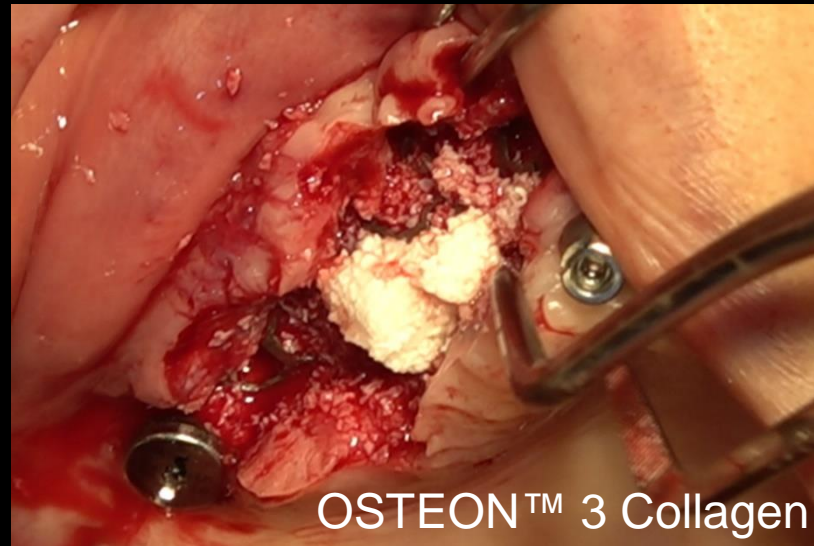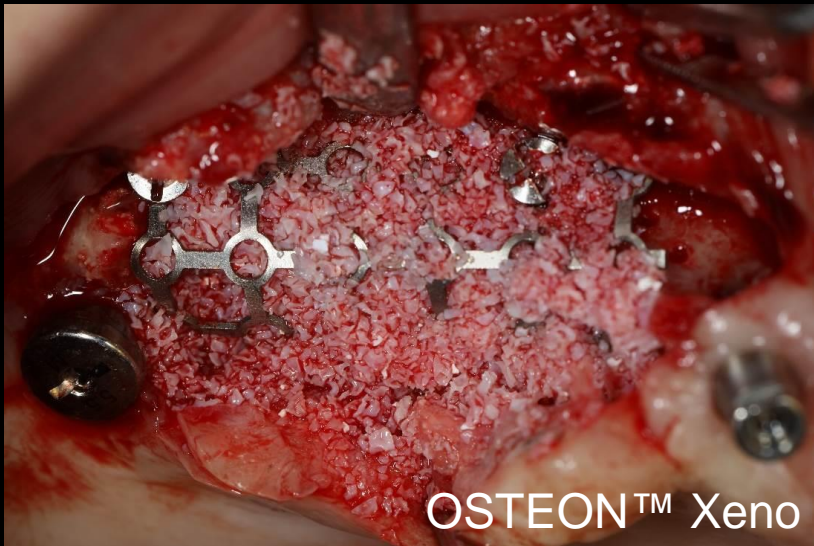Aired on June 2nd

3rd Re-view

Overcoming severely defective ridge with Staged process concept

Past Dental History

Maxillary GBR using mesh plate



#10 Surgery

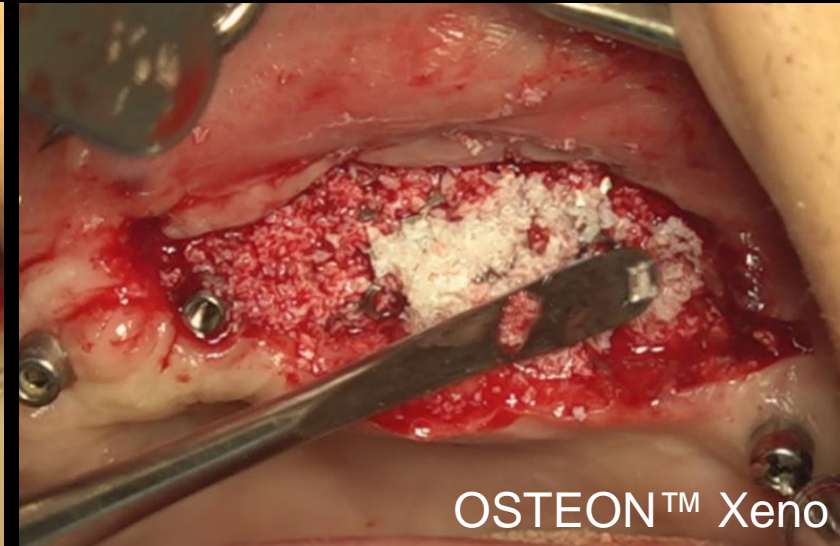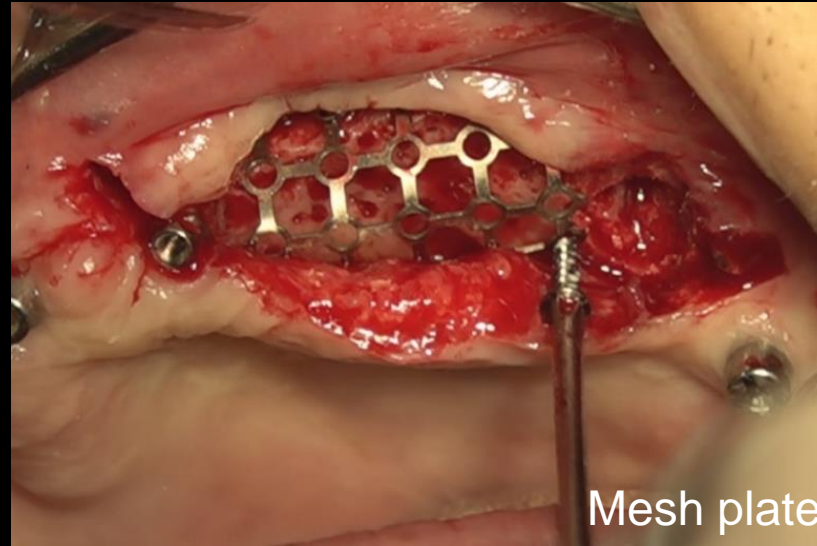
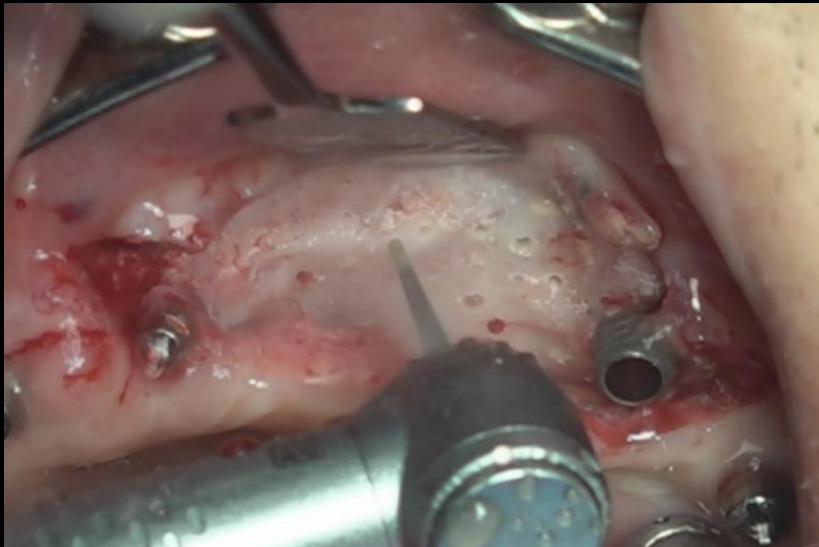
Aired on June 2nd

3rd Re-view

Overcoming severely defective ridge with Staged process concept

Past Dental History

Maxillary GBR using mesh plate



#20 Surgery

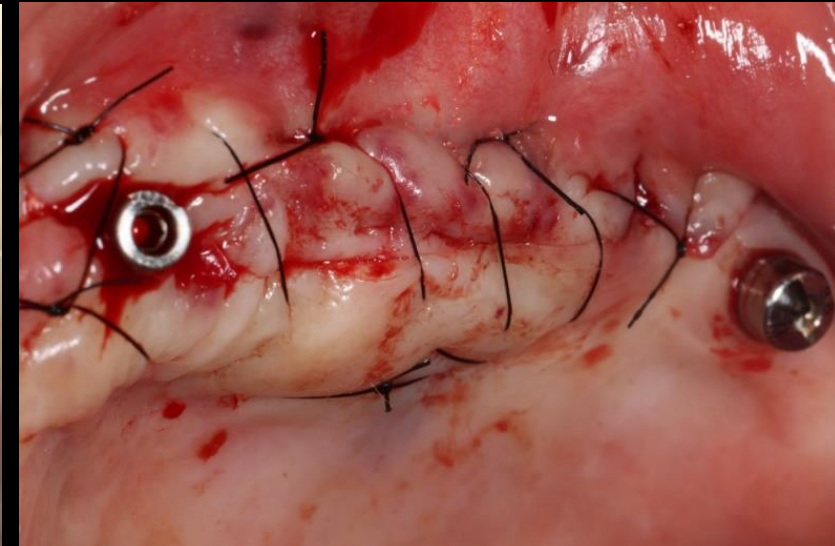
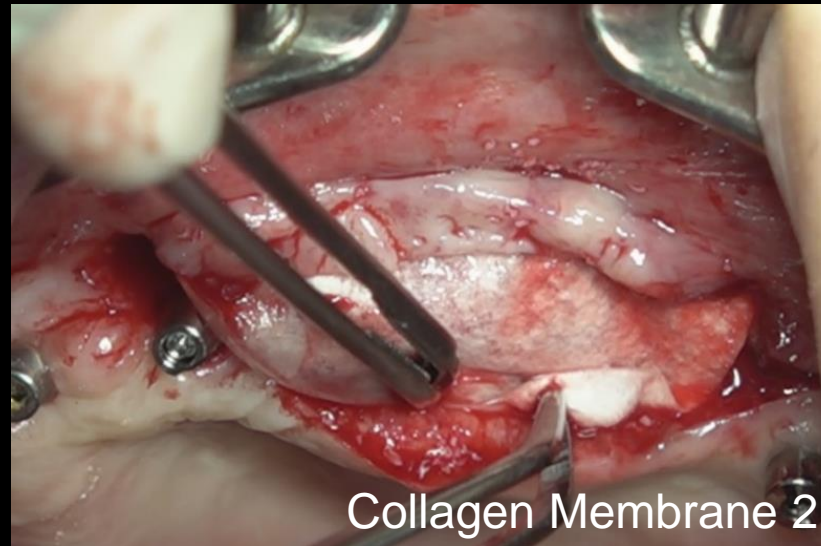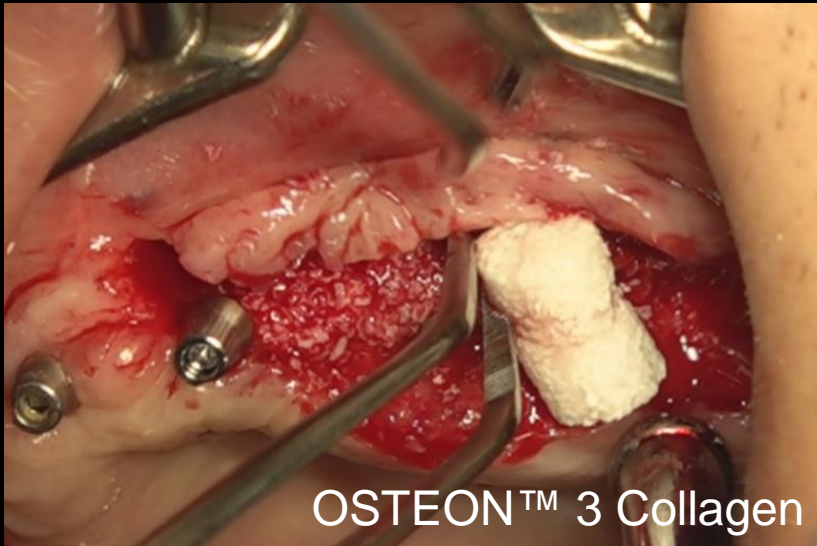
Aired on June 2nd

3rd Re-view

Overcoming severely defective ridge with Staged process concept

Past Dental History

Maxillary GBR using mesh plate

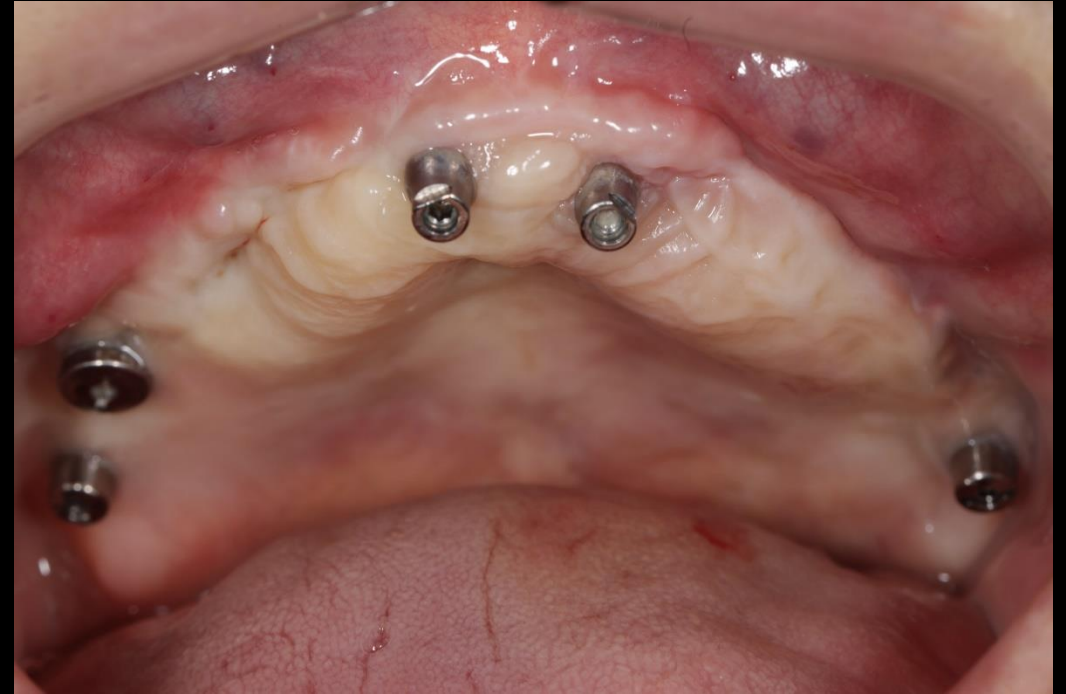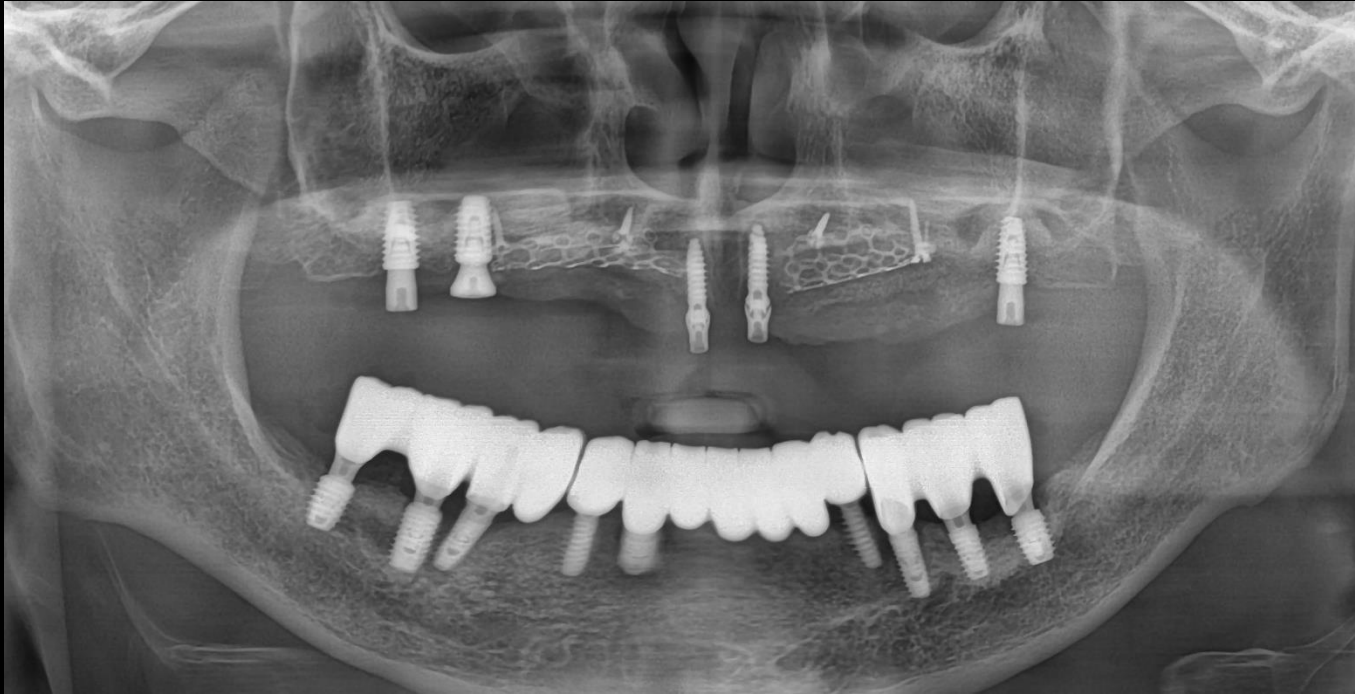


#20 Surgery

Aired on June 2nd

3rd Re-view

Overcoming severely defective ridge with Staged process concept

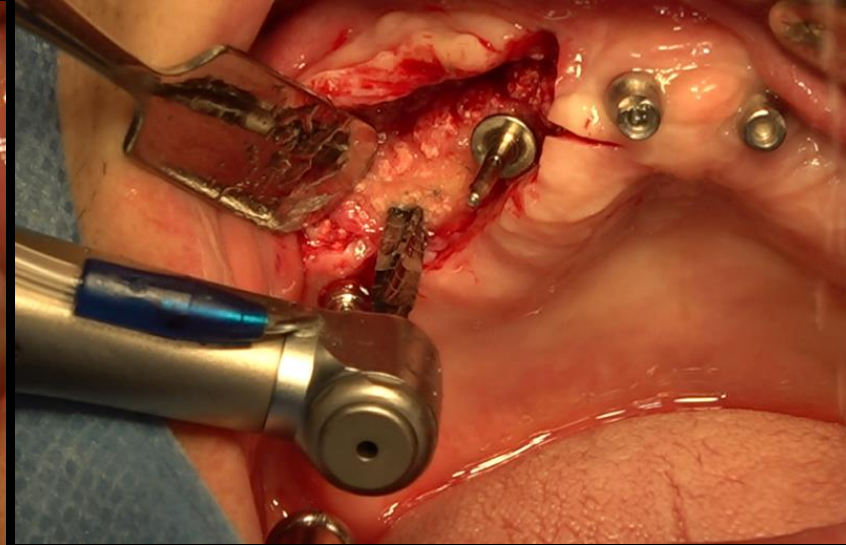
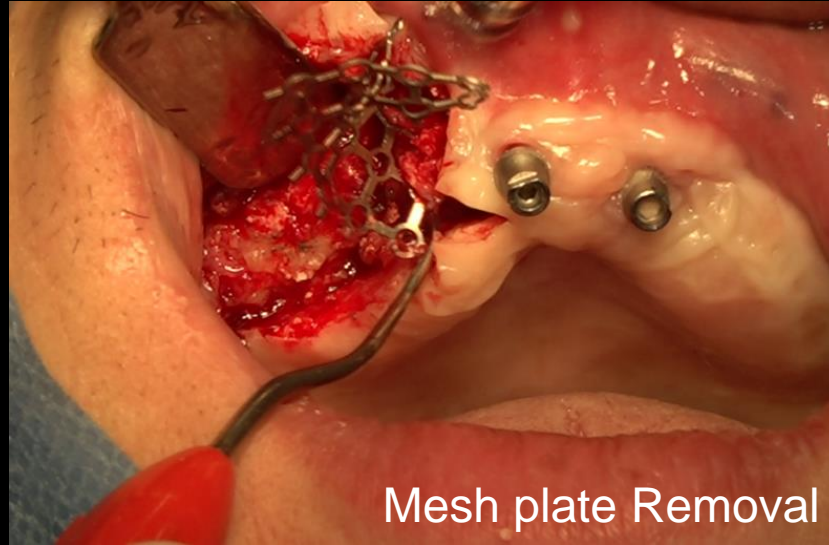
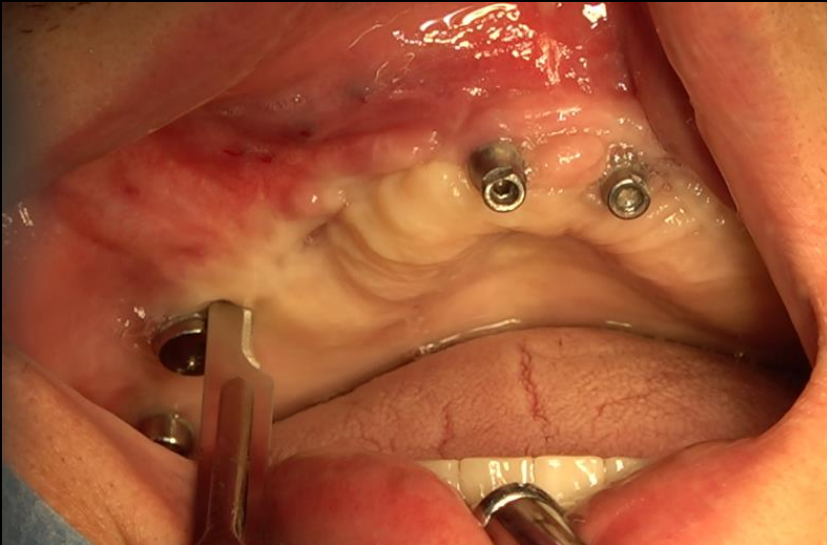


Pre-op

Aired on June 2nd

3rd Re-view

Overcoming severely defective ridge with Staged process concept

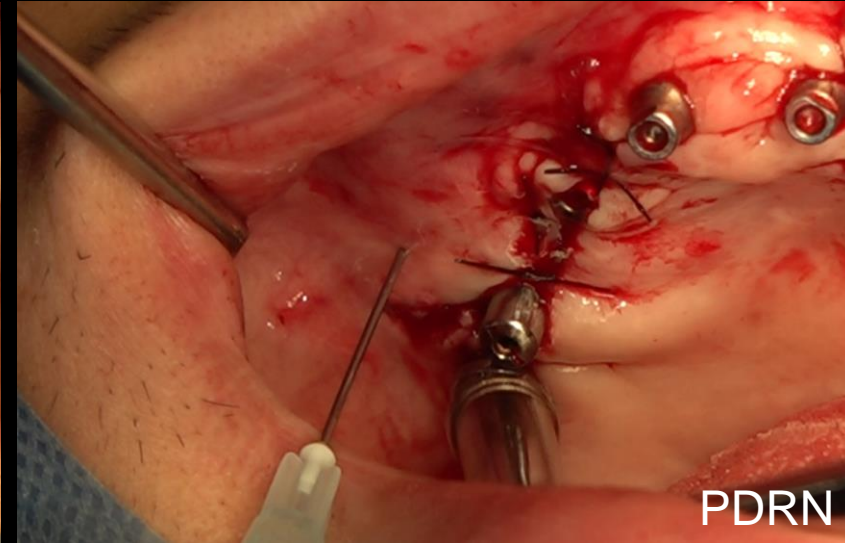
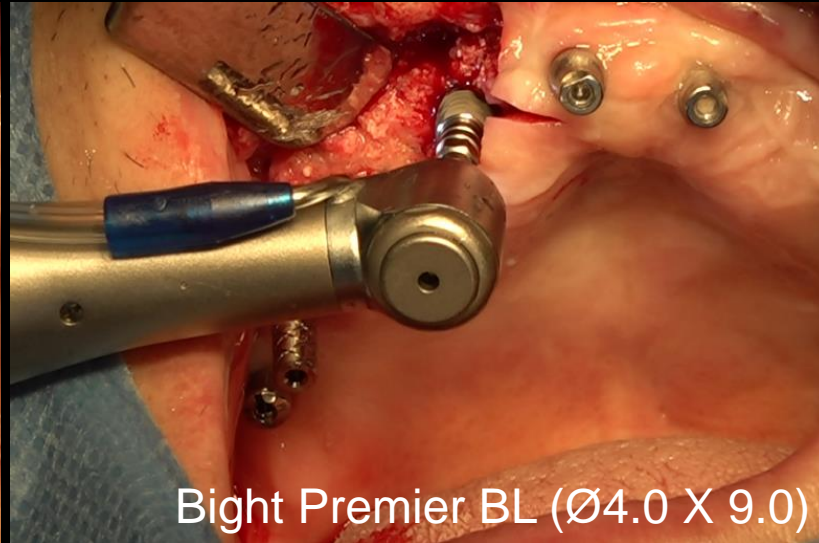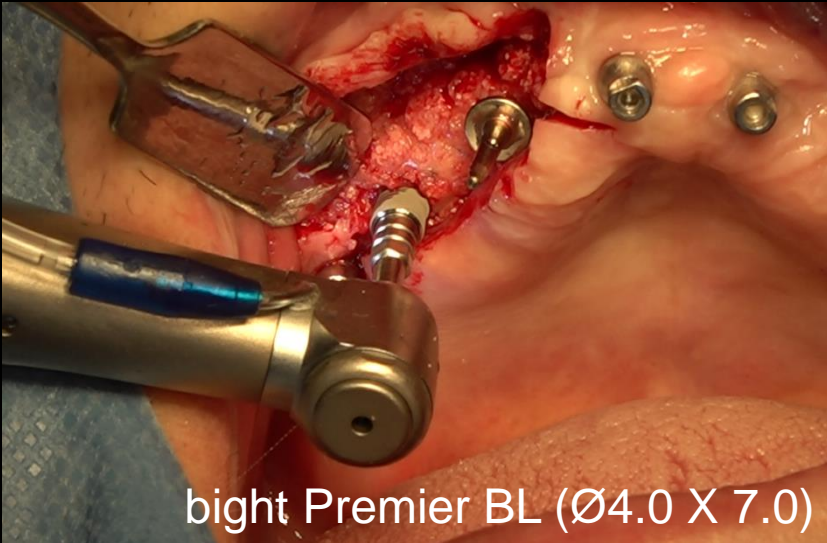


#10 Surgery

Aired on June 2nd

3rd Re-view

Overcoming severely defective ridge with Staged process concept

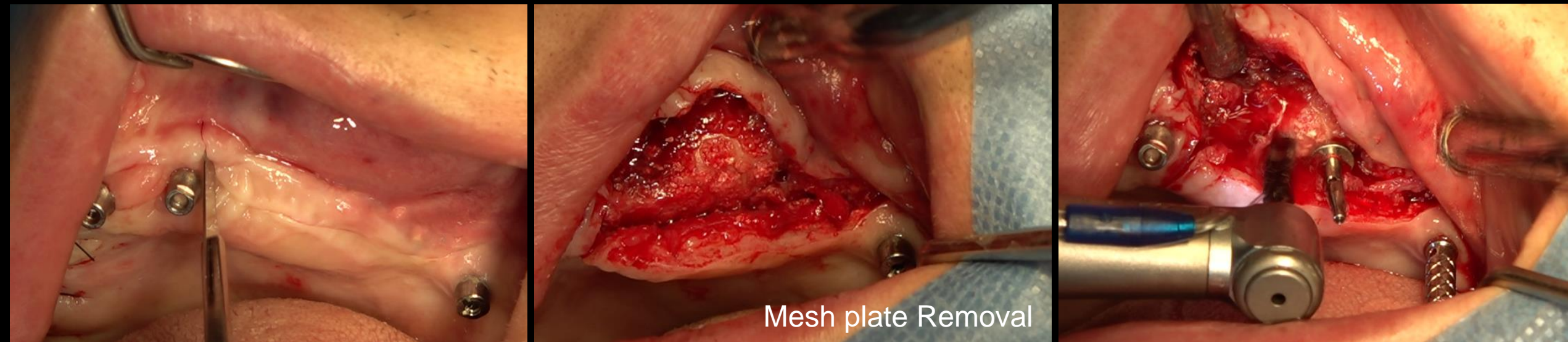


#10 Surgery

Aired on June 2nd

3rd Re-view

Overcoming severely defective ridge with Staged process concept

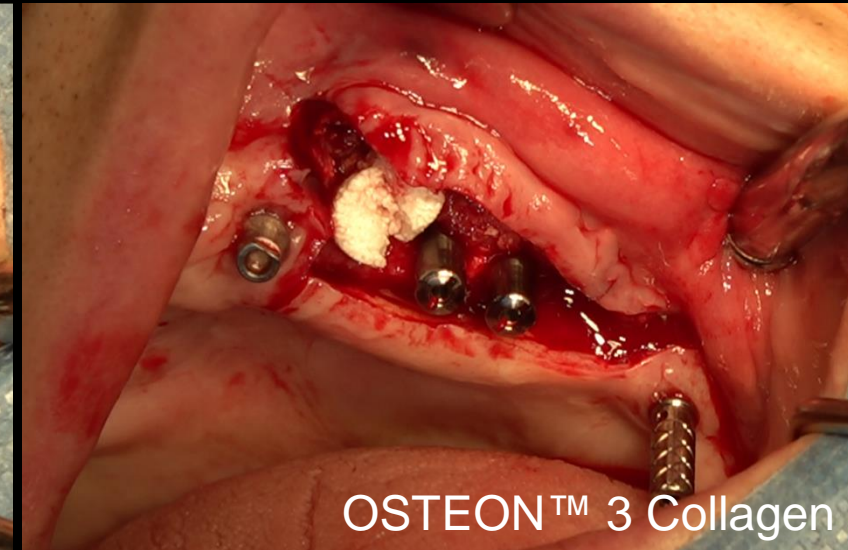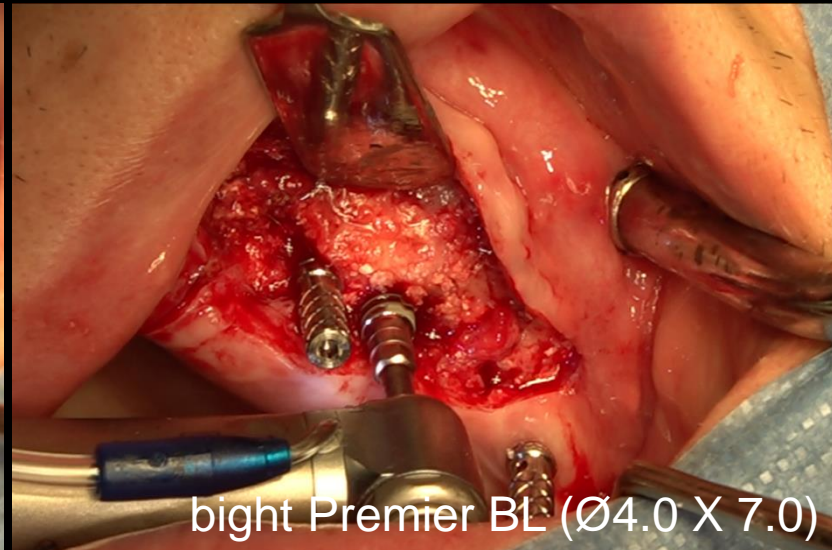
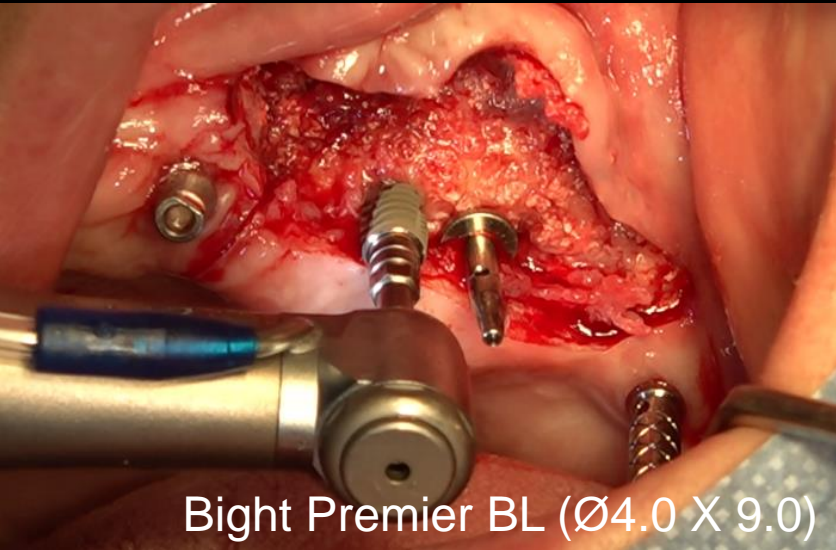


#20 Surgery

Aired on June 2nd

3rd Re-view

Overcoming severely defective ridge with Staged process concept

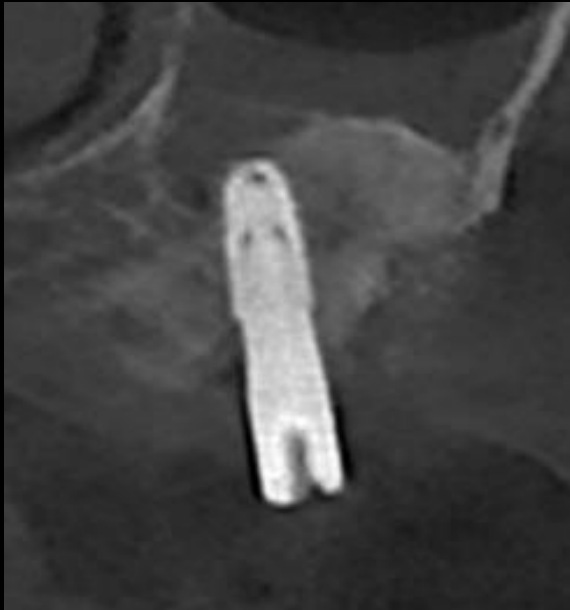

#20 Surgery

Aired on June 2nd

3rd Re-view

Overcoming severely defective ridge with Staged process concept



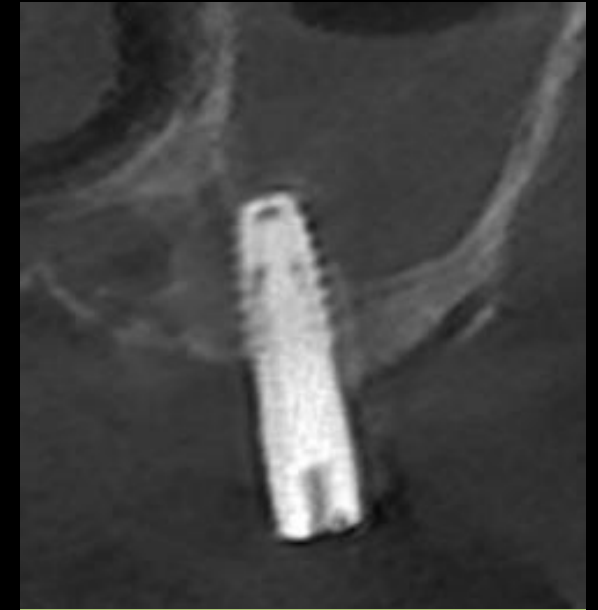
#15



#13



#24



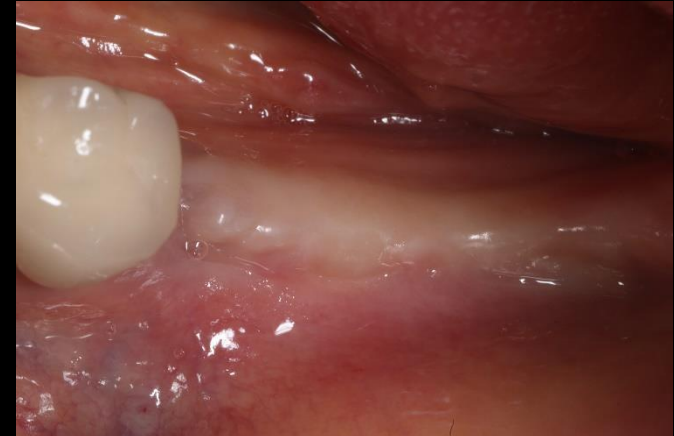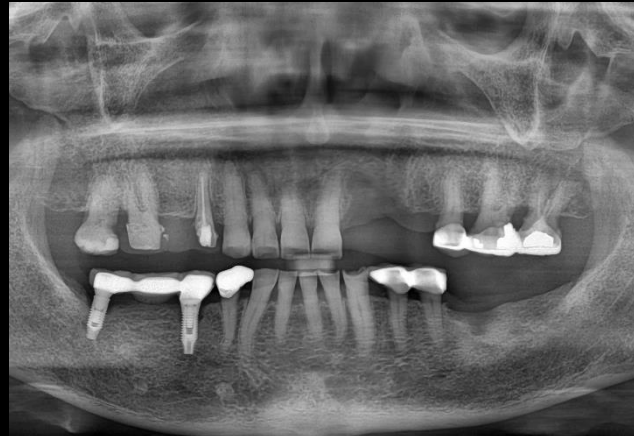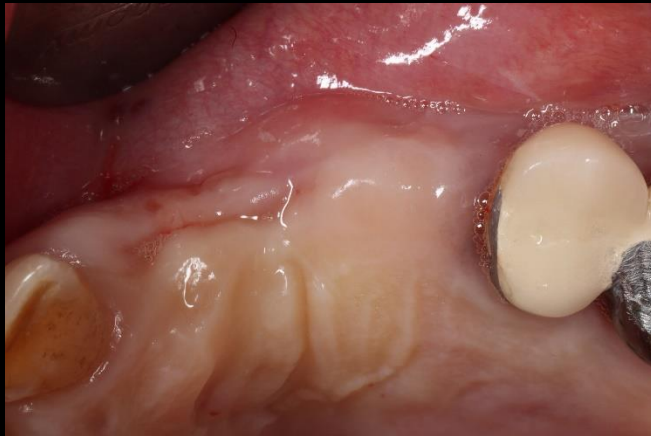
#25

Post-op CT

LIVE & Follow up 2nd Ratings

Aired on January 6th

Narrow Implantation & Ridge augmentation on defect area

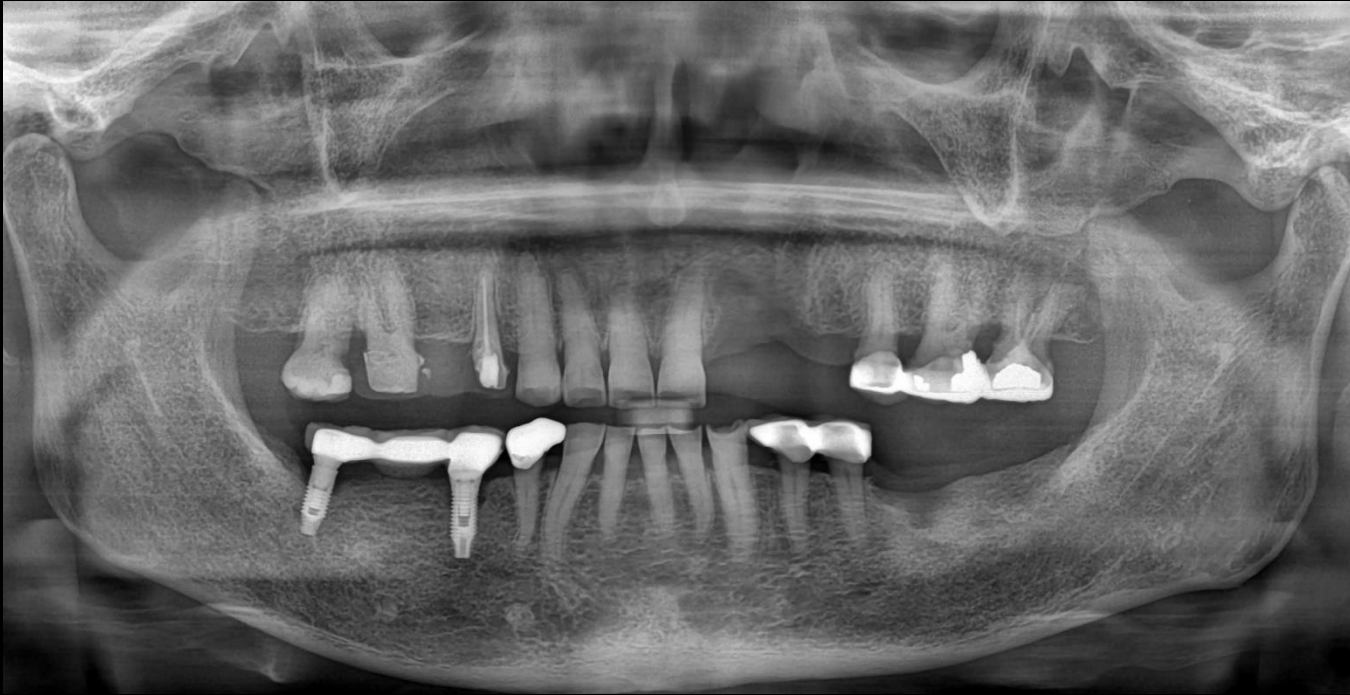

Dr. SM Chung

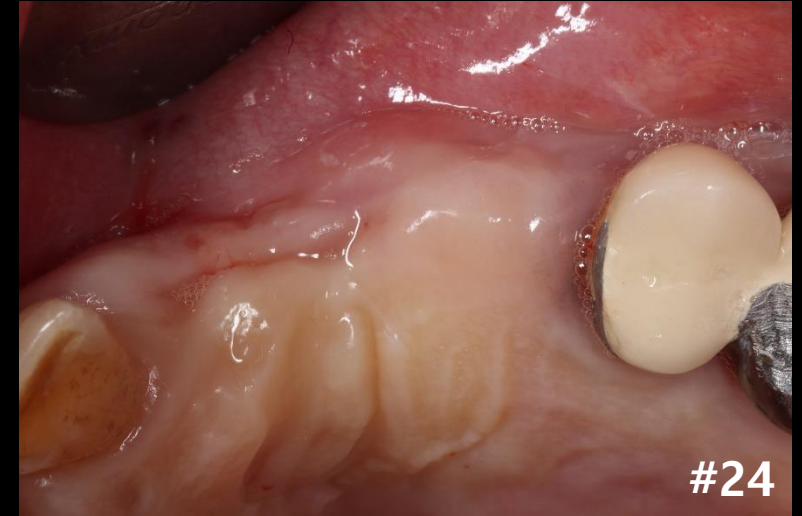
Aired on January 6th

2nd Re-view

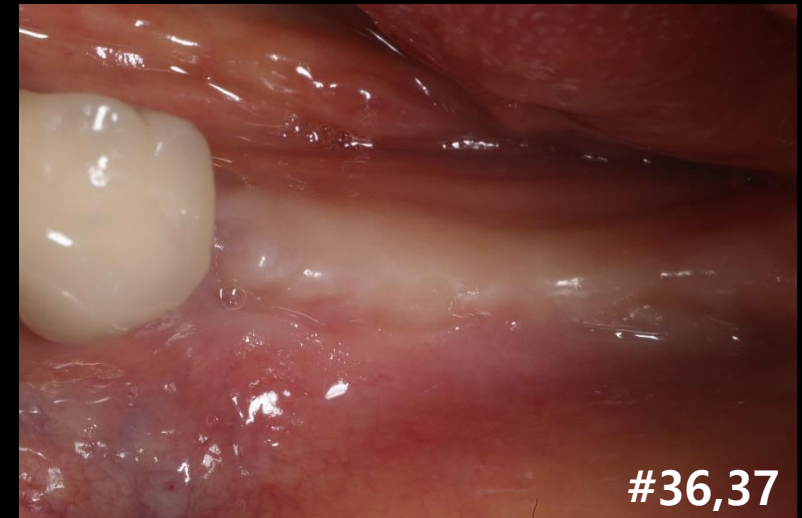
Narrow Implantation & Ridge augmentation on defect area



Pre-op



#24

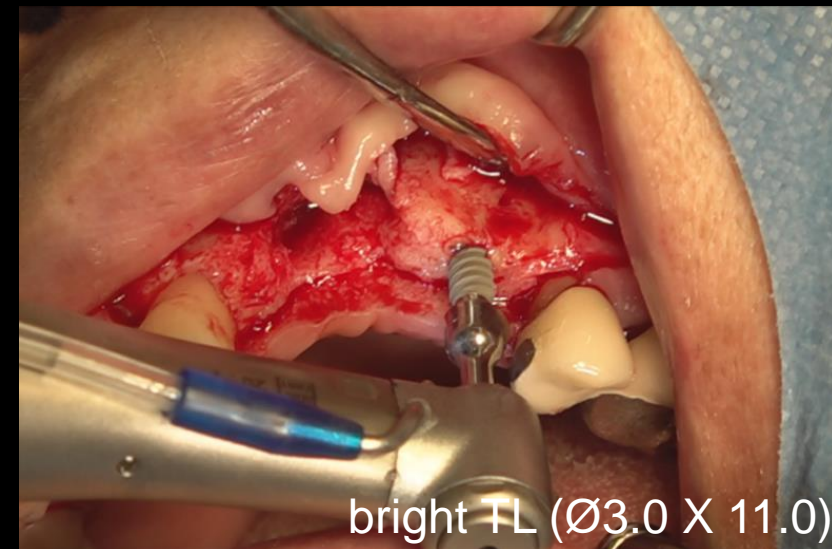
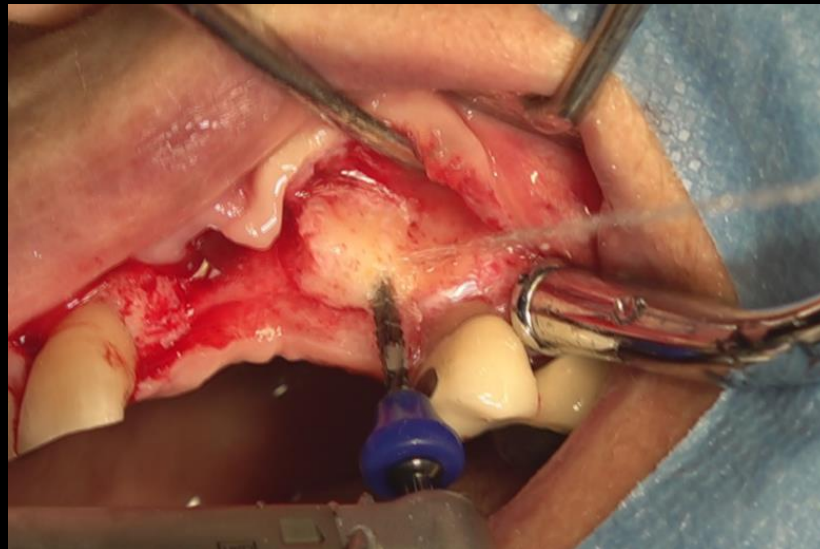
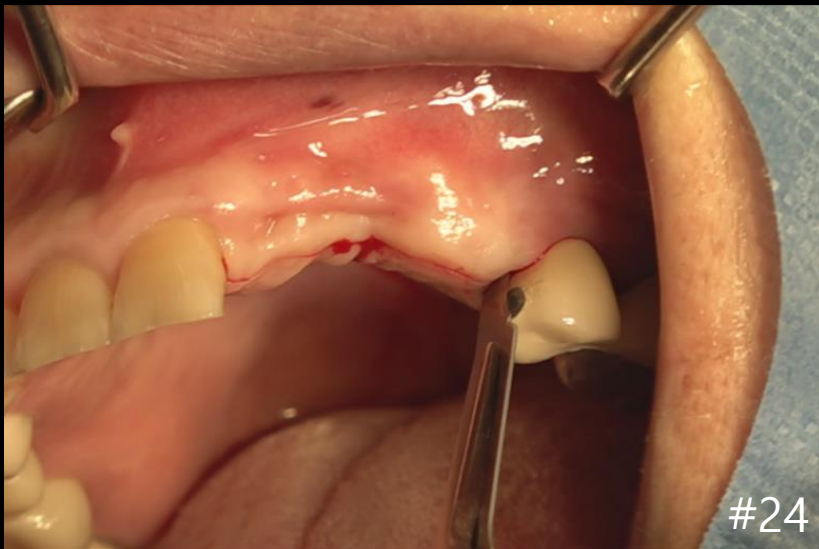


#36,37

Aired on January 6th

2nd Re-view

Narrow Implantation & Ridge augmentation on defect area

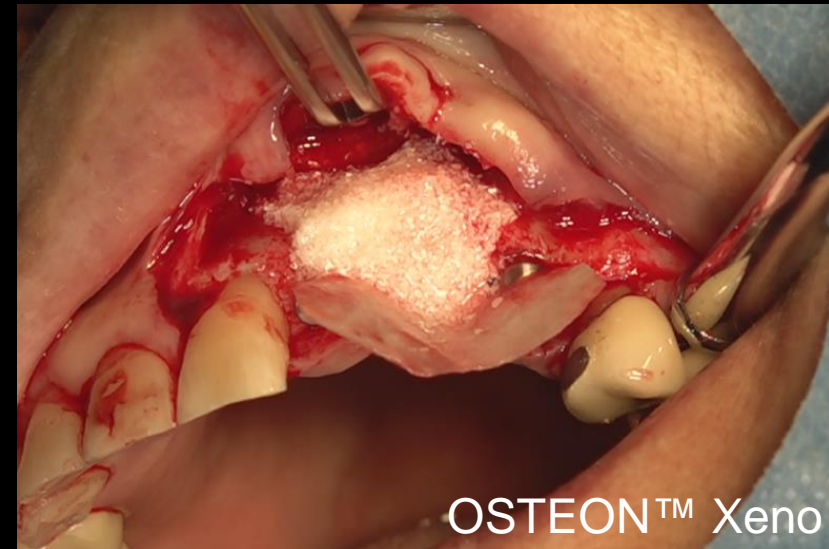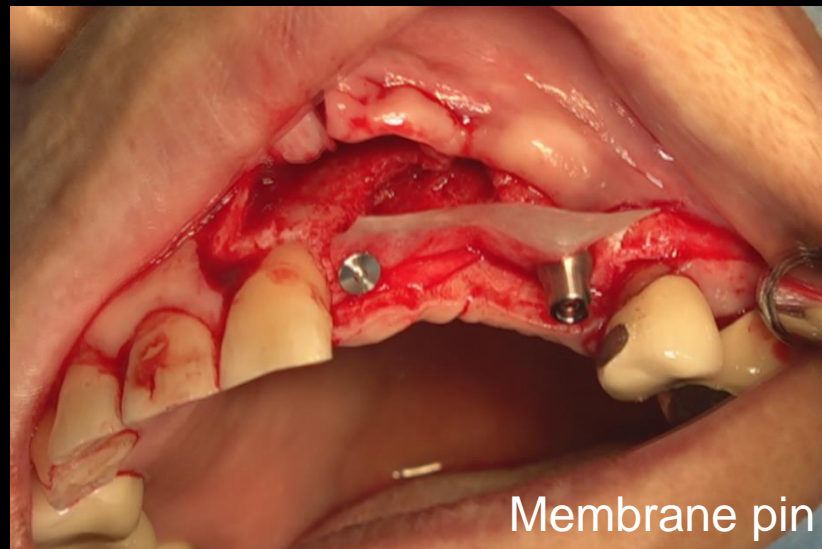
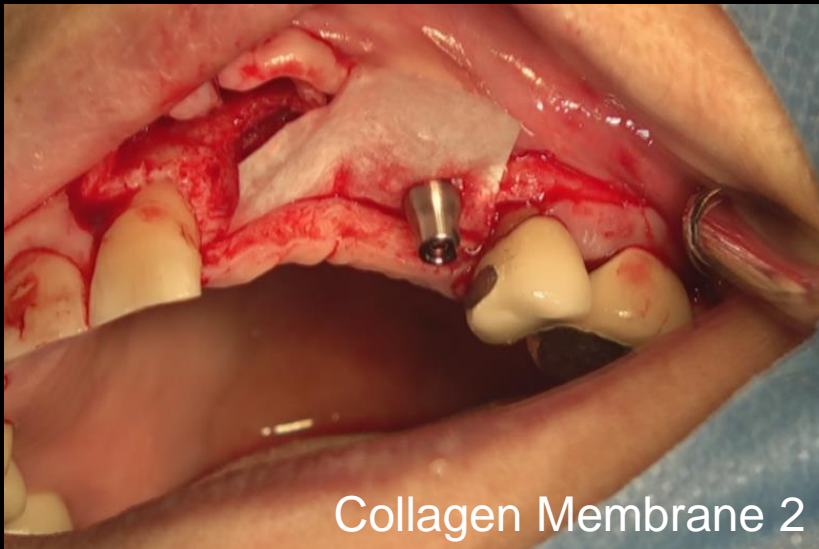


Surgery

Aired on January 6th

2nd Re-view

Narrow Implantation & Ridge augmentation on defect area

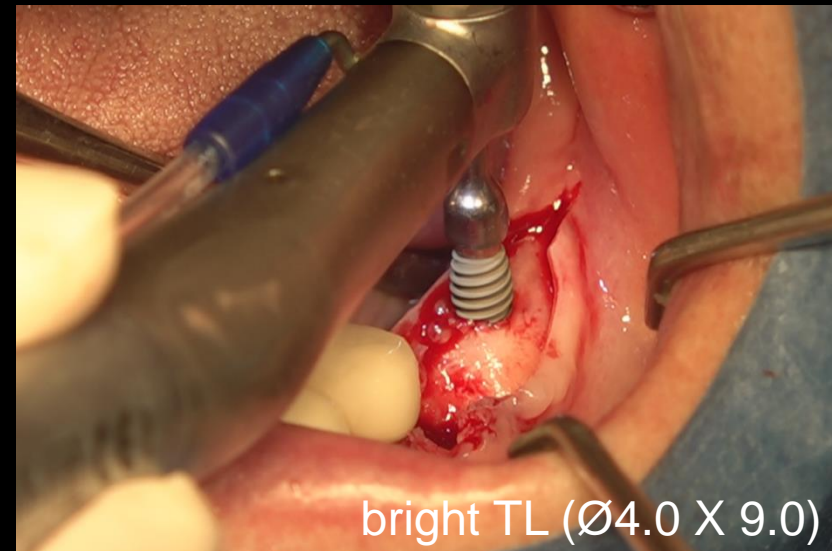
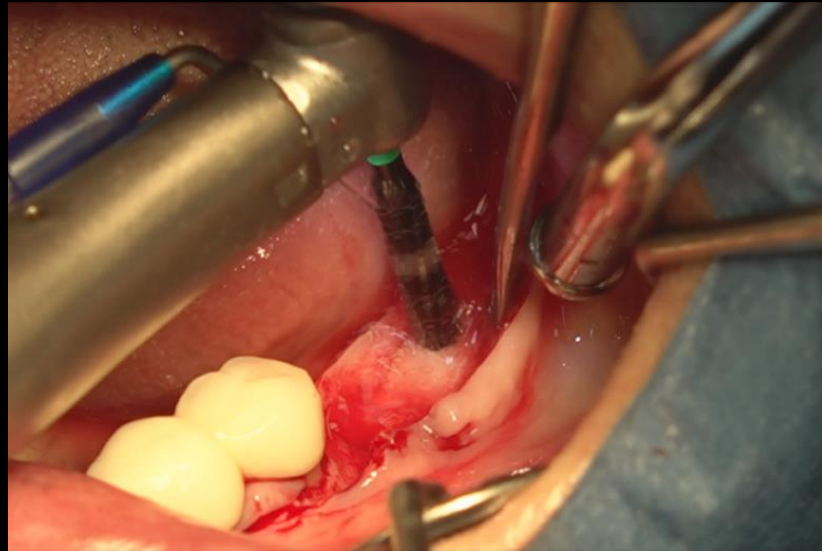
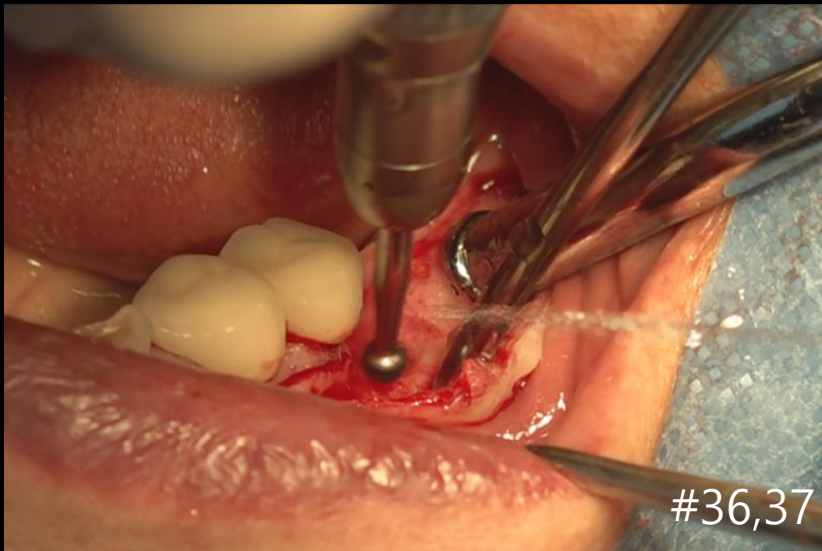


Surgery

Aired on January 6th

2nd Re-view

Narrow Implantation & Ridge augmentation on defect area

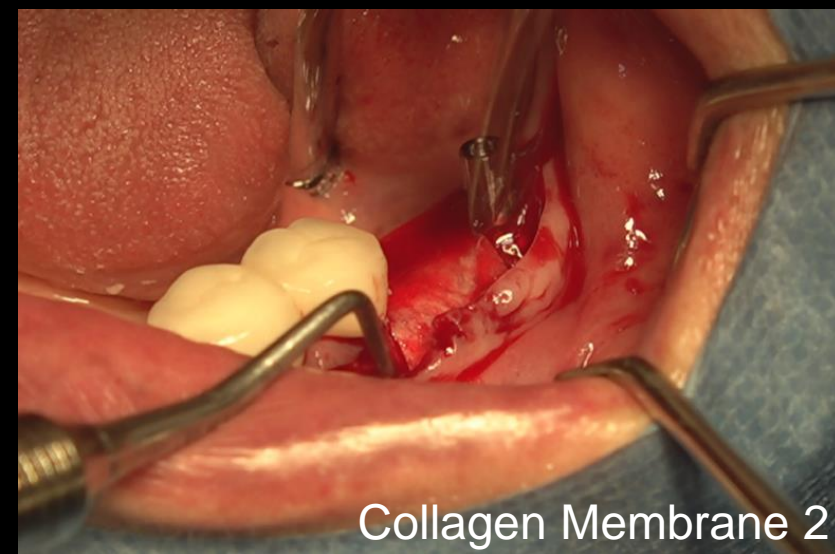
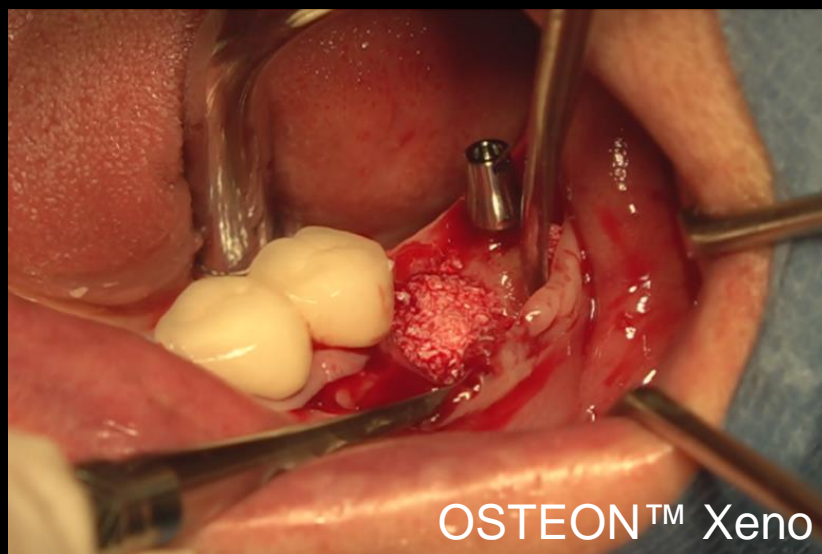
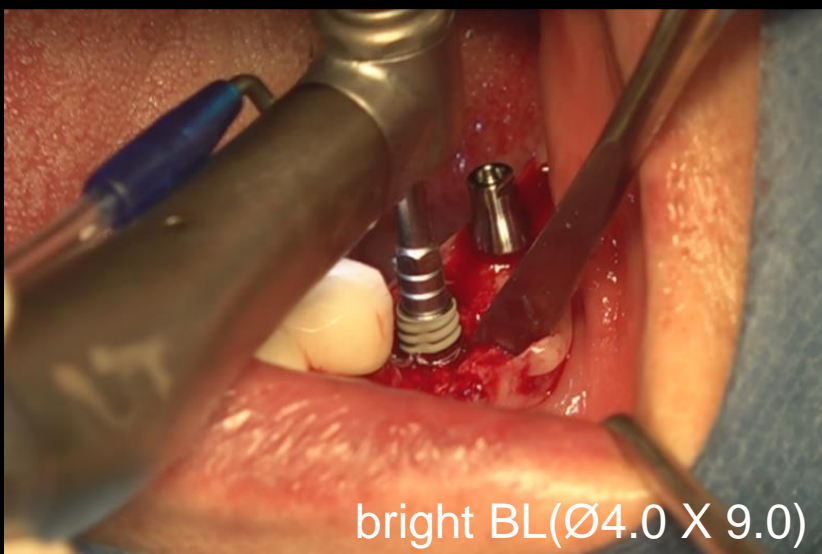


Surgery

Aired on January 6th

2nd Re-view

Narrow Implantation & Ridge augmentation on defect area

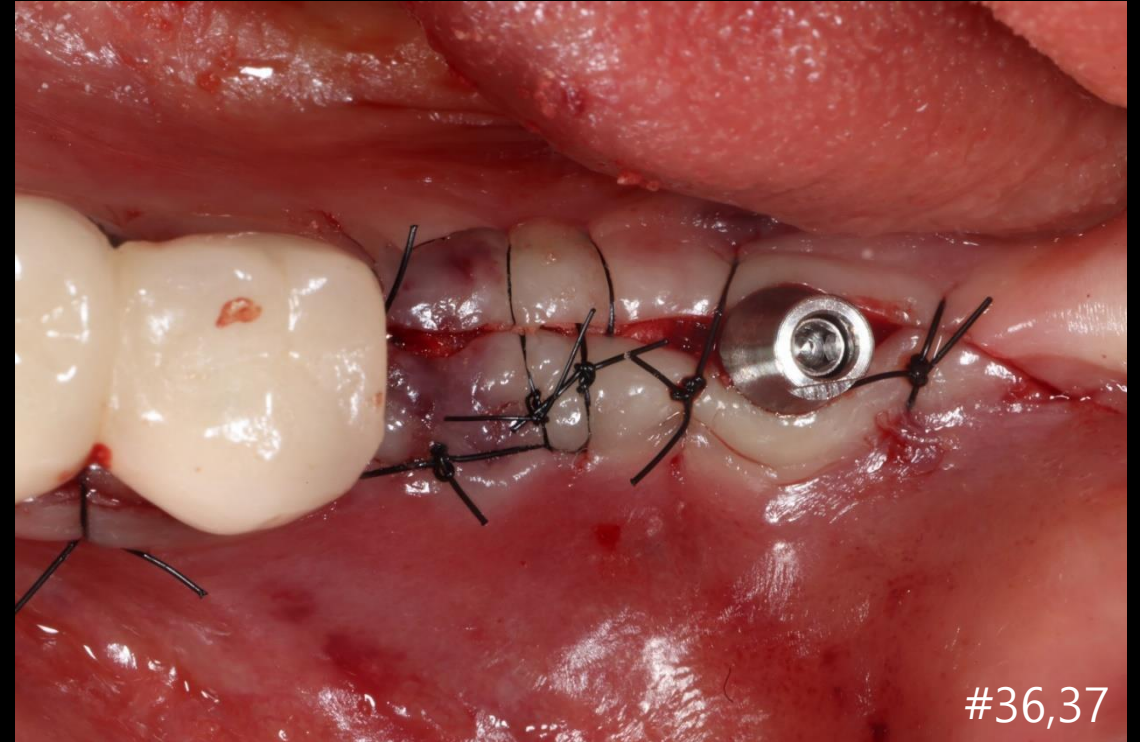
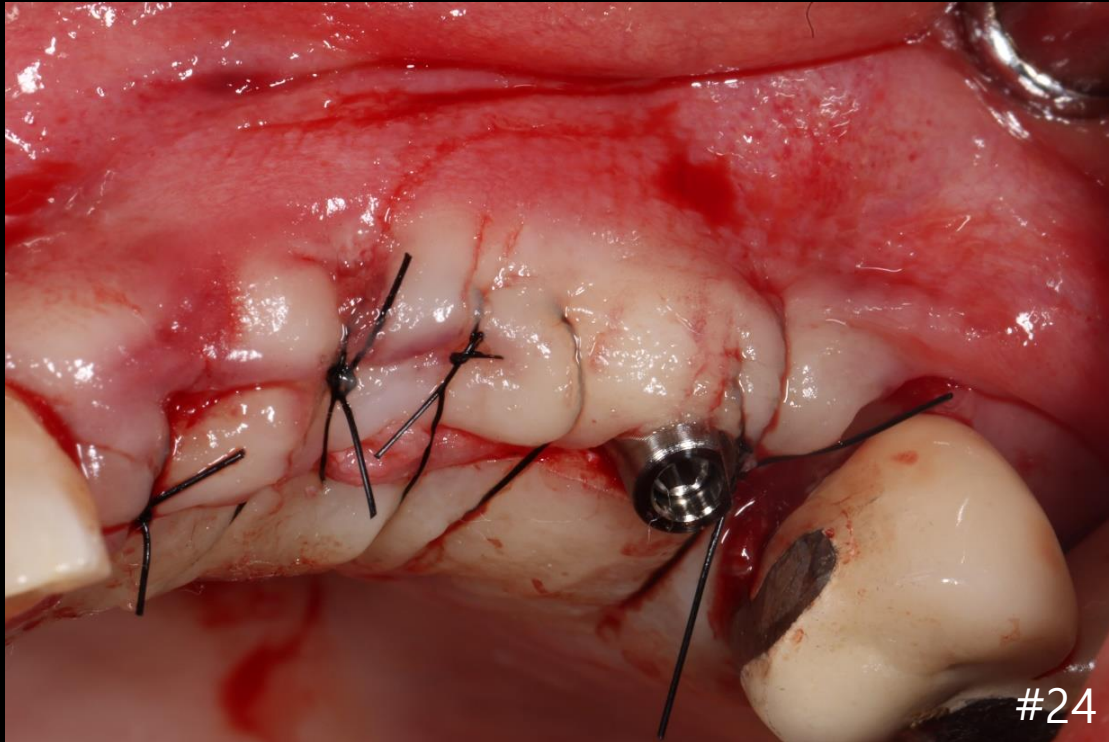


Surgery

Aired on January 6th

2nd Re-view

Narrow Implantation & Ridge augmentation on defect area

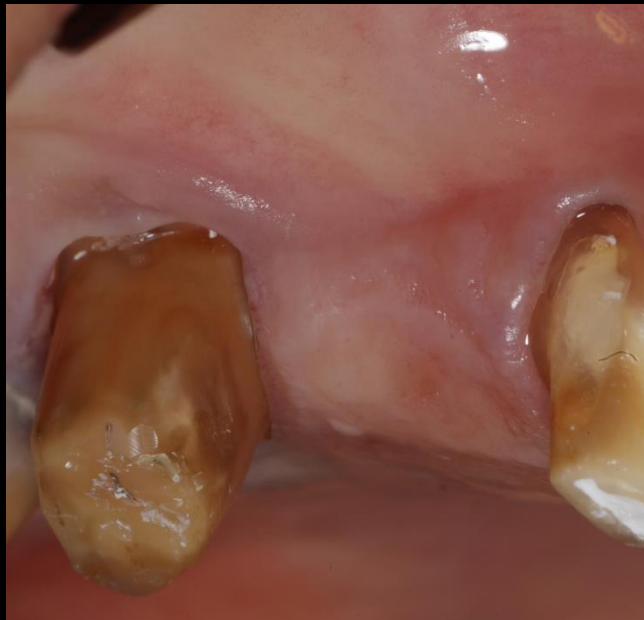


Post-op

 **LIVE** & Follow up 1st Ratings

Aired on August 4th

Simple & Clear Lateral approach with DASK Simple

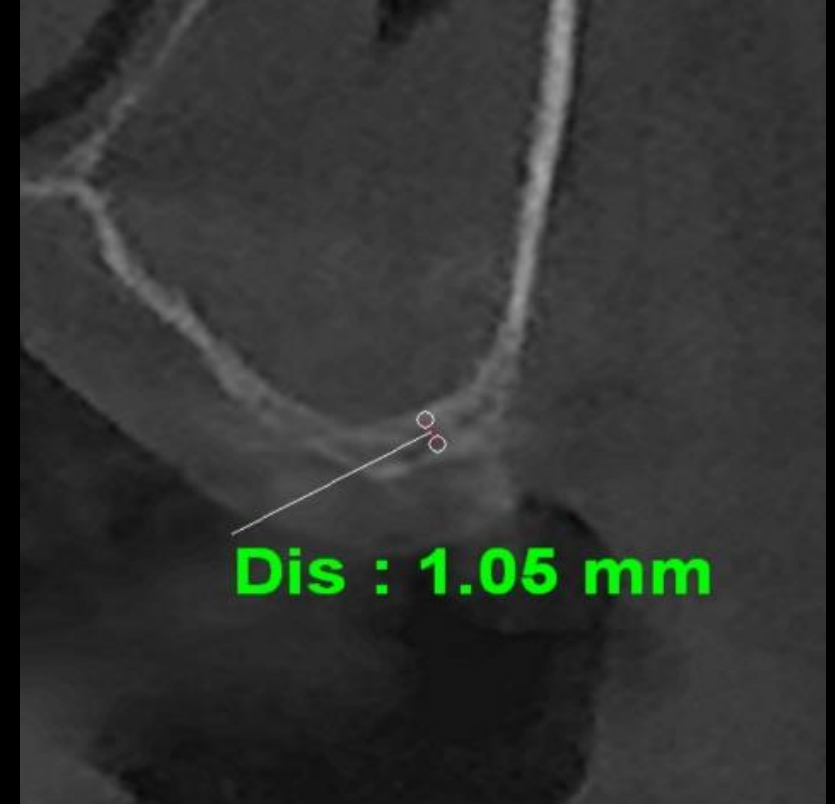
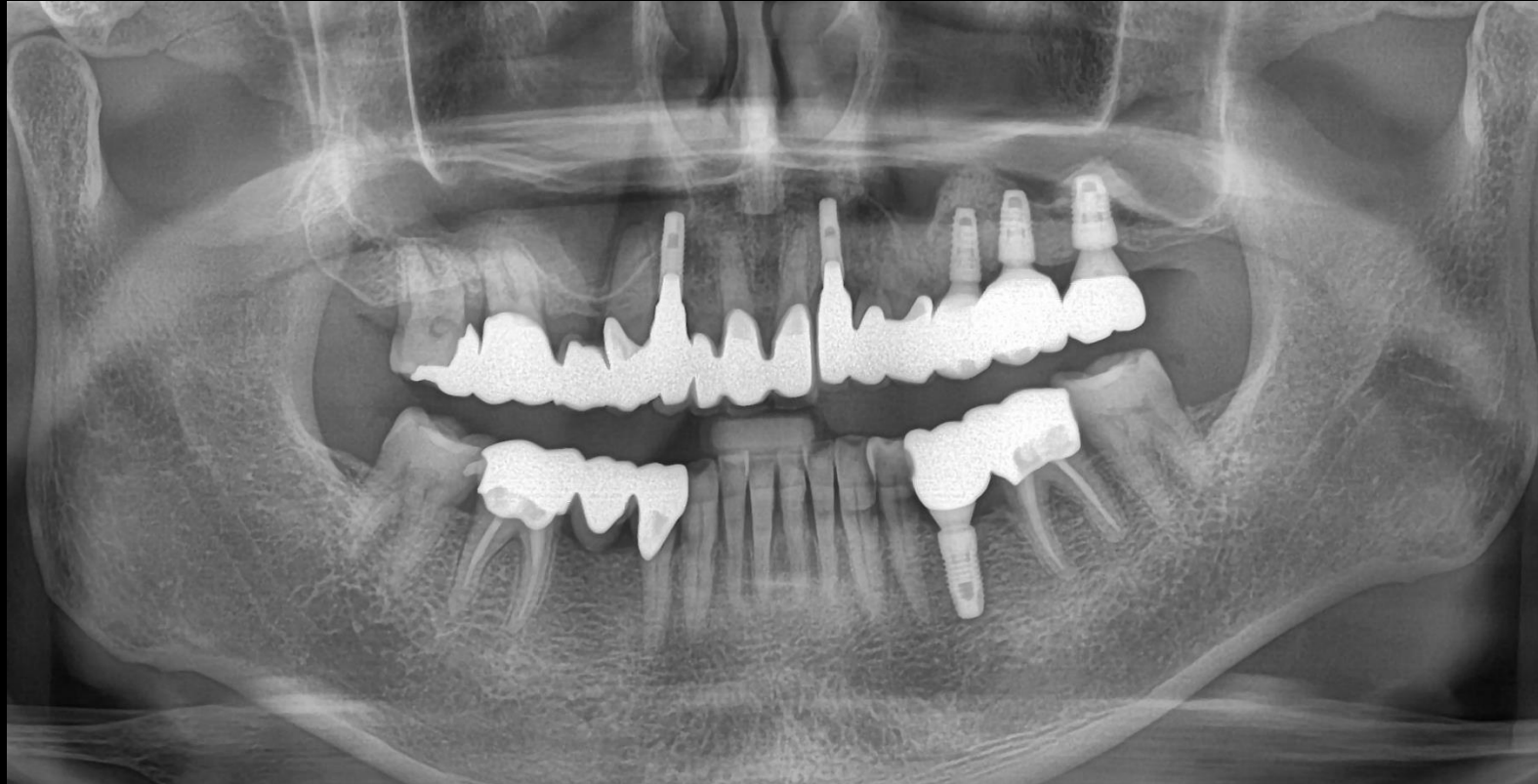
Dr. SM Chung

Aired on August 4th

1st Re-view

Simple & Clear Lateral approach with DASK Simple



Pre-op

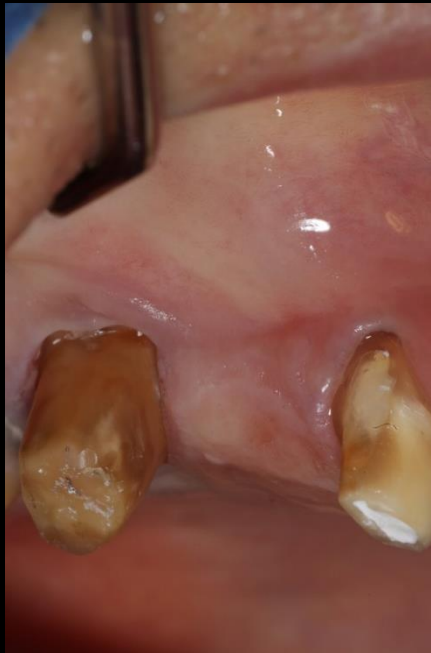
Aired on August 4th

1st Re-view

& Clear Lateral approach with DASK Simple

Past Dental History #14, 16 endodontic treatment & caries treatment and Prep for Temporary bridge crown

Surgery Plan



- Implantation on #15 using **bright bone Level**
- Lateral approach with DASK Simple & **OSTEON™ 3 Collagen**

Aired on August 4th

1st Re-view

Simple & Clear Lateral approach with DASK Simple

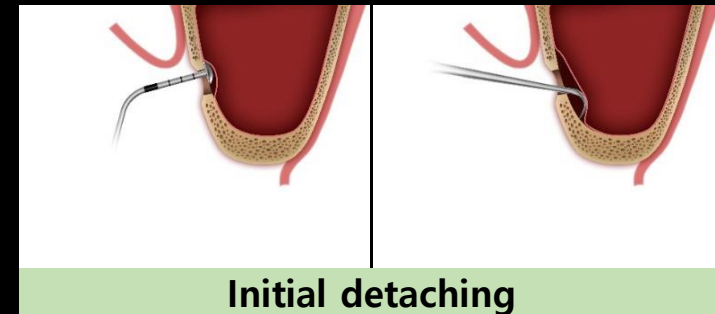
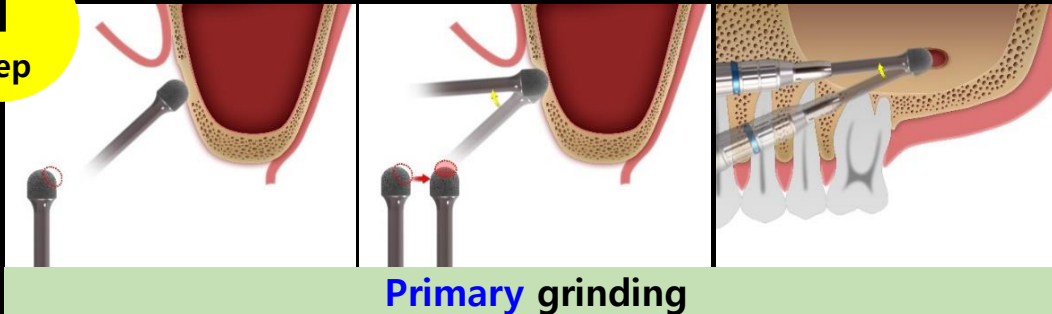
Minimalism in Sinus

Surgery point

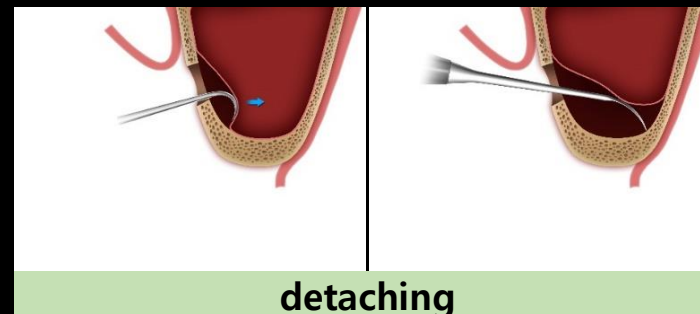
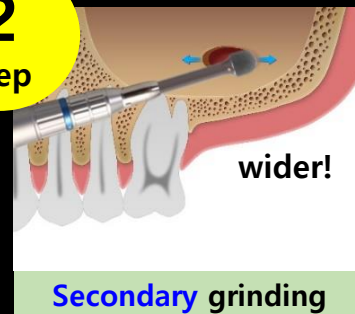
√ 2 Step grinding-out technique

Minimization of perforation

1
step



2
step

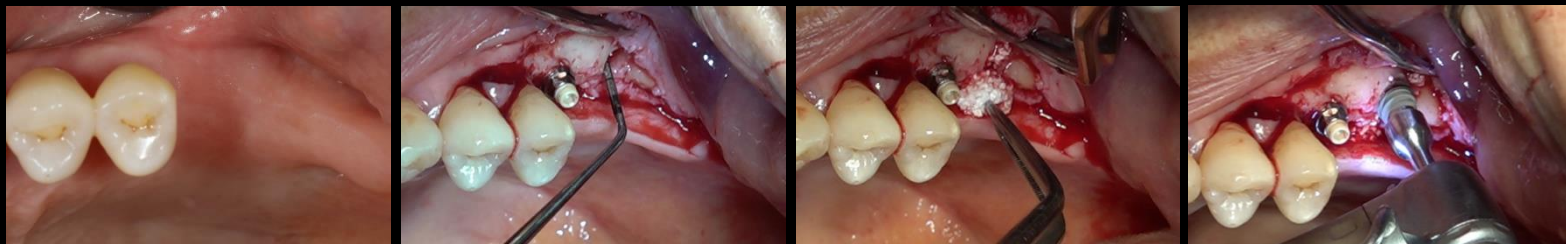

OSTEONTM 3 Collagen

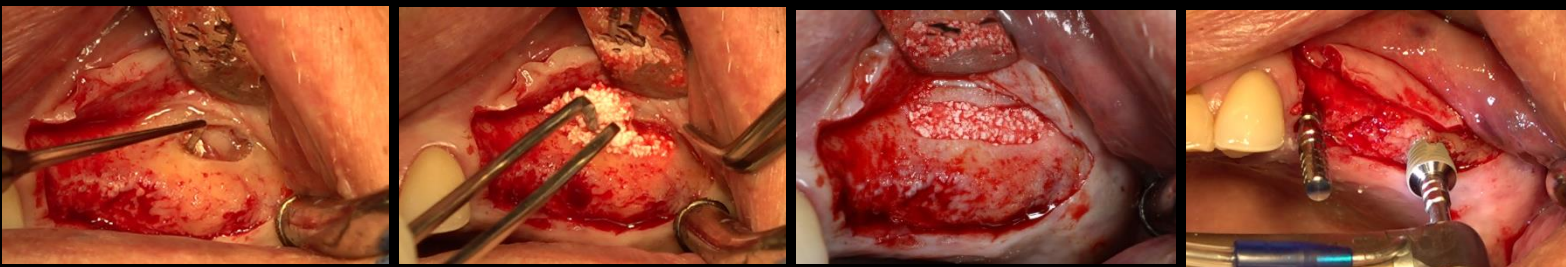
- Moldable to various defect shapes during wetting
- Easy handling to reduce chair time
- Collagen is absorbed within a few weeks after grafting



Case 1



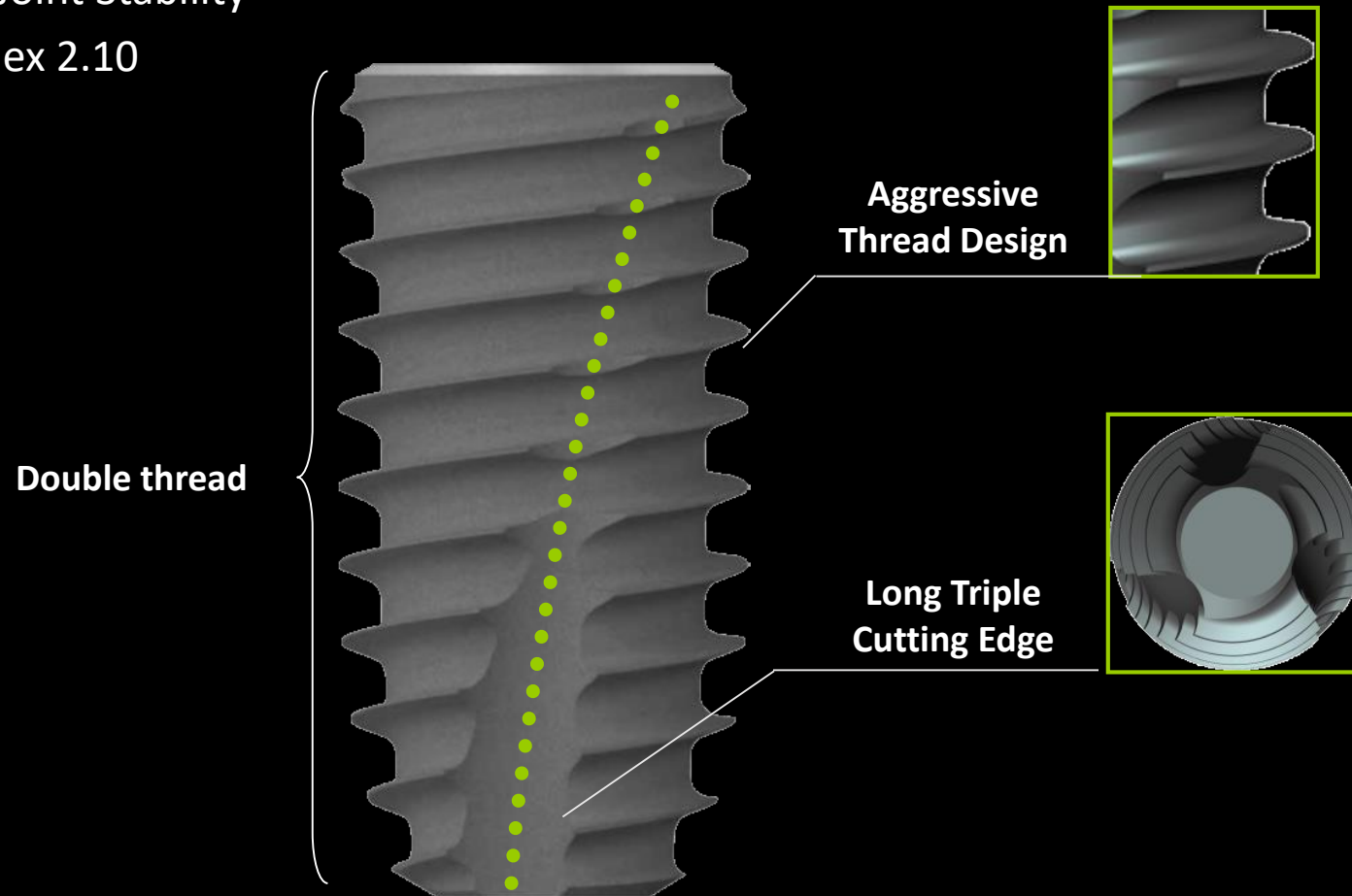
Case 2



bright Bone Level

10° , 3.70 mm Deep Connection

- Excellent Joint Stability
- Internal Hex 2.10



1st Surgery 영상 송출