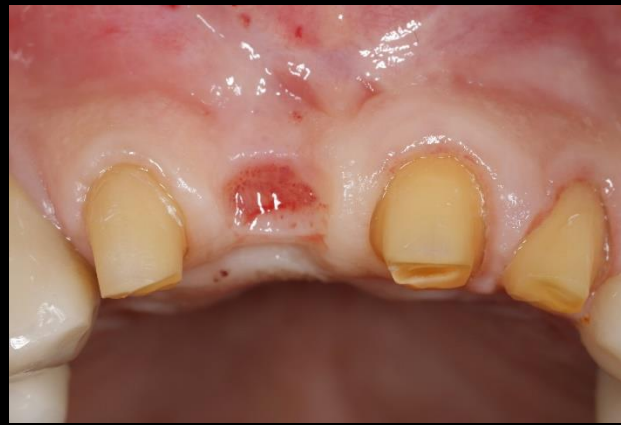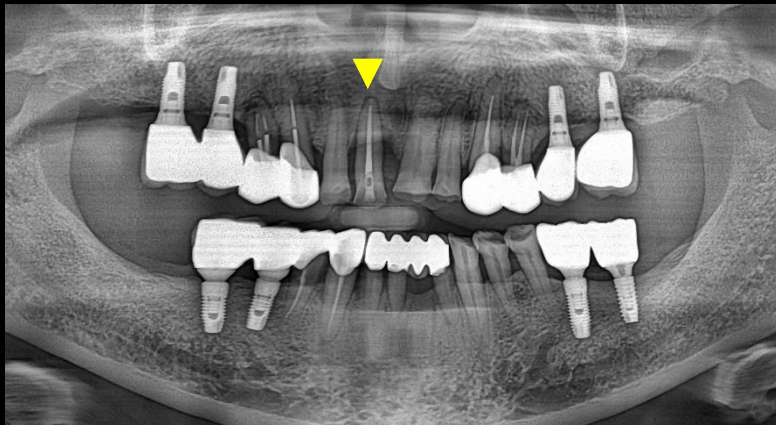


 **LIVE** & Follow up

Narrow implant placement

On upper anterior with simpler bone grafting



Dr. SM Chung

2024.04.05. (Fri)

Patient Information

Age : 74

Sex : Male

Chief Complaint

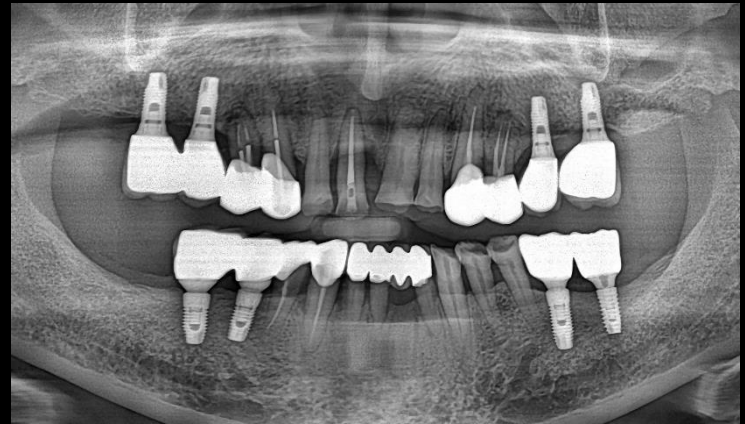
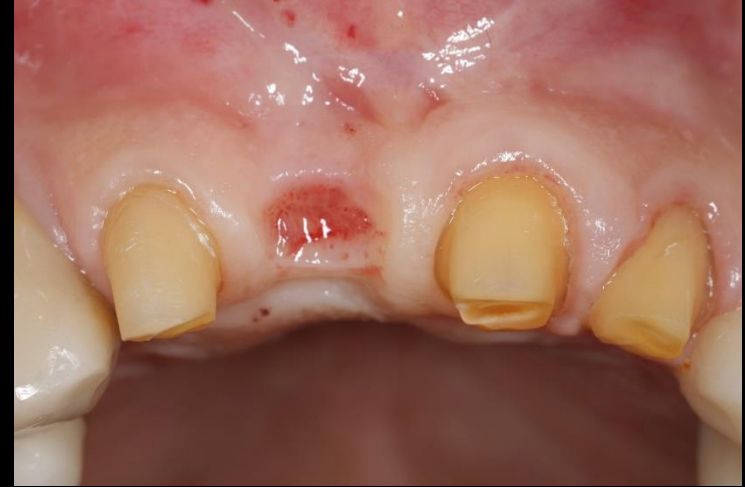: I'd like to get on implant treatment
on the area where I extracted it.

Past Dental History

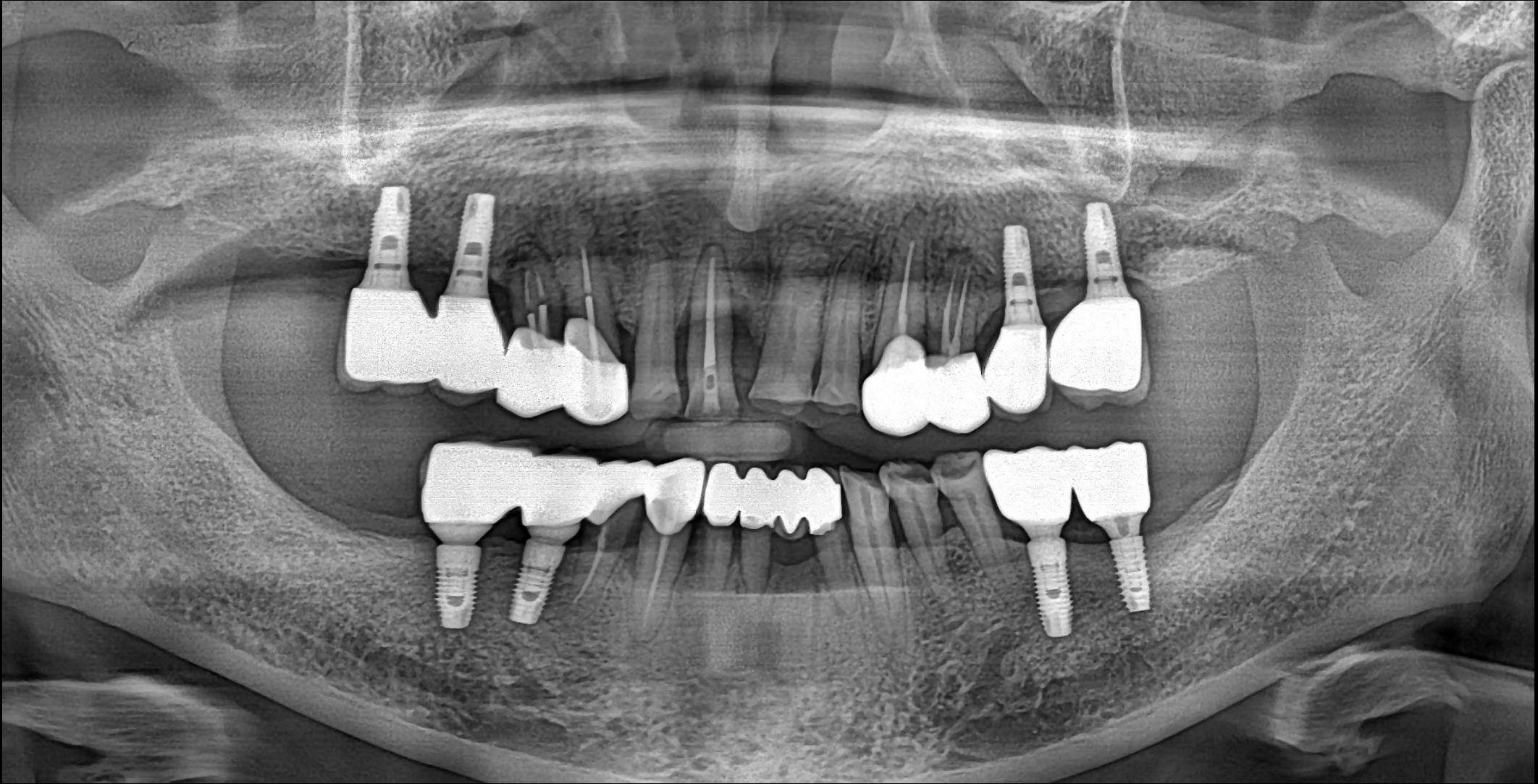
: #11 extraction before 7 months

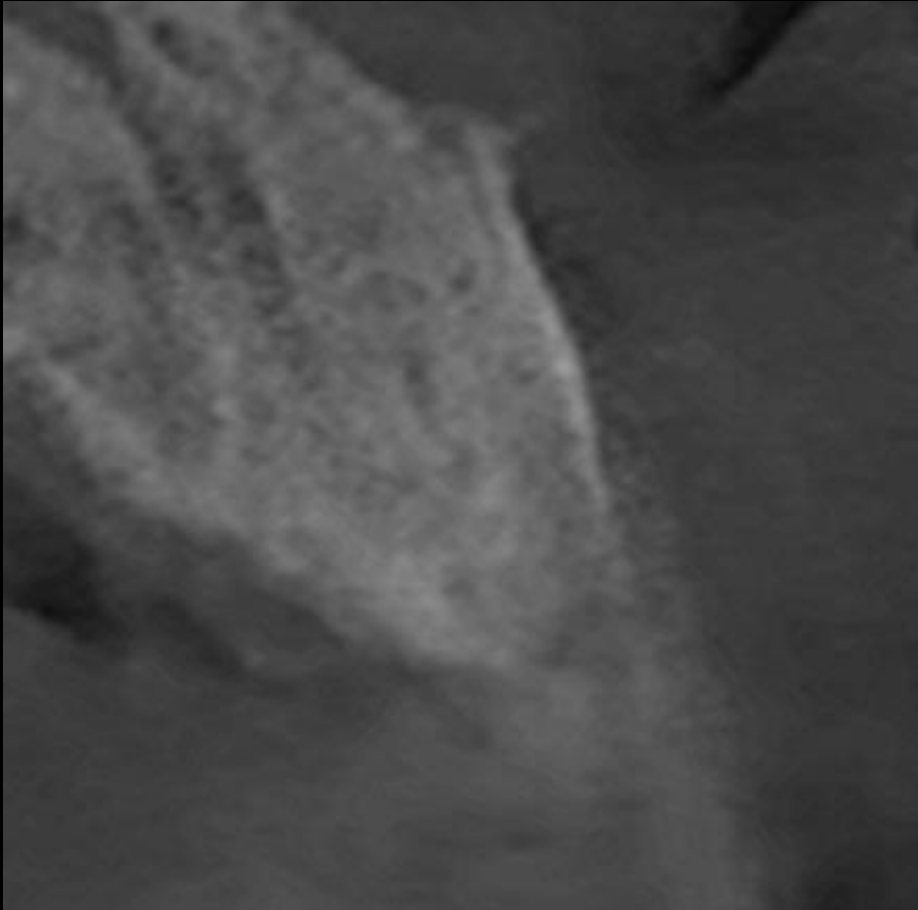
Past Medical History

: None

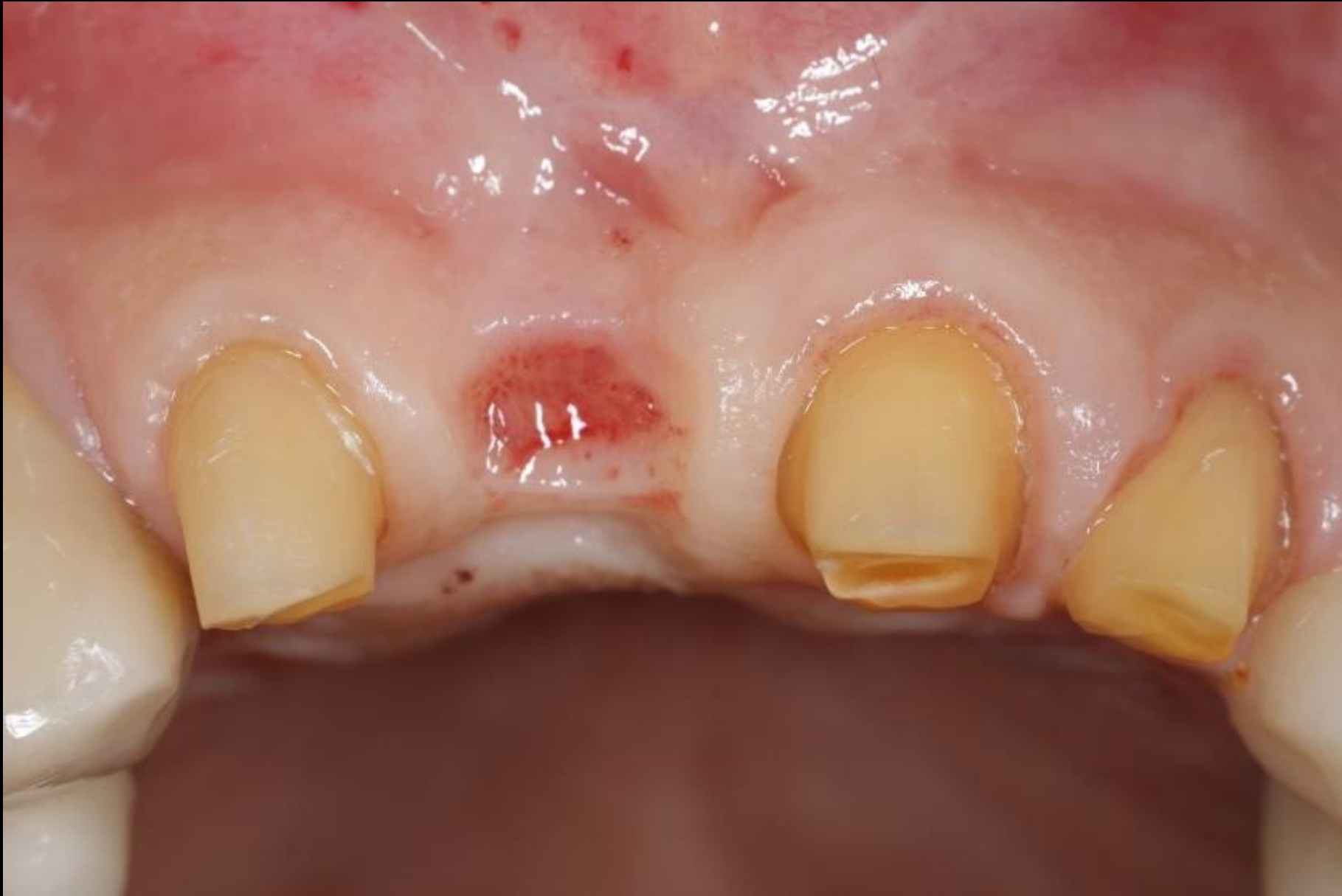

Pre-op



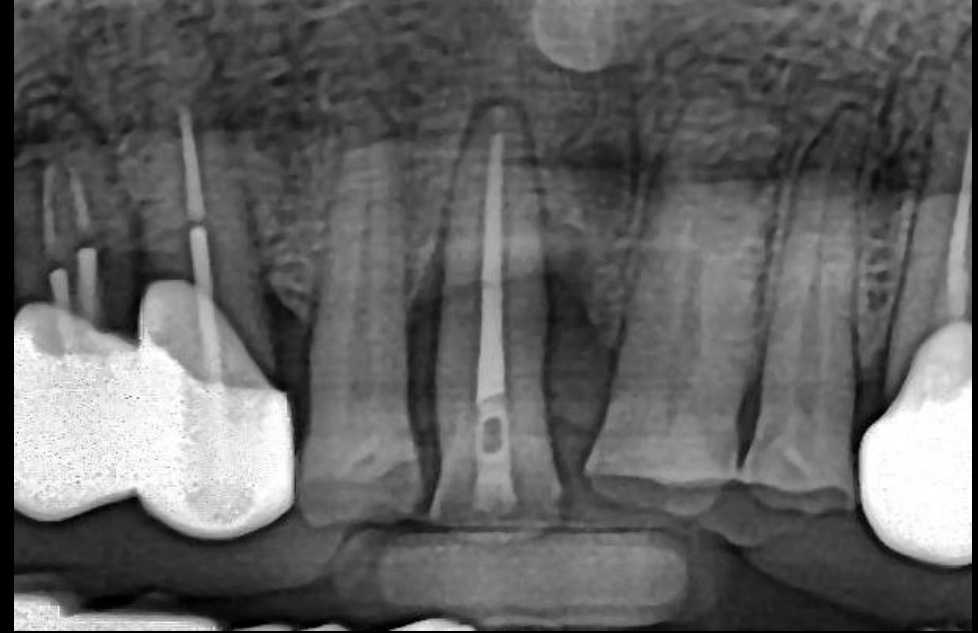
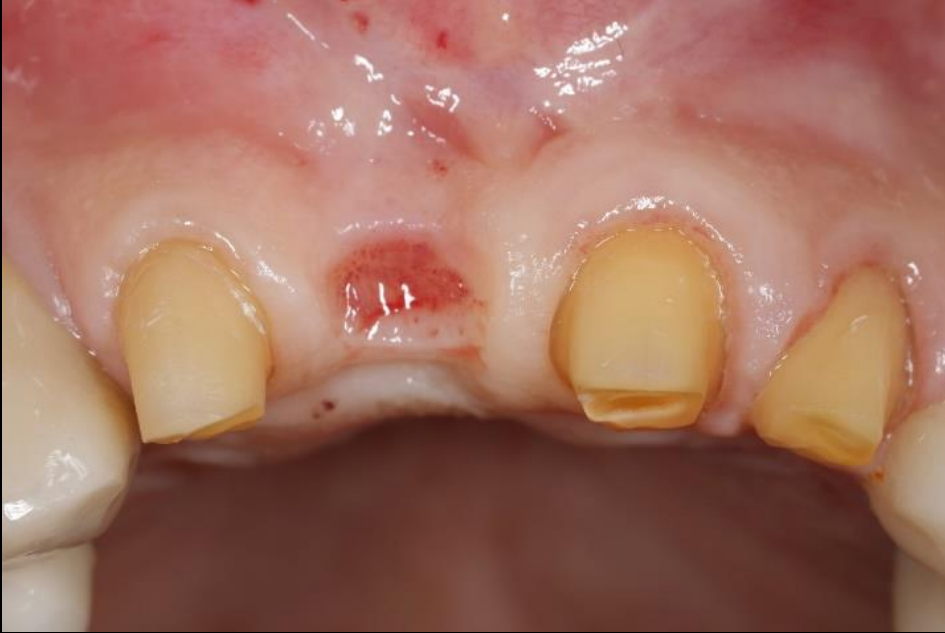
#11



Pre-op

Surgery Plan (#11)



- Narrow Implantation on #11 using **bright Tissue Level**
- Bone Graft using **OSTEON™ Xeno Collagen, Collagen Graft 2**

Minimalism in GBR

Today's Surgery point

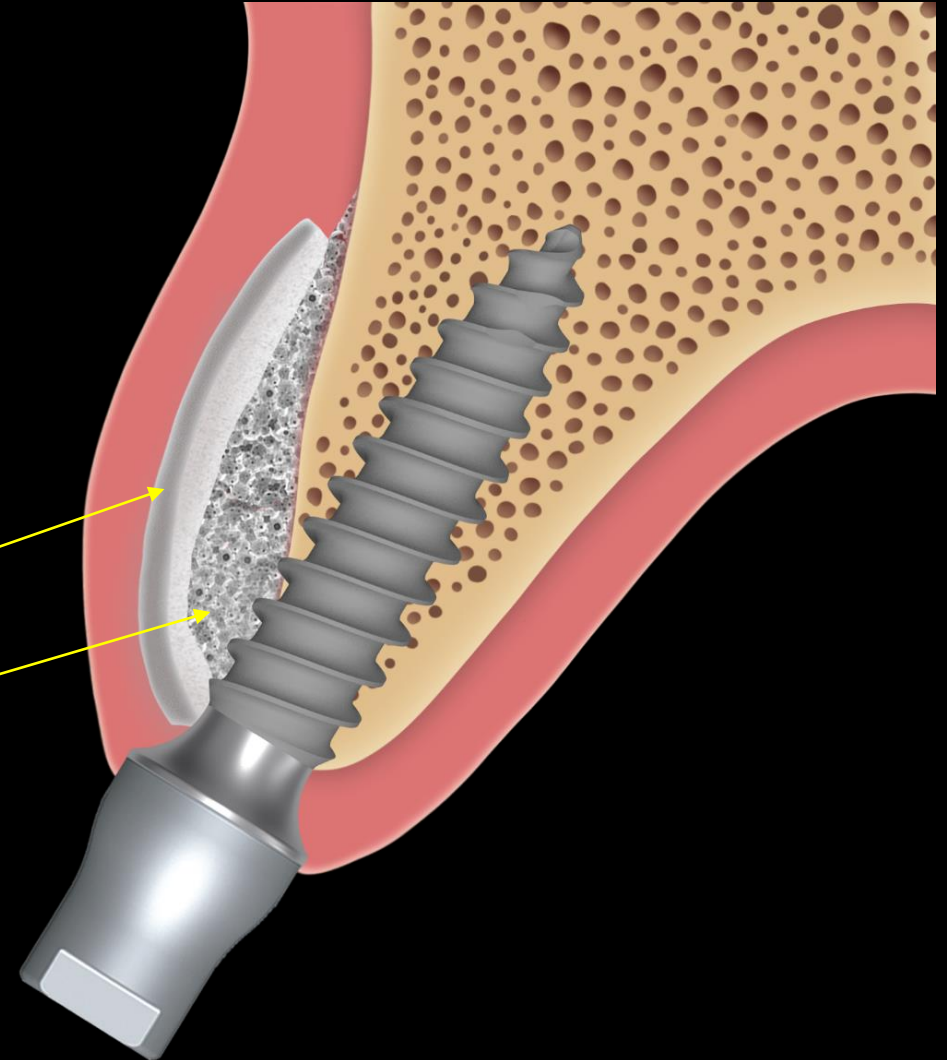
✓ **Easy GBR with bright TL**

1) Narrow implantation

2) OSTEON™ Xeno Collagen

3) Collagen Graft 2


Collagen Graft 2
OSTEON™ Xeno Collagen



bright Tissue Level

For Simplify Surgical Procedure

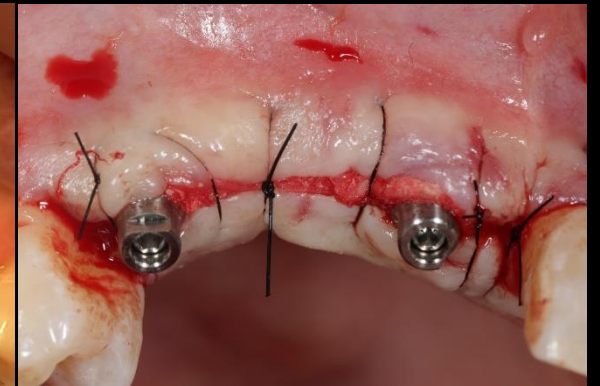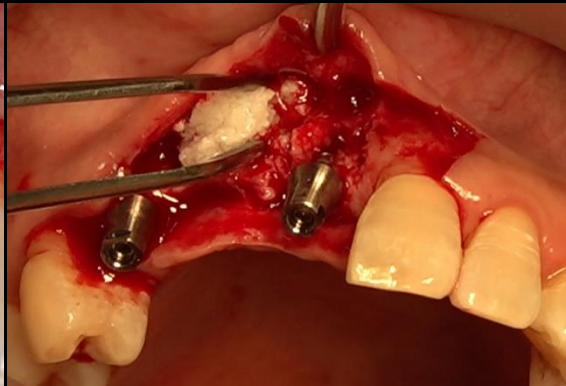
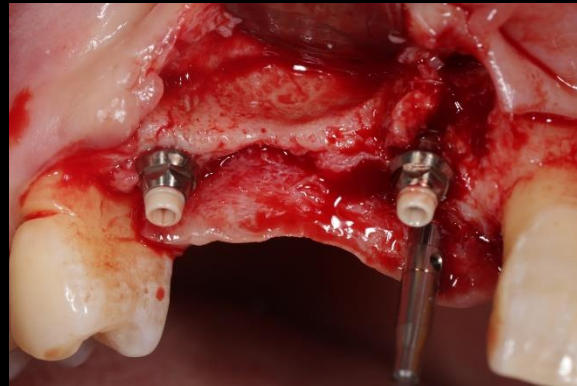
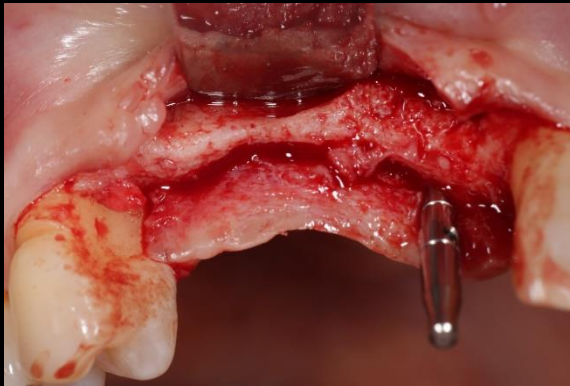
- Thin, Deep & Sharp Thread
- Final Drill Only





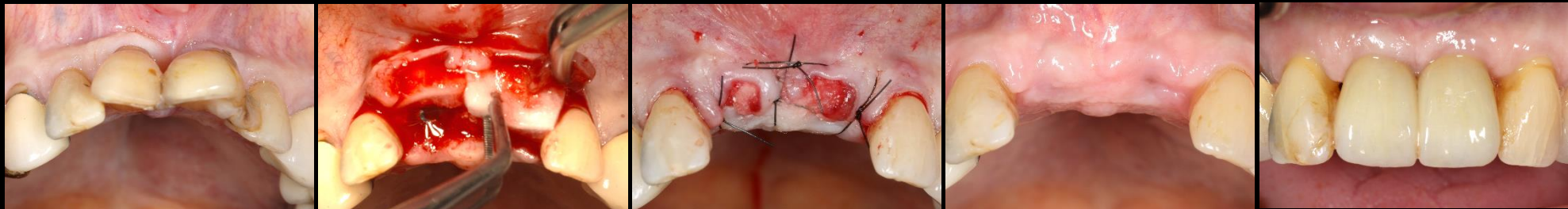OSTEON™ Xeno Collagen

- Ossification ability of Xeno graft
- Easy handling of collagenized bone graft
- Optimal collagen absorption speed



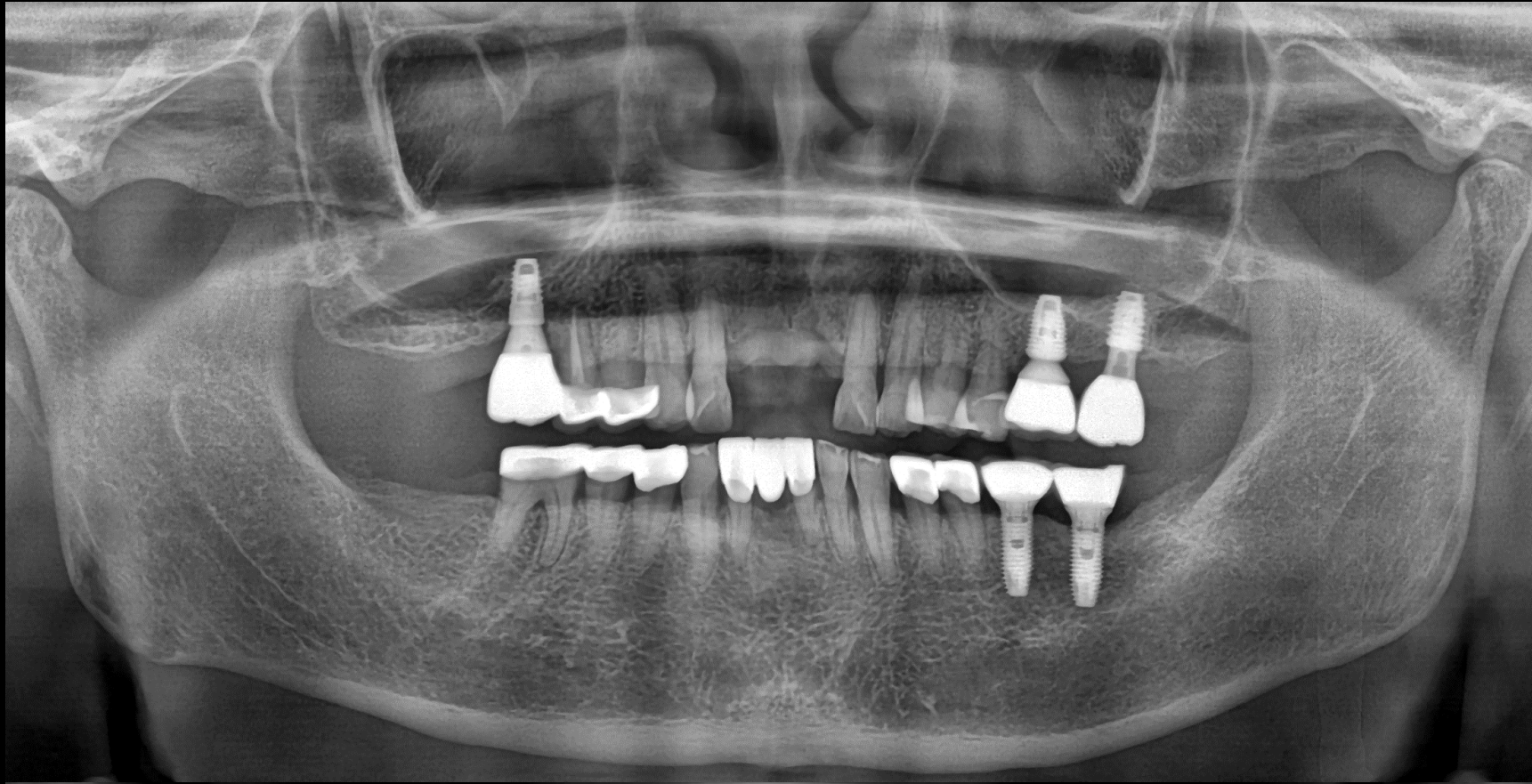
Collagen Graft 2

- Ridge preservation
- Porcine tendon derived type I collagen
- Faster soft tissue healing by epithelization



Similar case 1

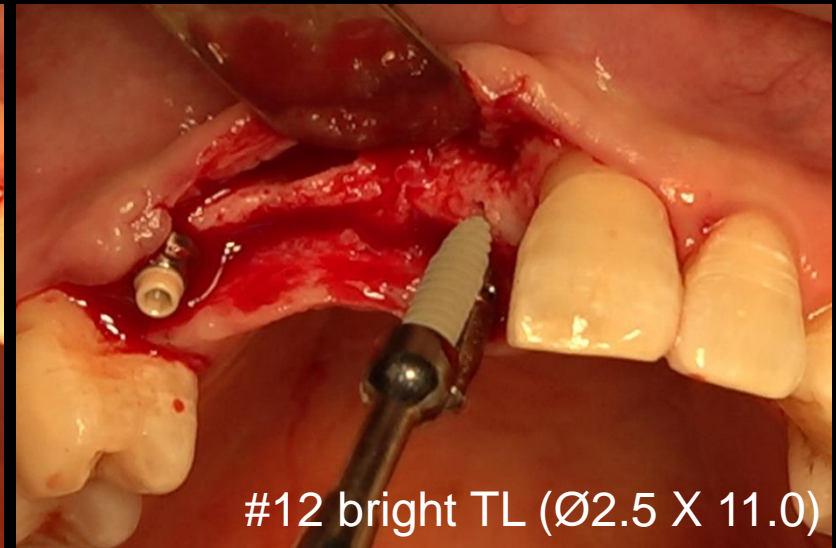
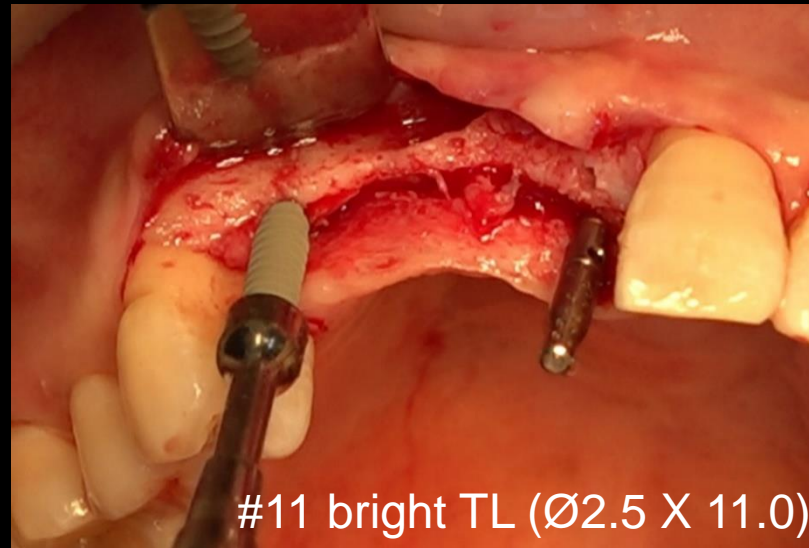
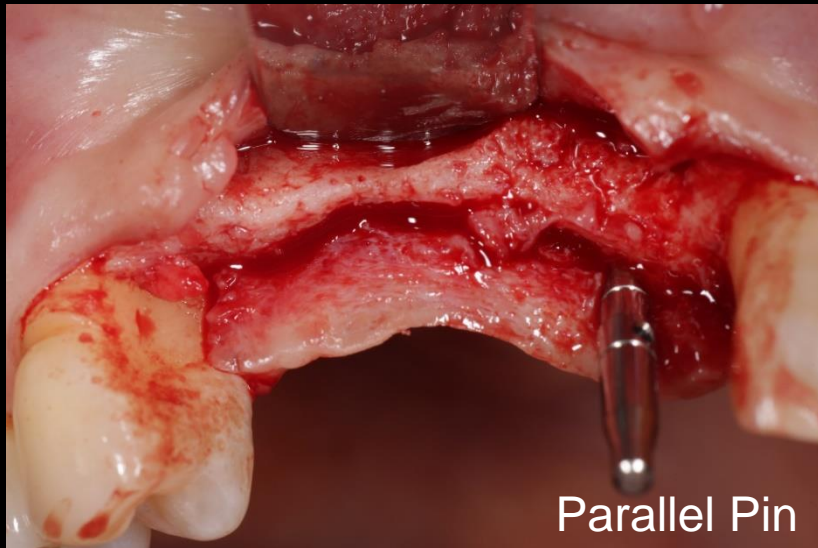
Narrow implantation & Contour Augmentation



Pre-op

Similar case 1

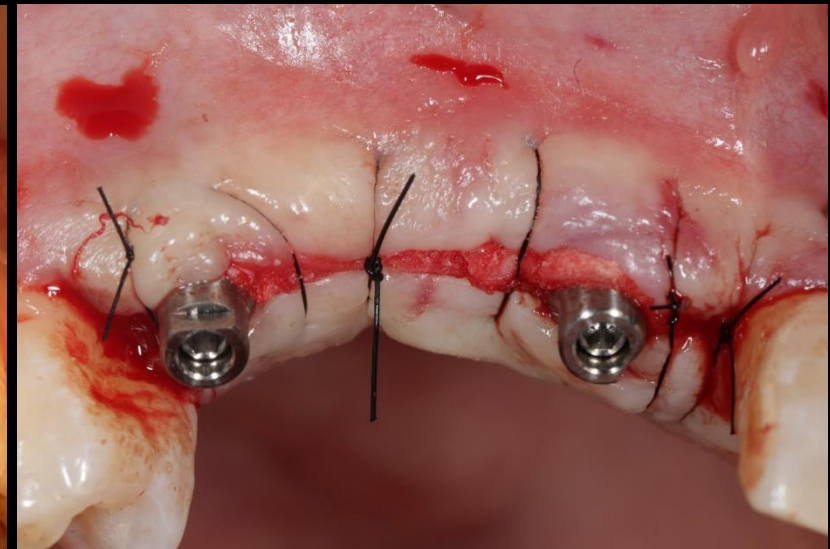
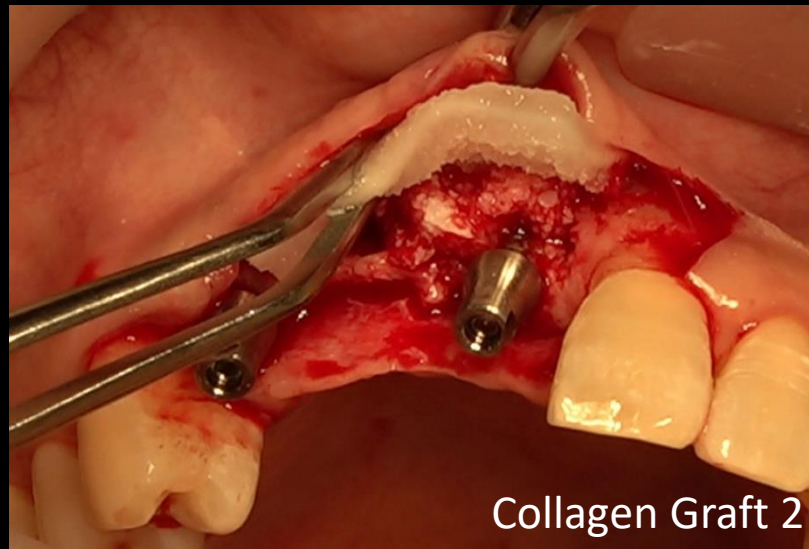
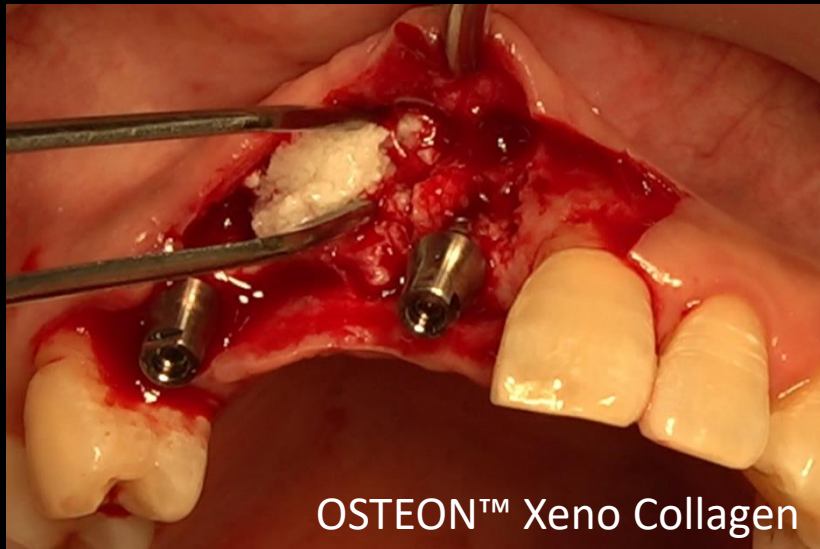Narrow implantation & Contour Augmentation



Surgery

Similar case 1

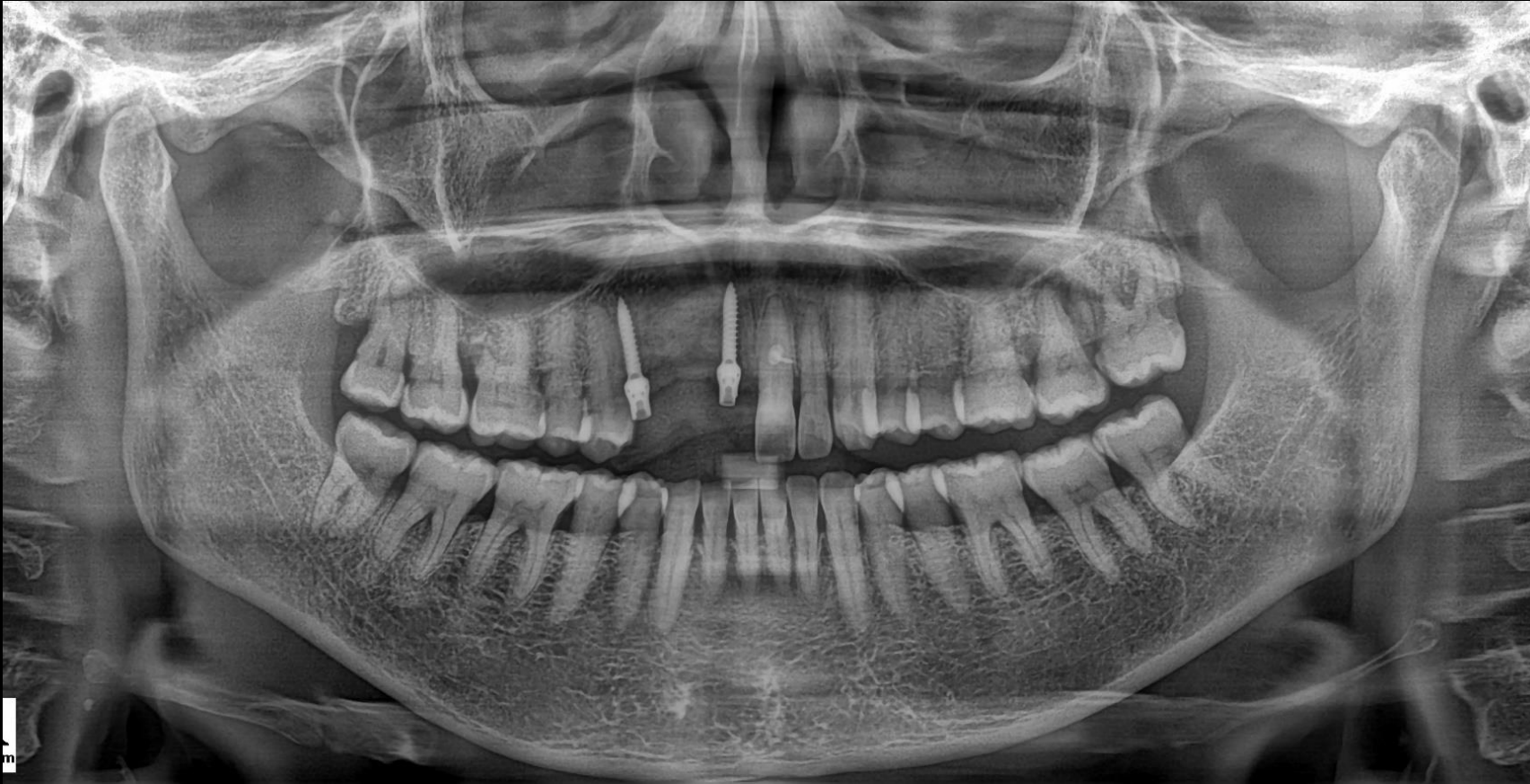Narrow implantation & Contour Augmentation



Surgery

Similar case 1

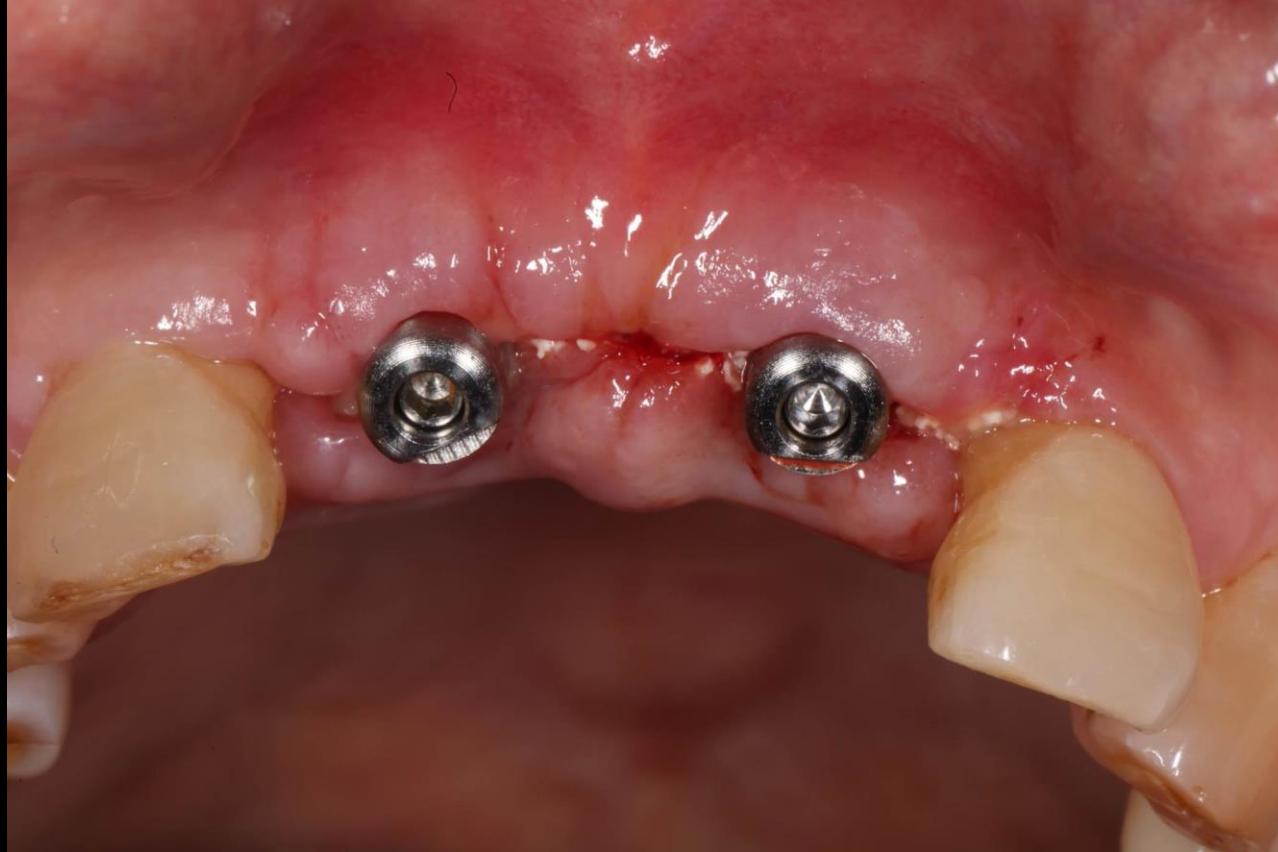Narrow implantation & Contour Augmentation



Post-op

Similar case 1

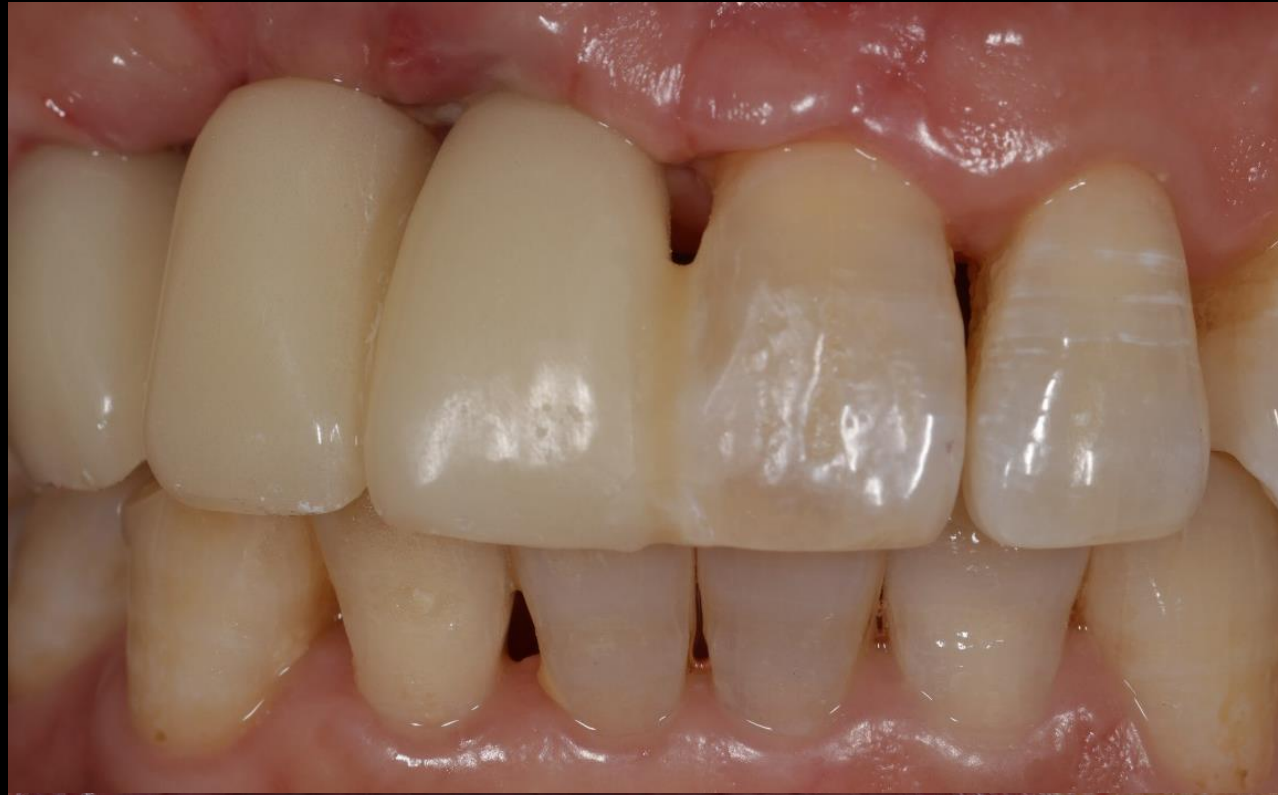Narrow implantation & Contour Augmentation



Healing 2 weeks

Similar case 1

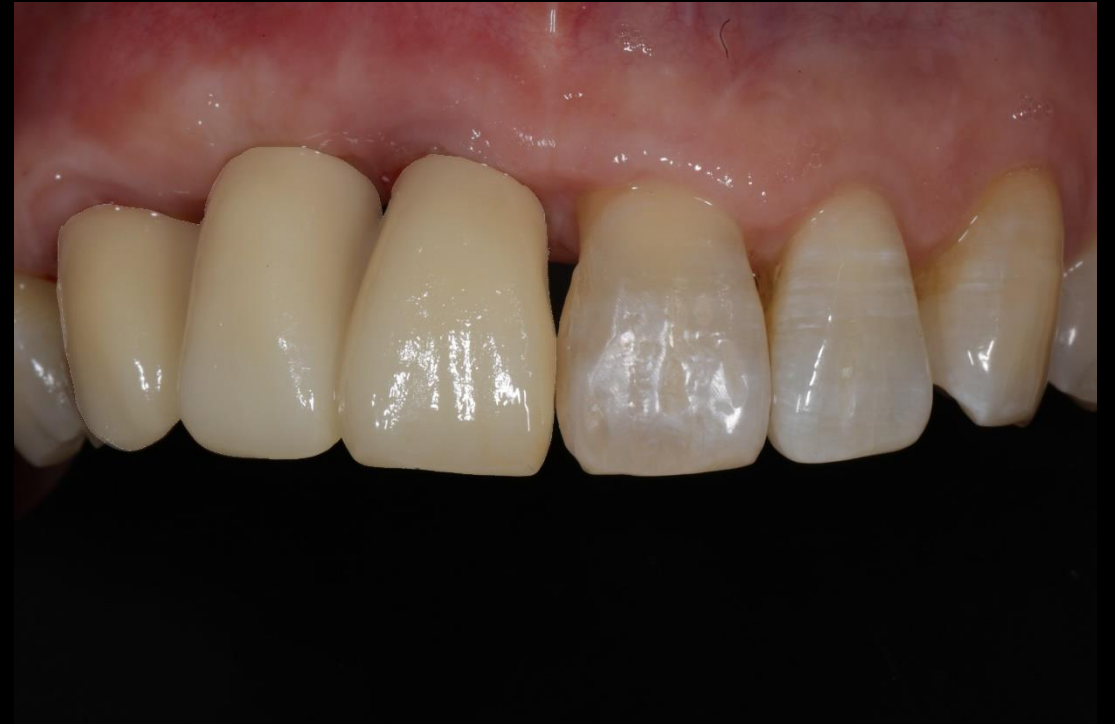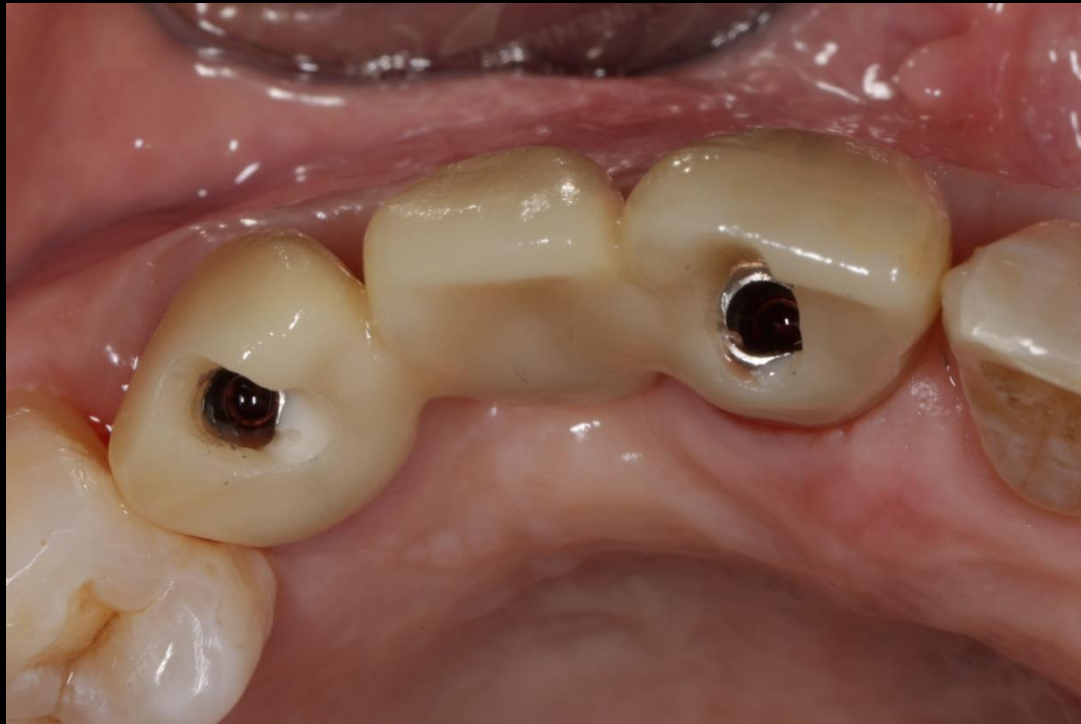Narrow implantation & Contour Augmentation



Provisional restoration

Similar case 1

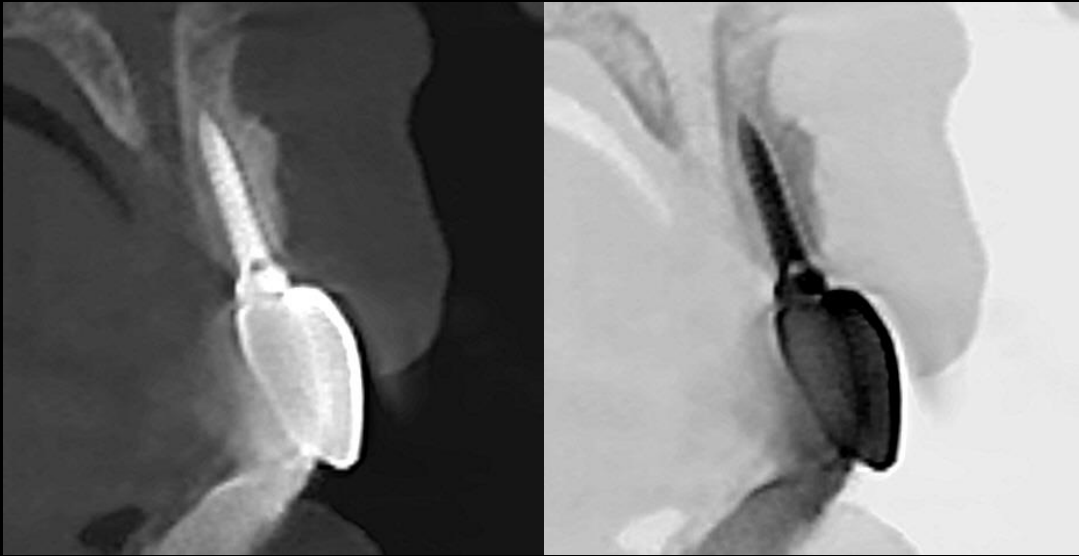
Narrow implantation & Contour Augmentation



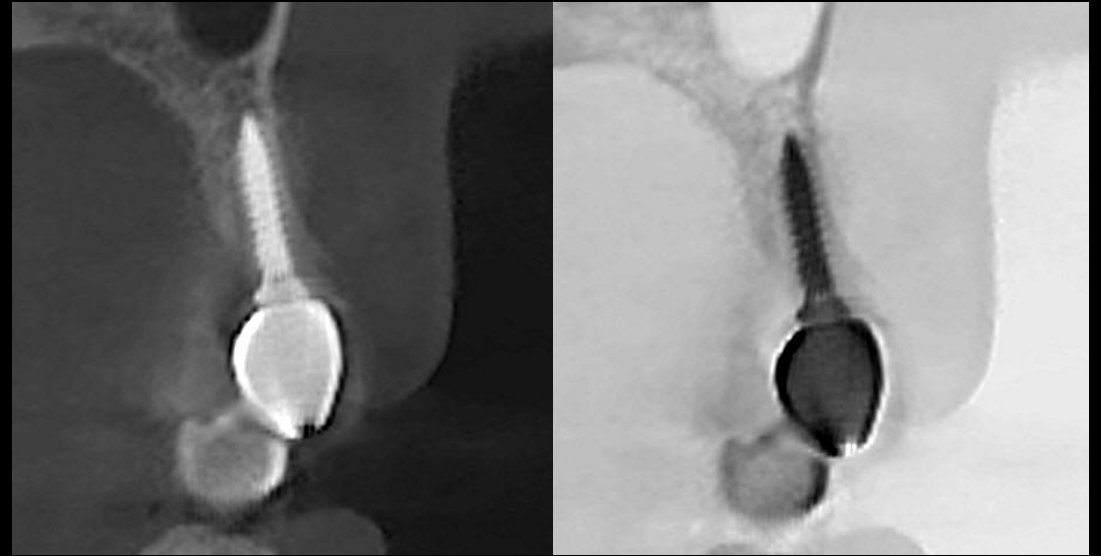
Final prosthesis

Similar case 1

Narrow implantation & Contour Augmentation



#11

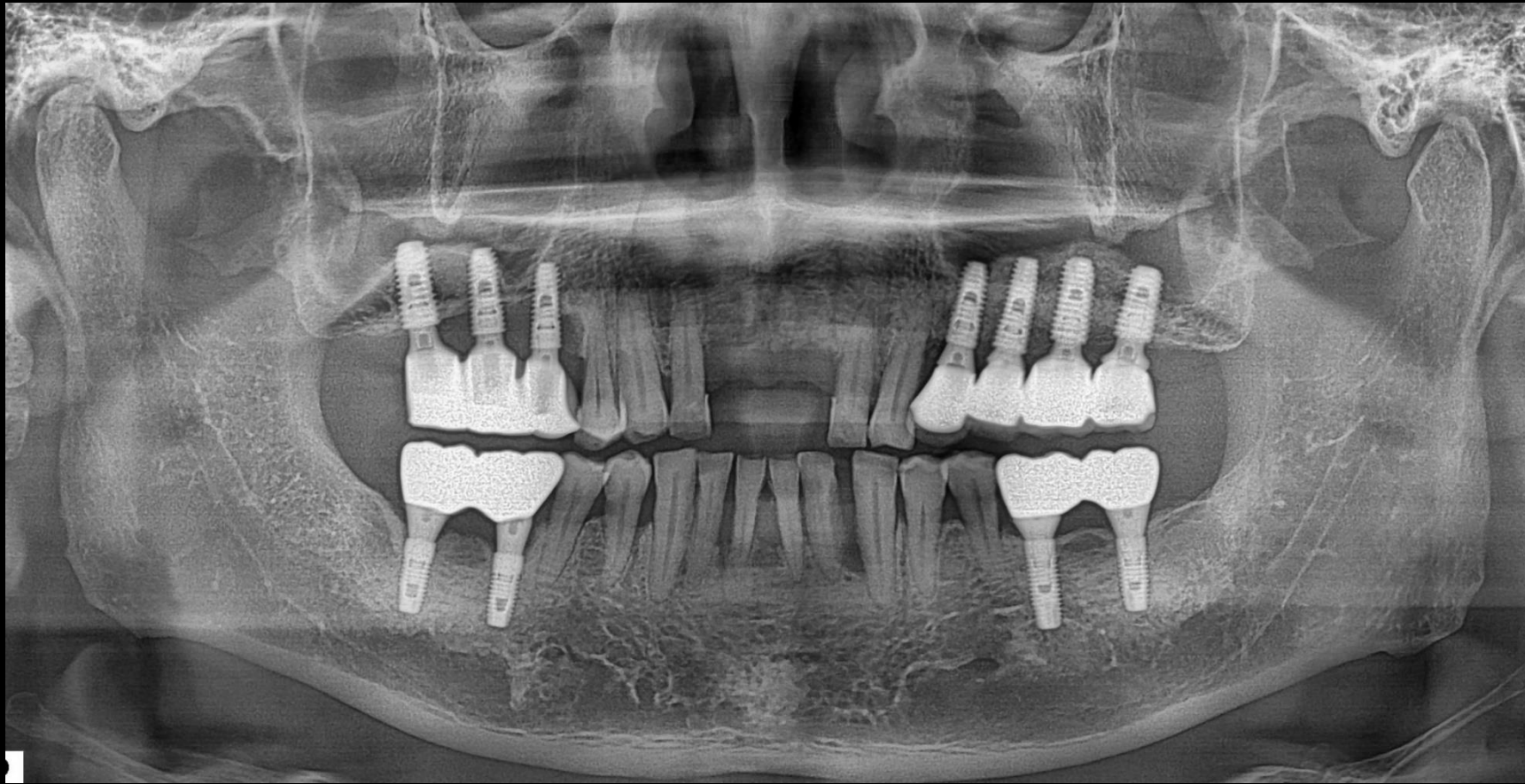


#13

Final prosthesis

Similar case 2

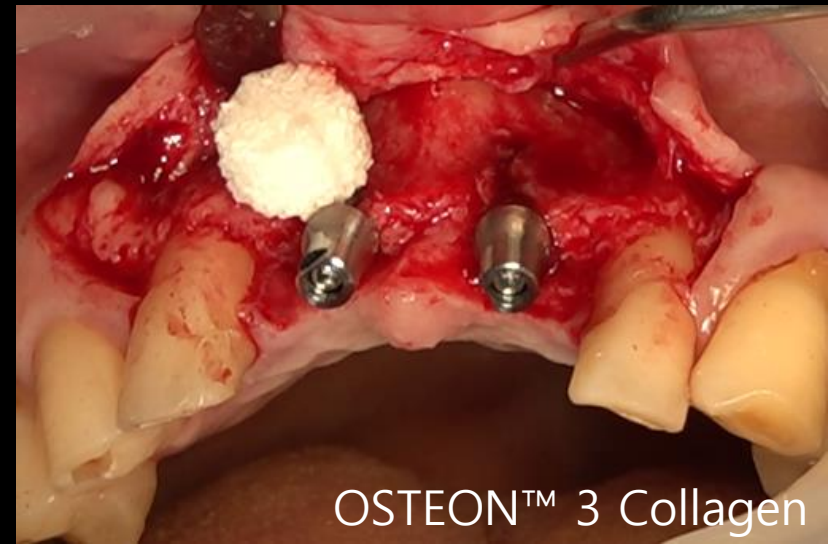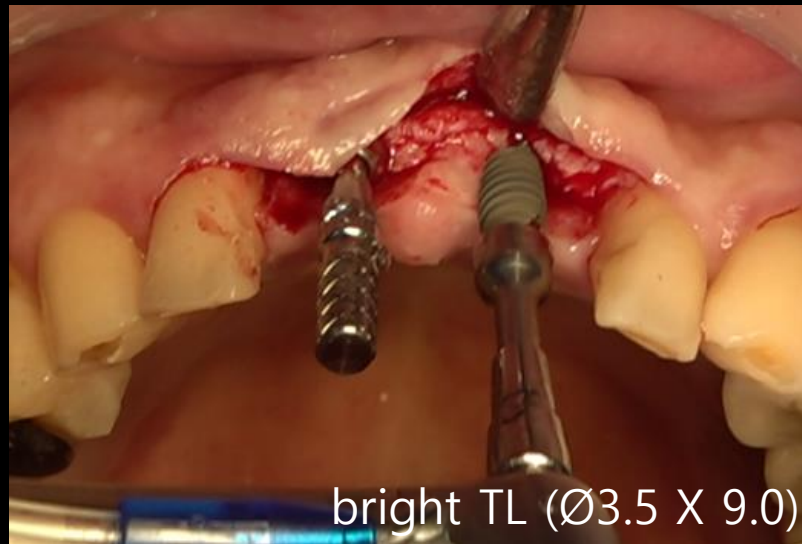
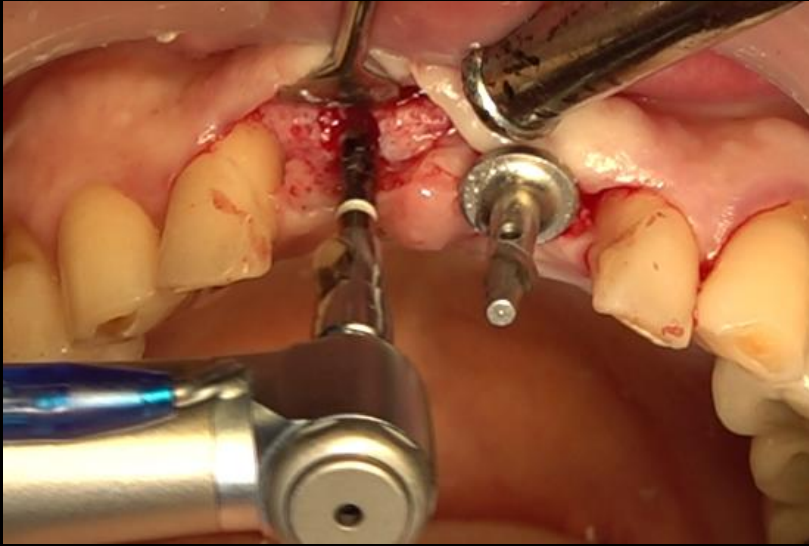
Narrow implantation with bright TL



Pre-op

Similar case 2

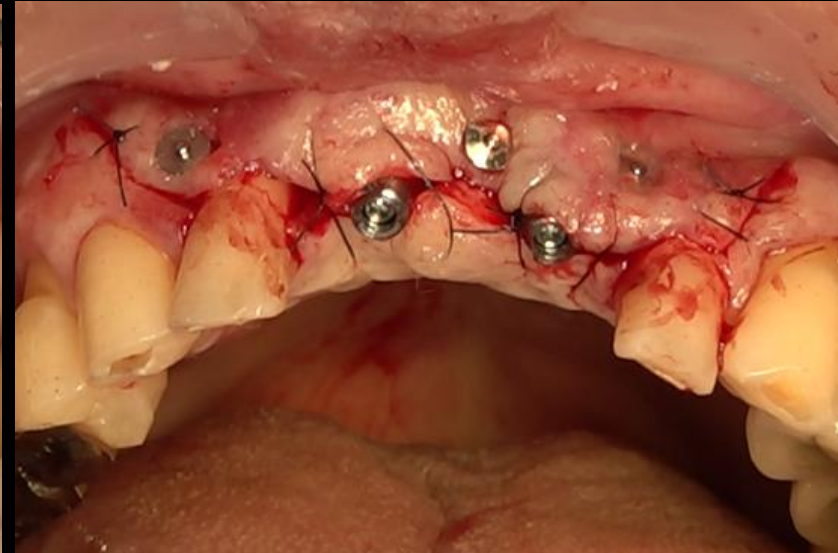
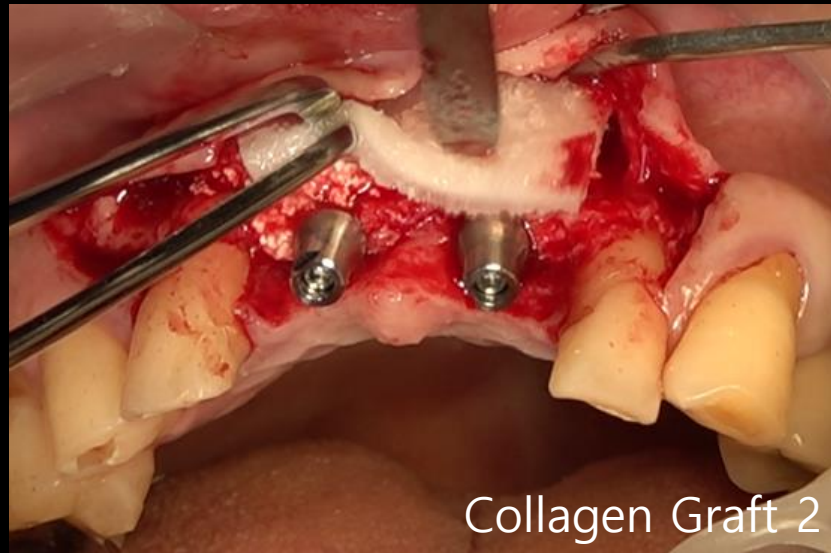
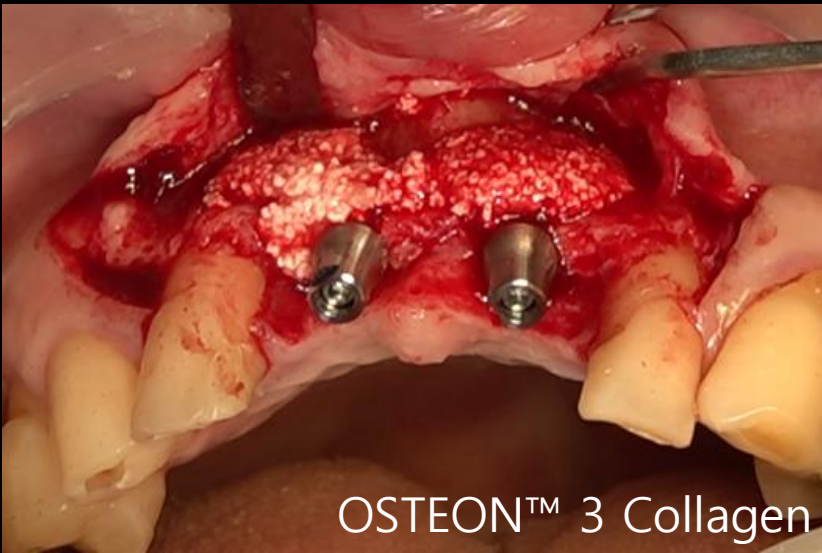
Narrow implantation with bright TL



Surgery

Similar case 2

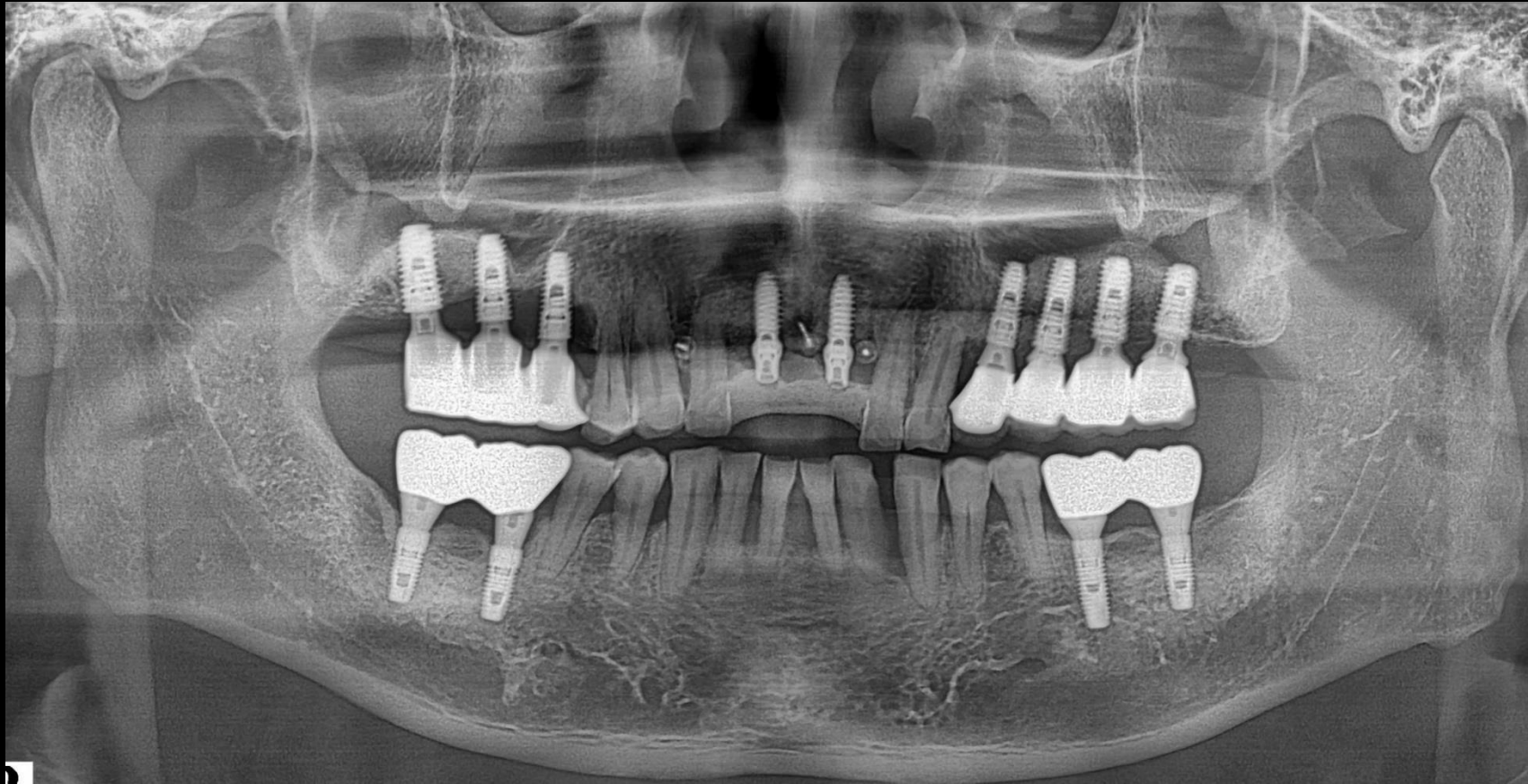Narrow implantation with bright TL



Surgery

Similar case 2

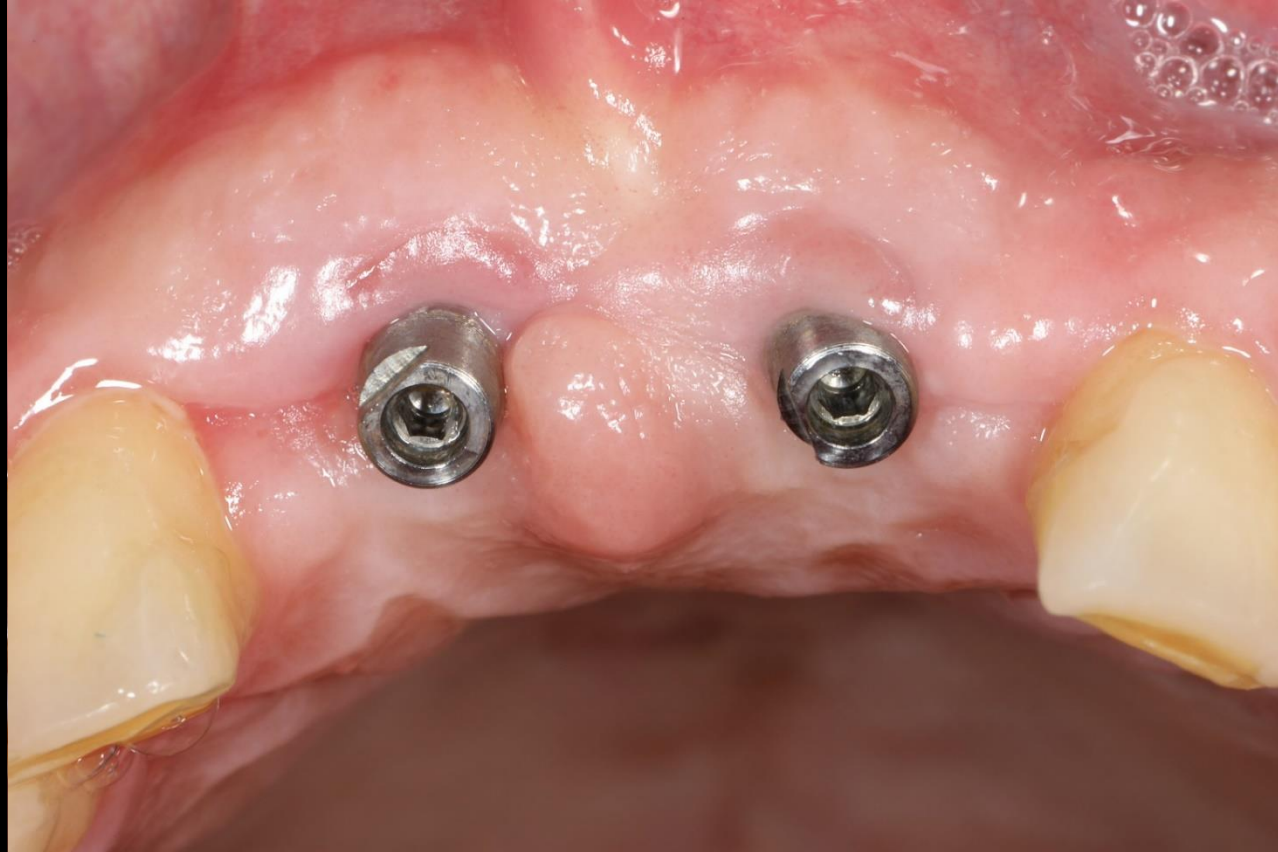
Narrow implantation with bright TL



Post-op

Similar case 2

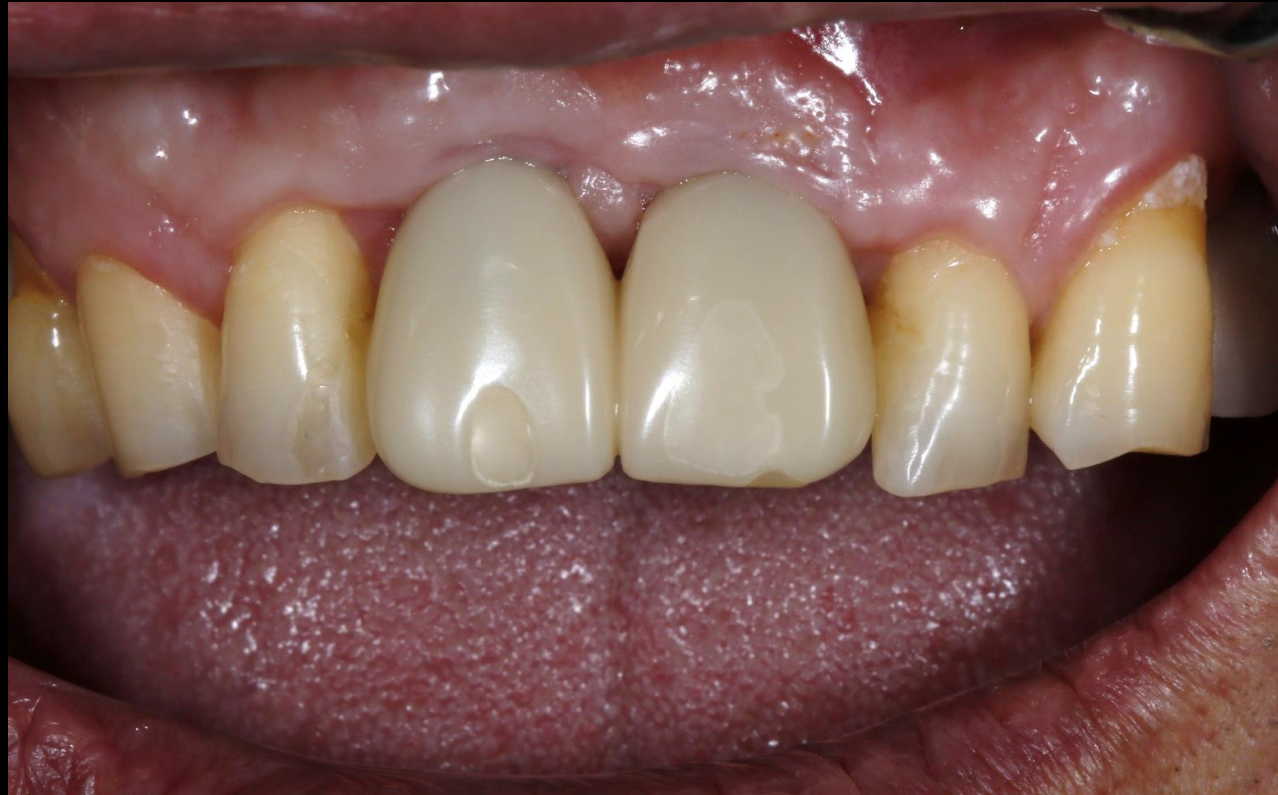Narrow implantation with bright TL



Healing 1 month

Similar case 2

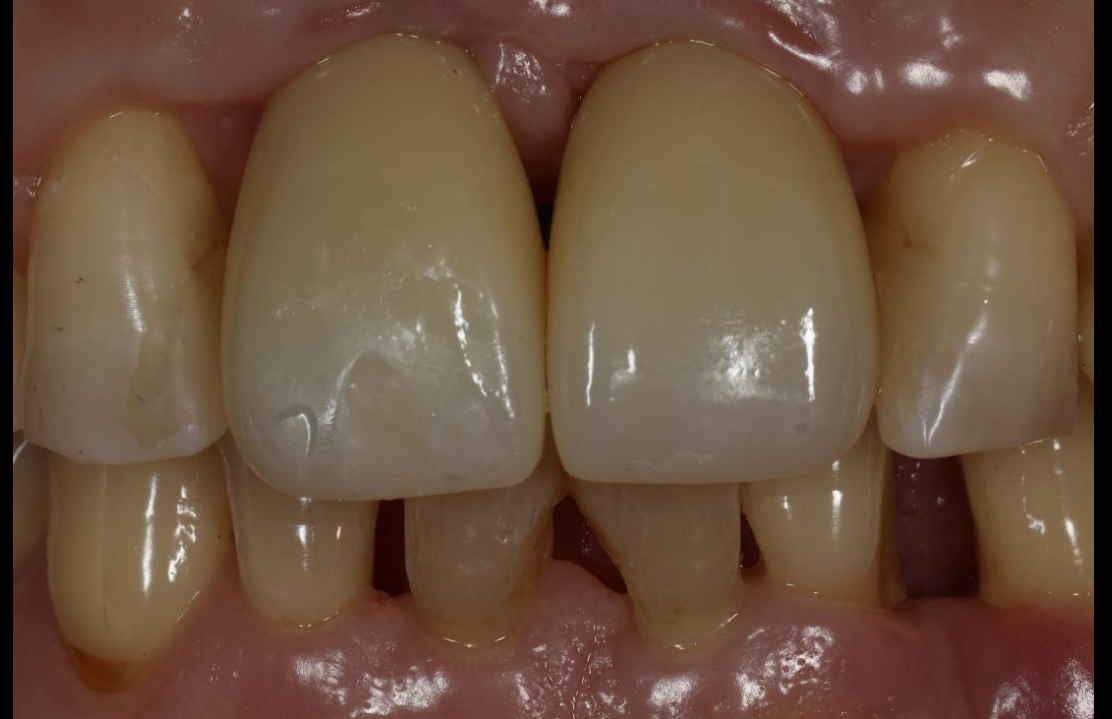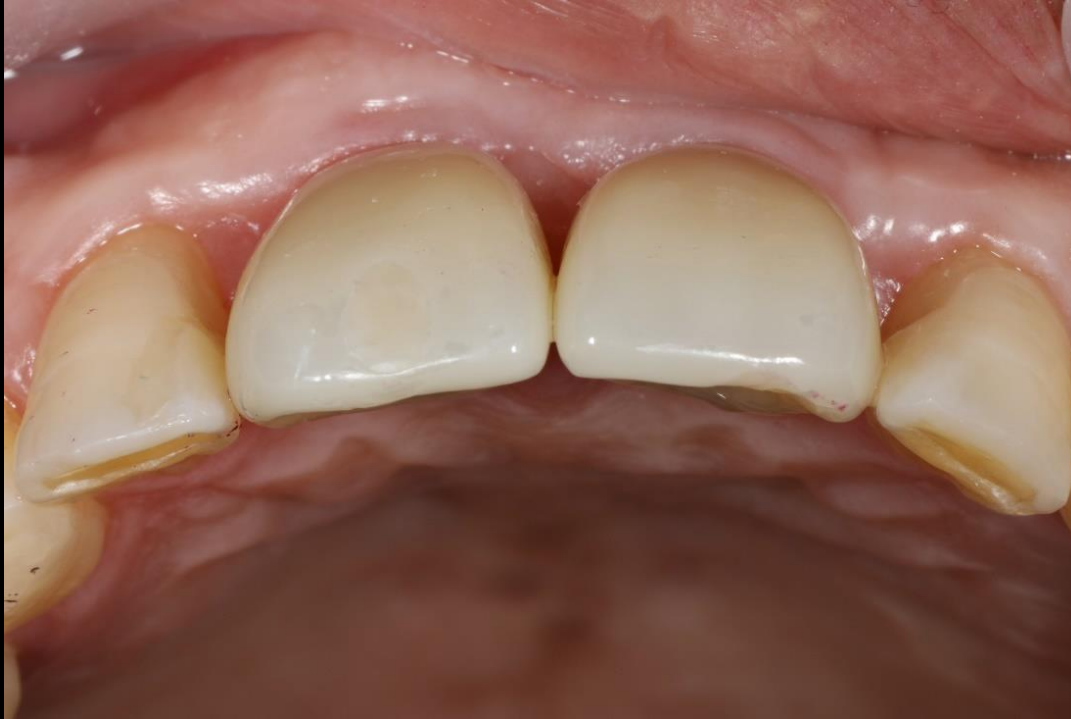Narrow implantation with bright TL



Provisional restoration

Similar case 2

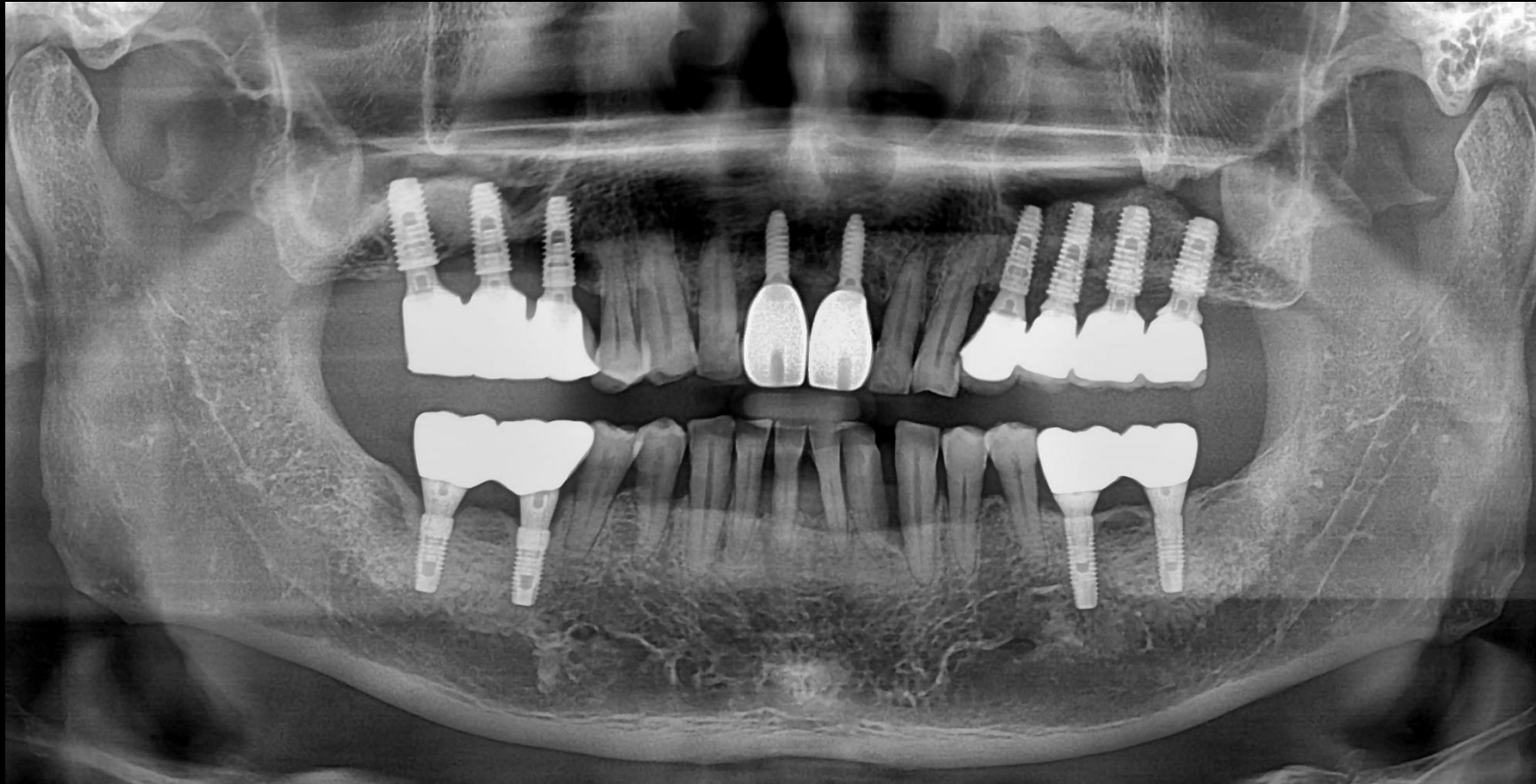
Narrow implantation with bright TL



Final prosthesis

Similar case 2

Narrow implantation with bright TL



Final prosthesis