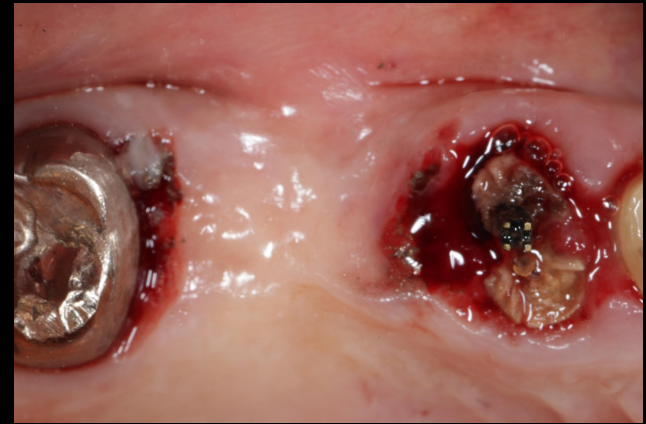
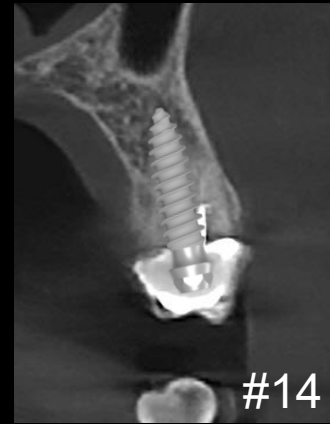
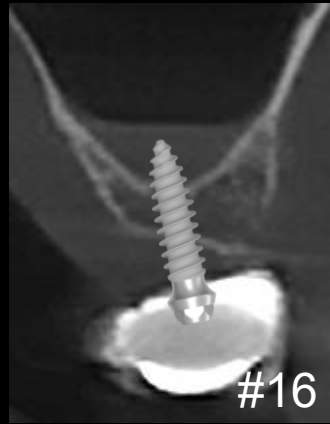
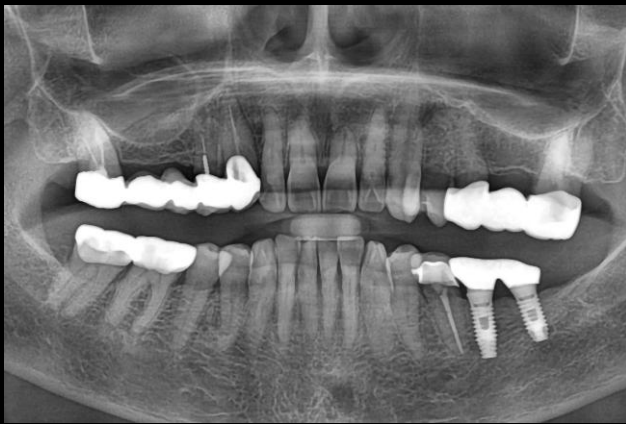 **LIVE** & Follow up

Simple Sinus lifting using Collagen Graft 2



Dr. SM Chung

2025.08.01. (Fri)

Patient Information

Age : 66

Sex : Female

Chief Complaint

: I'd like to get a comprehensive check-up

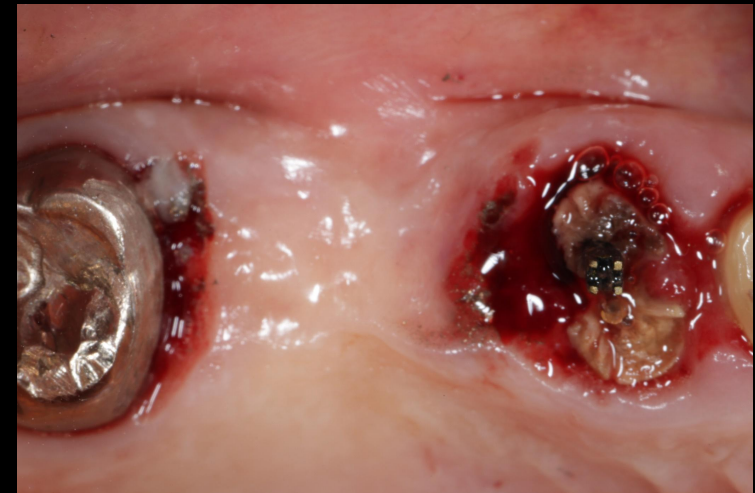
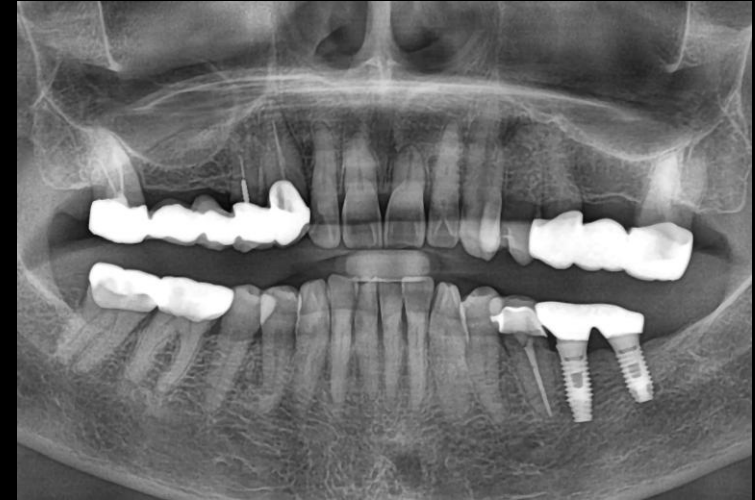Past Dental History


: #13,14,17 endodontic treatment

#15 pontic crown is fractured

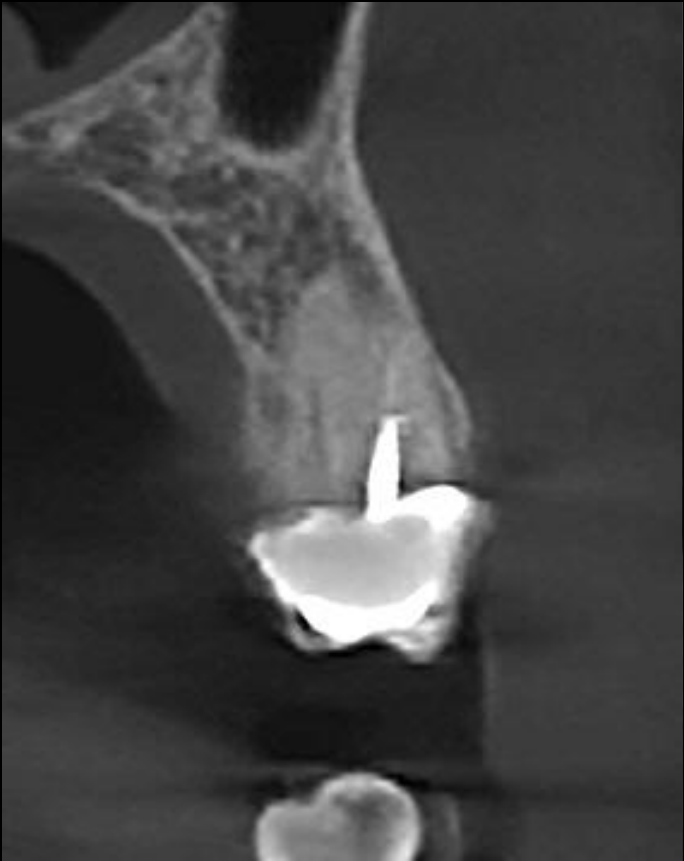Past Medical History

: None



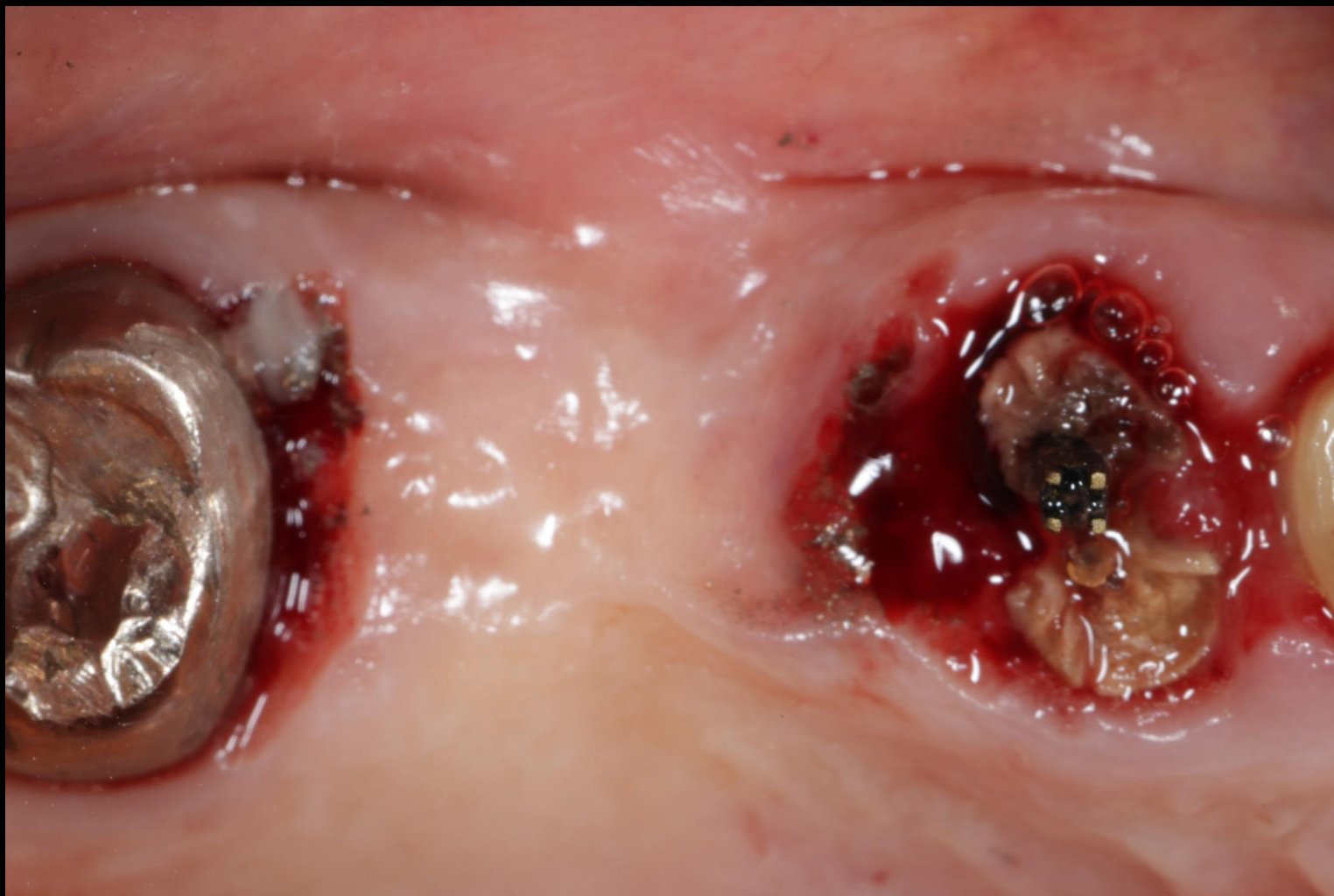

#16

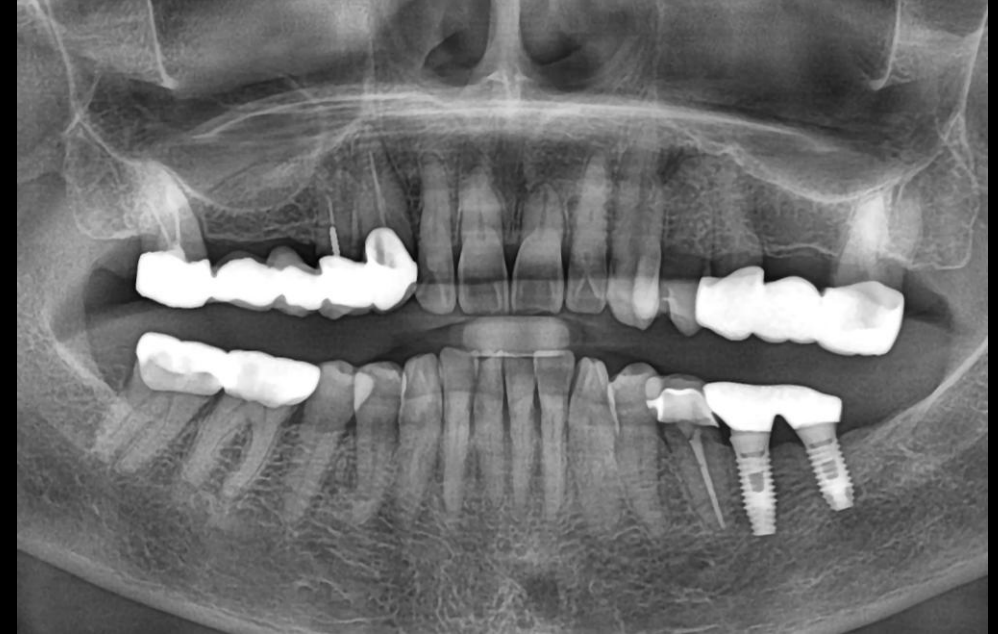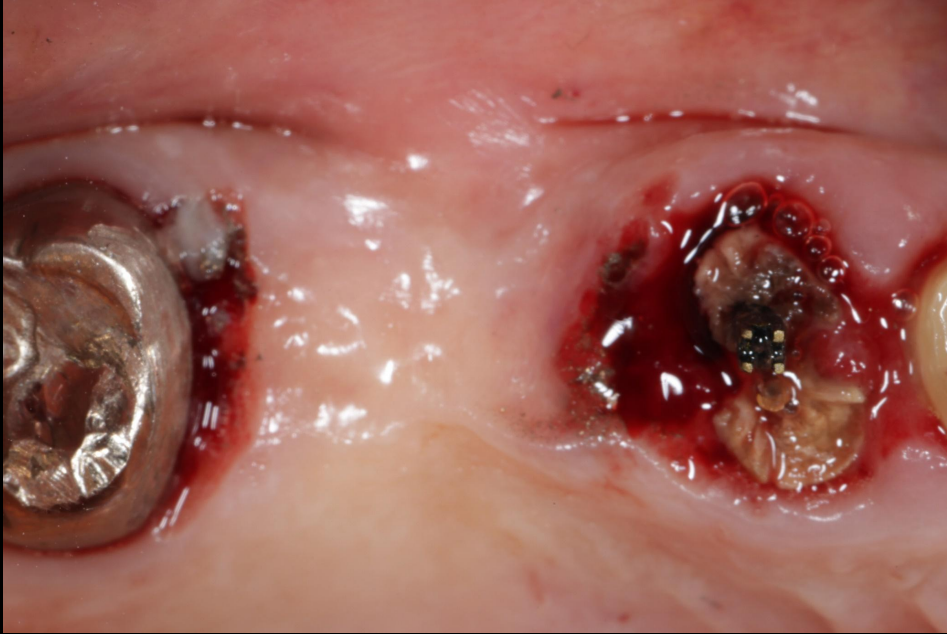


#14

Pre-op



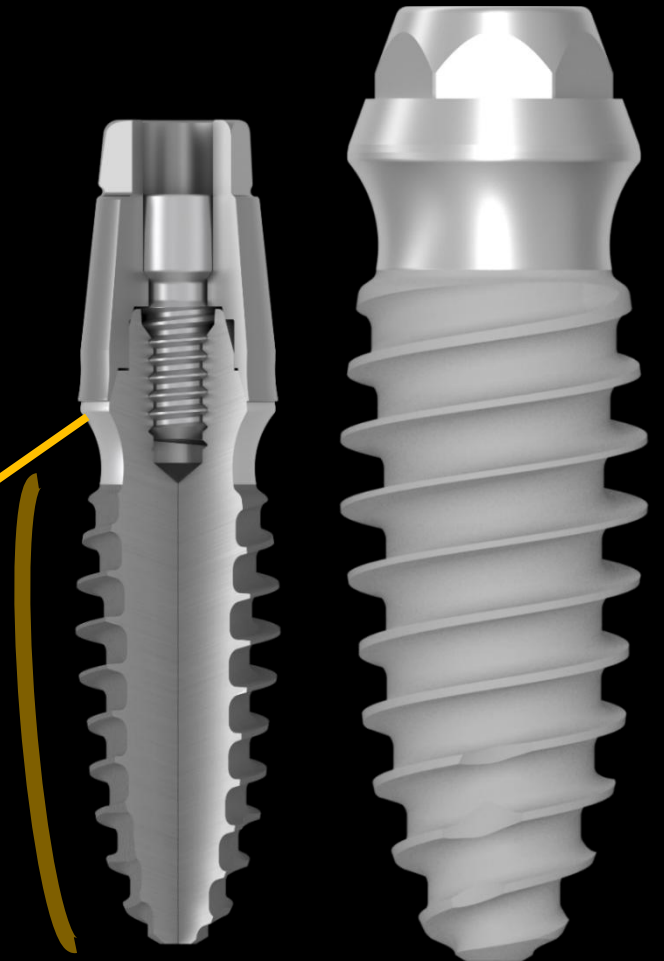
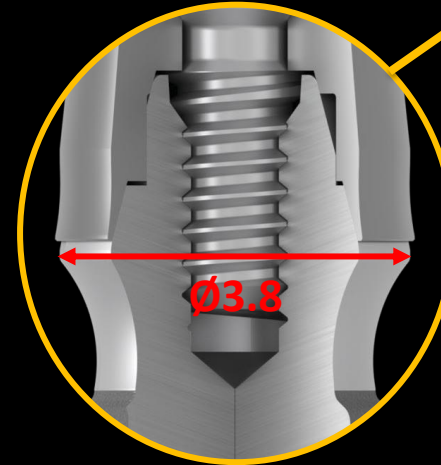
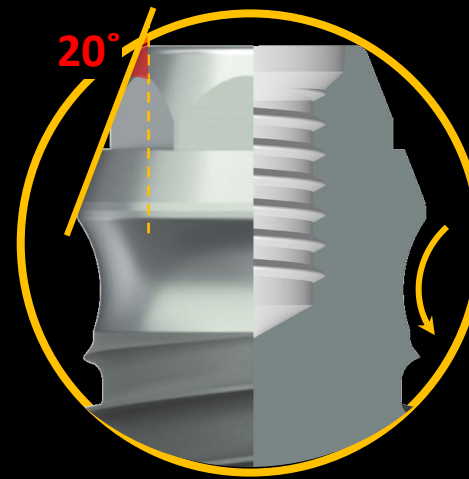
Surgery Plan (#14, 16)




- Sinus Lifting using **Collagen Graft 2, Dask Simple**
- Old bridge removal & Extraction and immediate implantation using **bright Tissue Level**
- Easy Bone Graft with **bright Tissue Level**

bright Implant **Tissue Level**

- ✓ **Narrow, Yet Strong**
 - Excellent Joint Stability
- ✓ **20° External Tapered & External Hex**
 - Excellent Joint Stability
 - Multi Purpose and Easy-to-Use Connection on Trans-Mucosa
- ✓ **Concaved Neck**
 - Better Contour Management for Soft Tissue
- ✓ **Dome Shaped Body**
 - Better Primary Stability
 - Better BIC on Cancellous Bone
 - Marginal Bone Preservation
- ✓ **Ø3.8 Single Platform**
 - One Connection / One Prosthetic Line






DASK *Simple*




Compaction Drill



Lateral Drill




Bone Spreader



Hand Instrument

Compaction Drill




Reverse Direction Cutting

- ✓ Auto bone chip lifting
- ✓ Side bone compaction

Compaction Drill

Single **Built-in Stopper**

- ✓ Safe prevention of perforation
- ✓ Adjustable length of 4–6 mm



Sinus Instrument

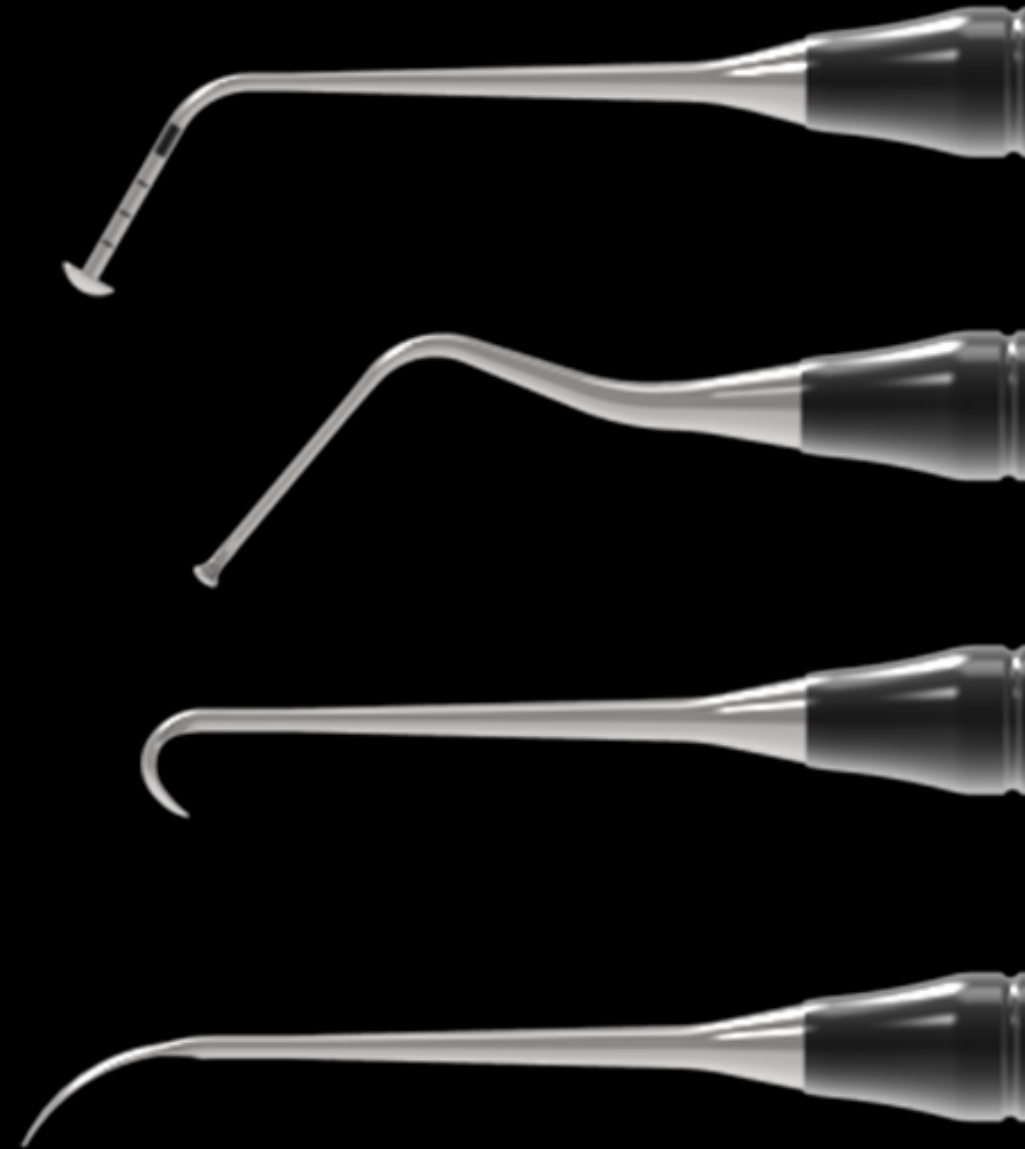

Art. No.

SSE1L

SSE2L

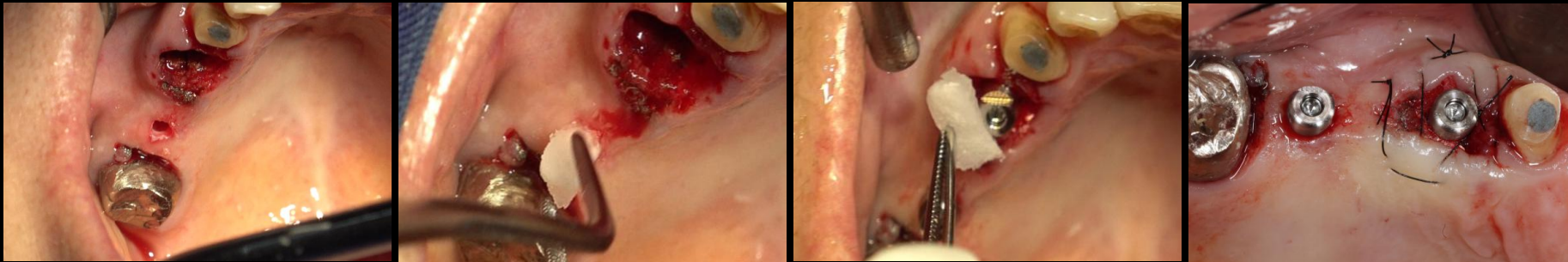SSE3L

SSE4L



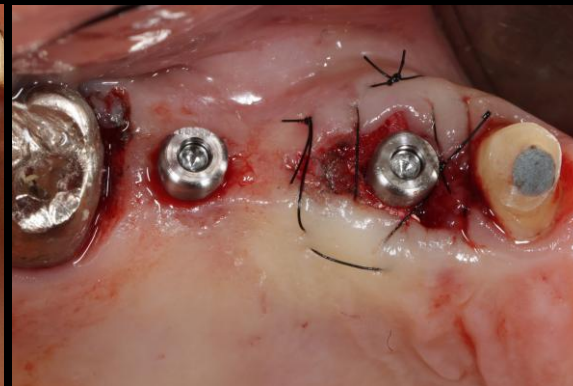
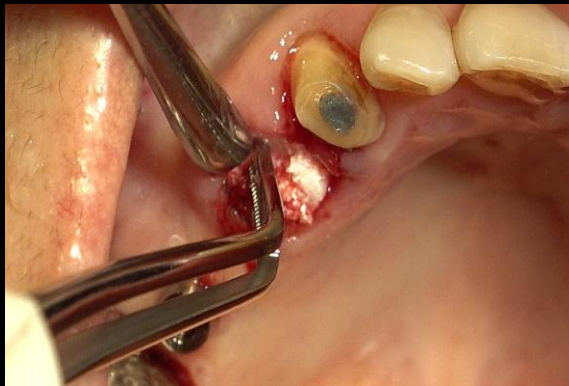
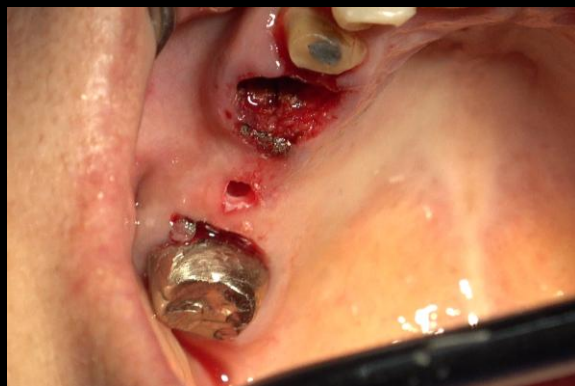Collagen Graft 2

- Ridge preservation
- Porcine tendon derived type I collagen
- Faster soft tissue healing by epithelization



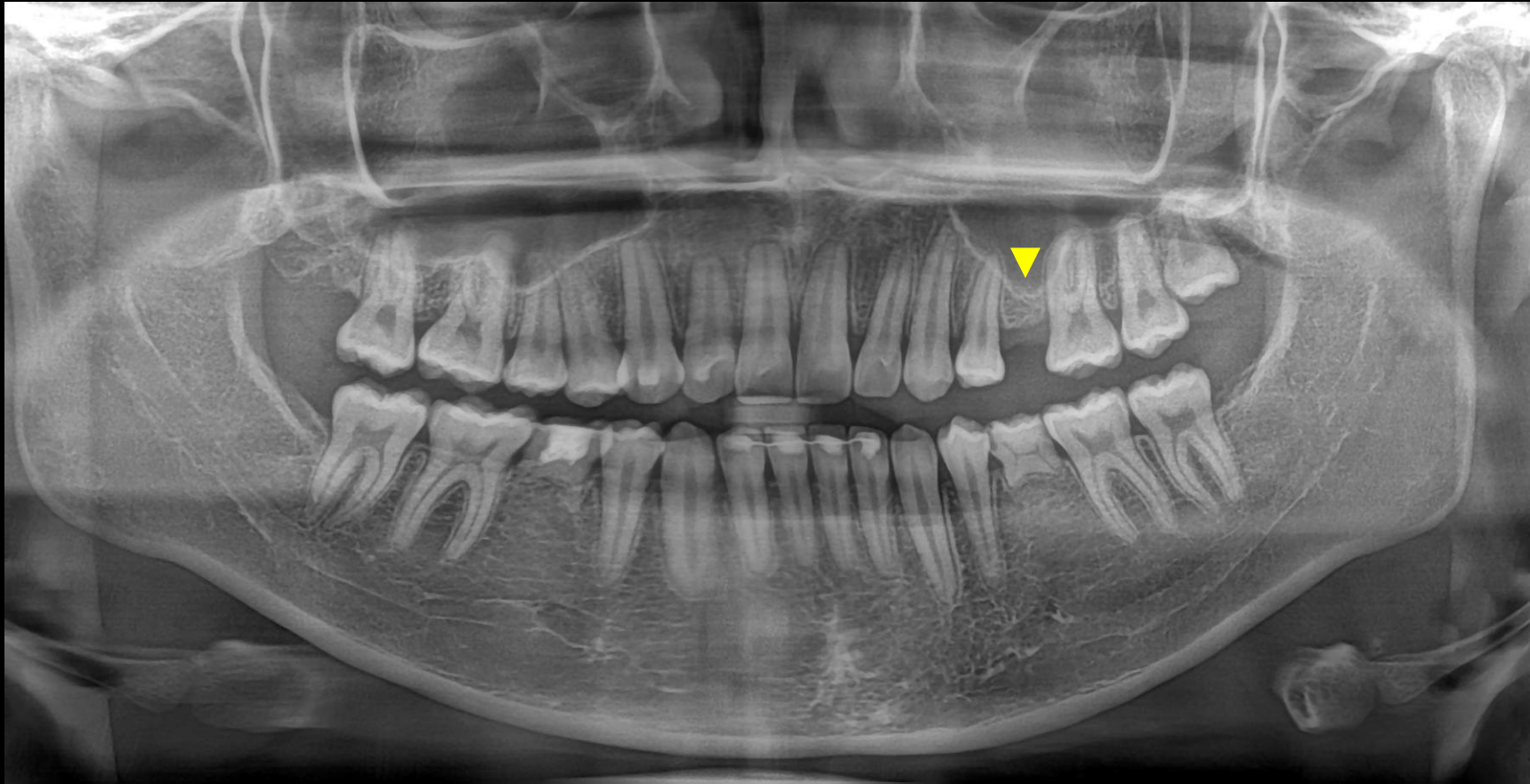
OSTEONTM Xeno Collagen

- Ossification ability of Xeno graft
- Easy handling of collagenized bone graft
- Optimal collagen absorption speed



Similar case 1

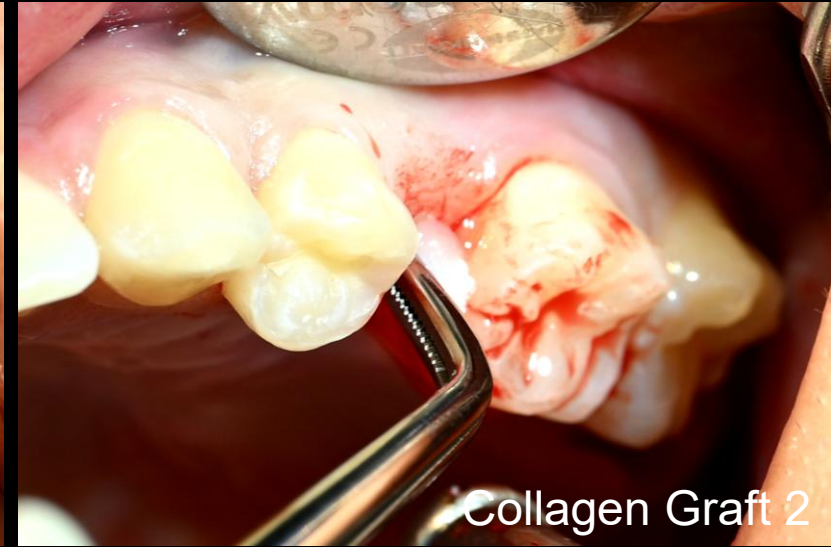
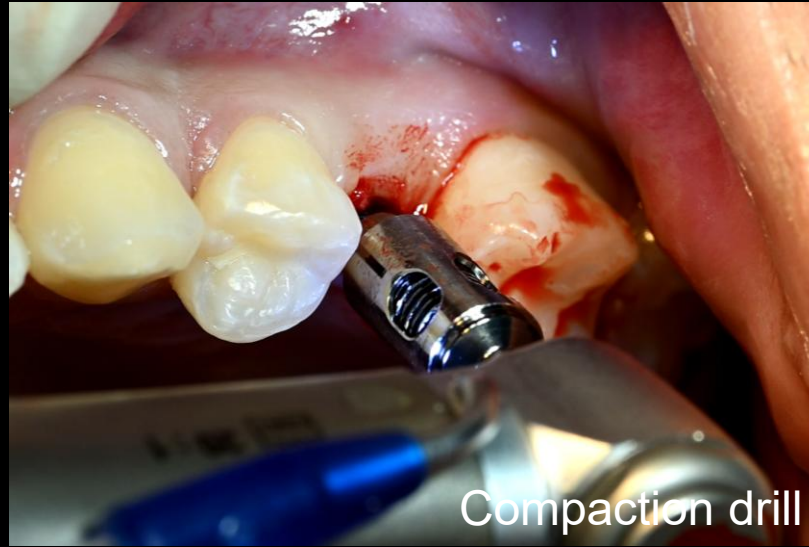
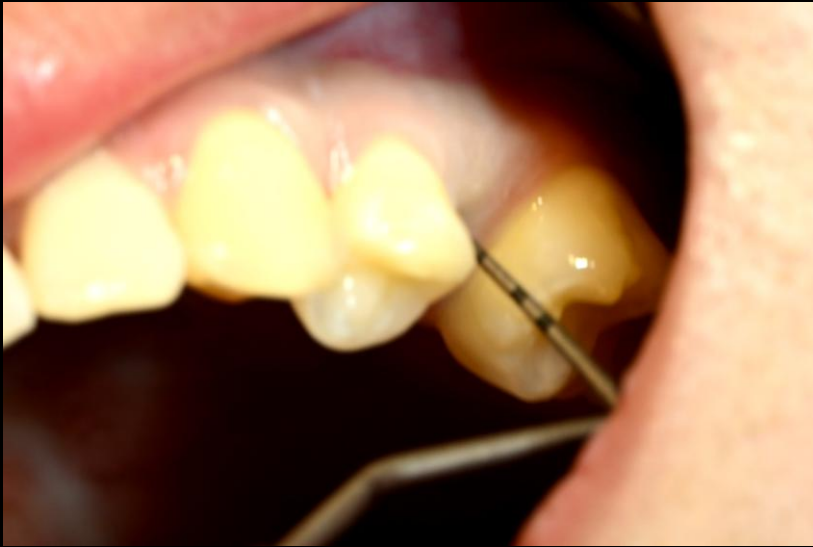Crestal approach for Sinus lifting using Collagen Graft 2



Pre-op

Similar case 1

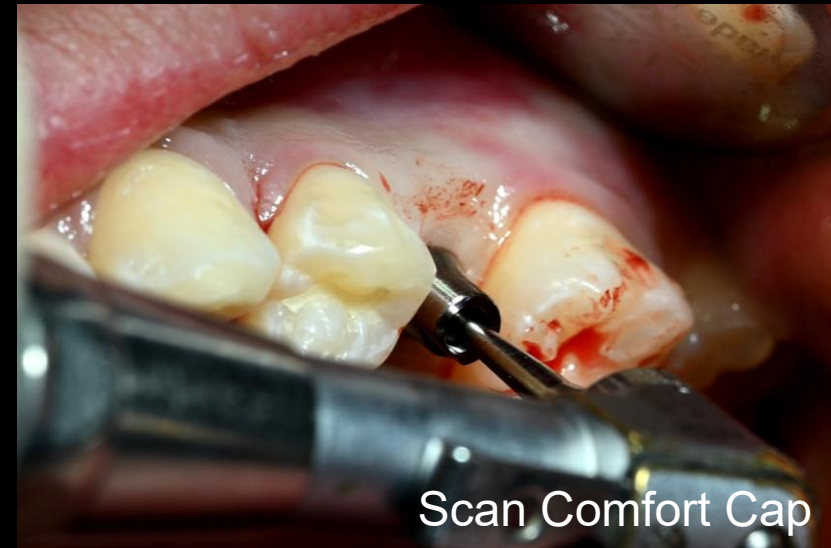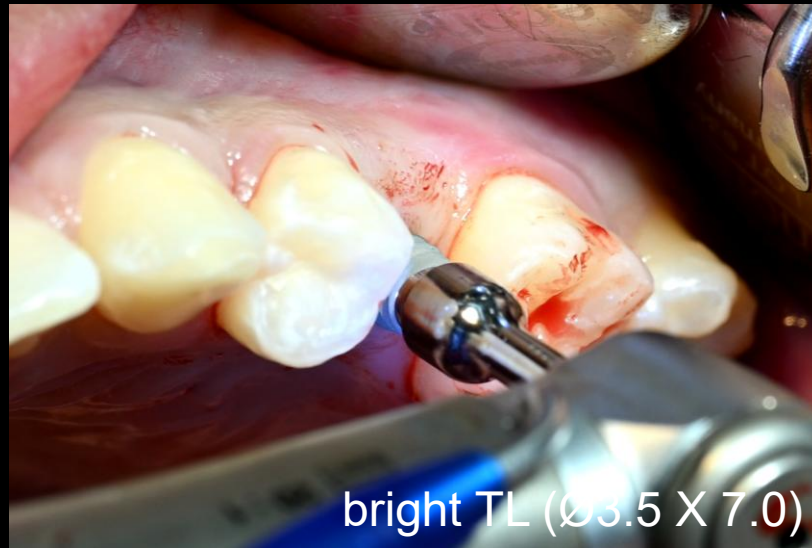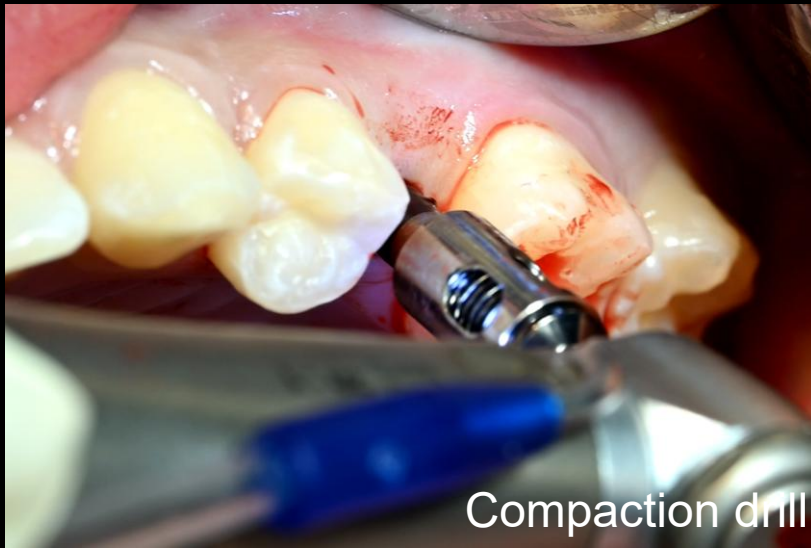Crestal approach for Sinus lifting using Collagen Graft 2



Surgery

Similar case 1

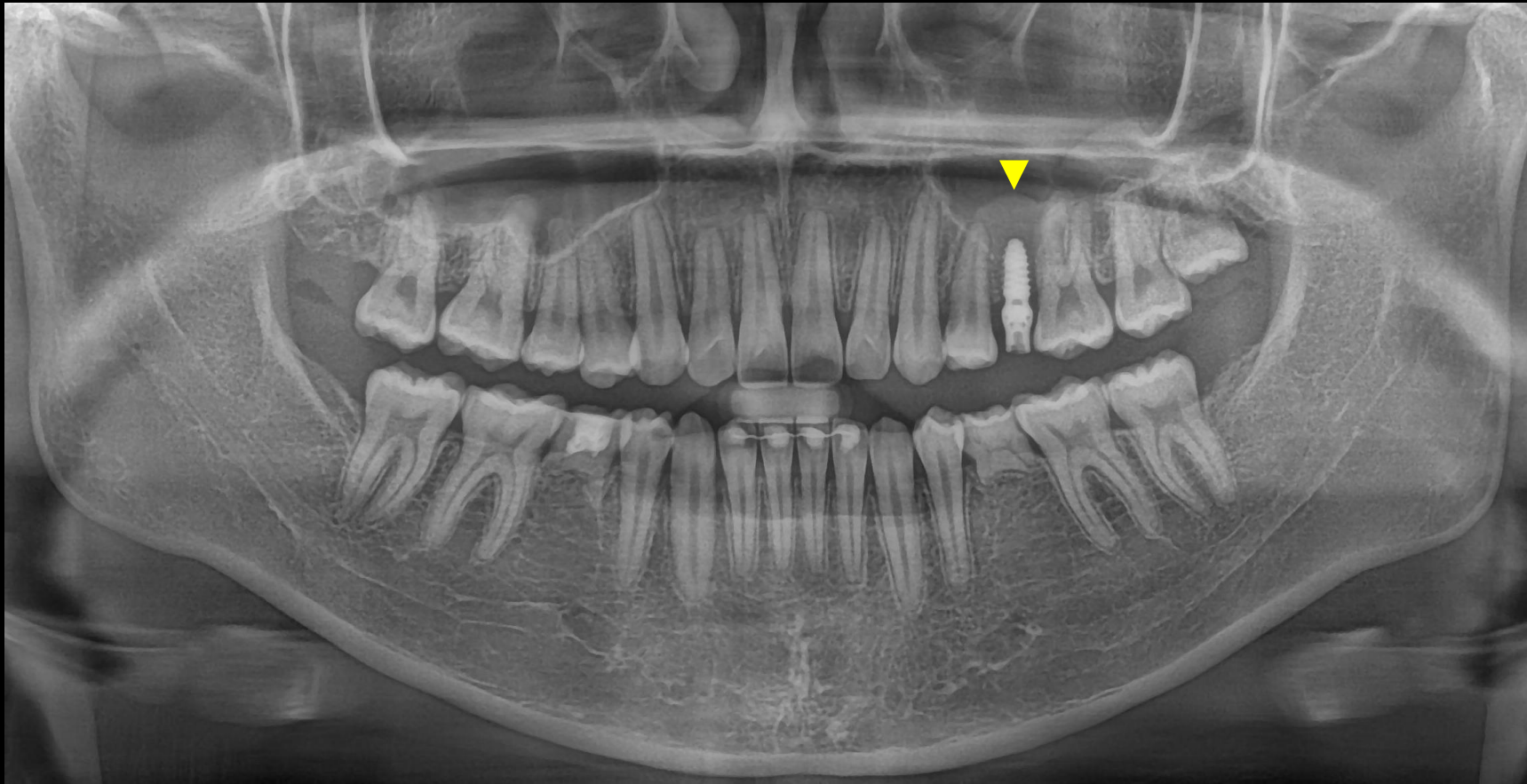
Crestal approach for Sinus lifting using Collagen Graft 2



Surgery

Similar case 1

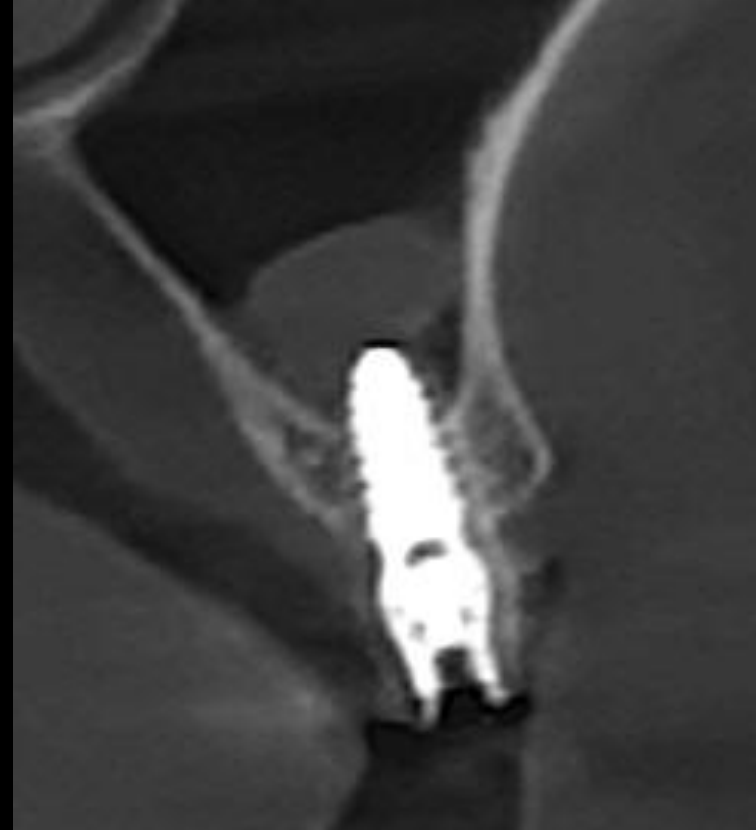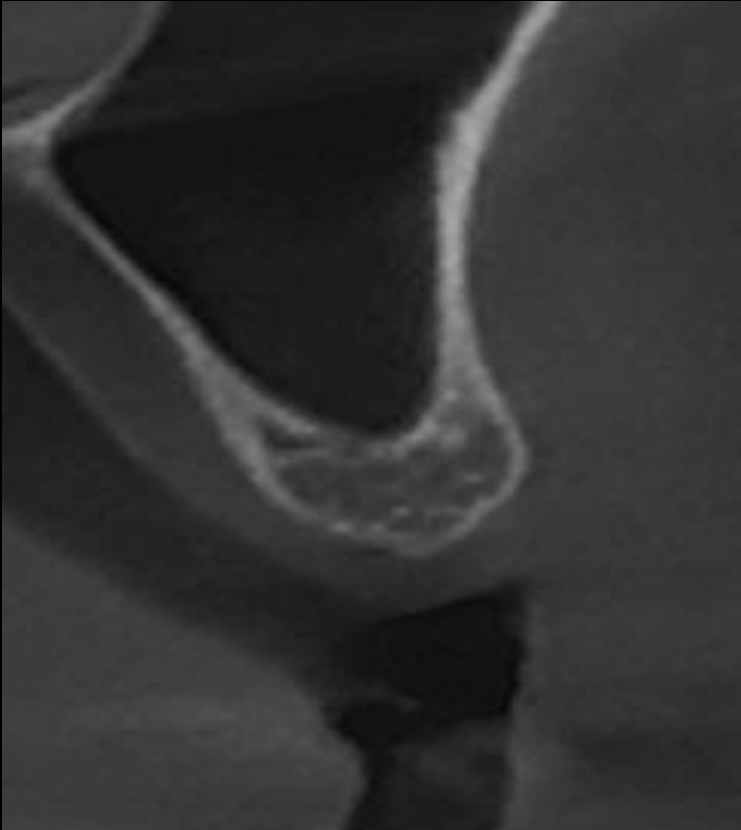
Crestal approach for Sinus lifting using Collagen Graft 2



Post-op

Similar case 1

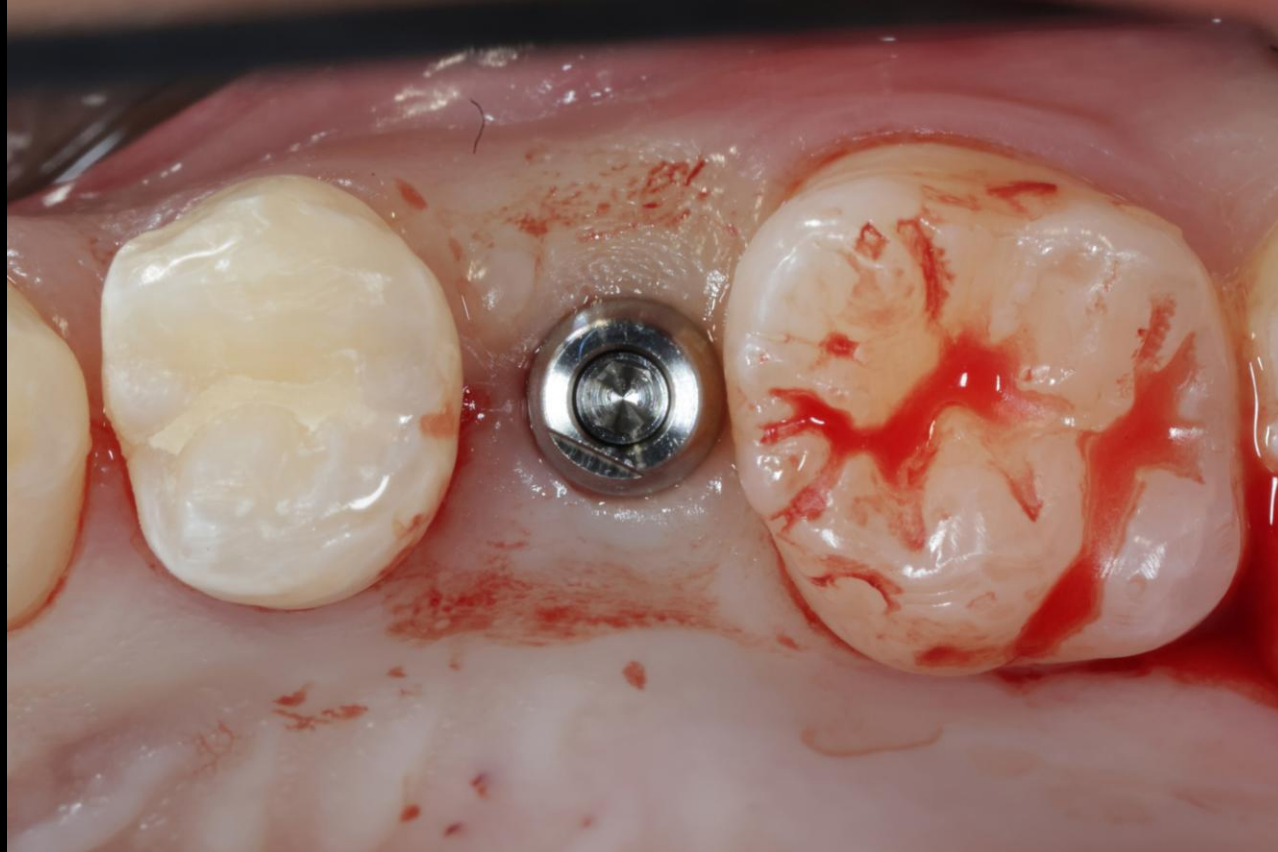
Crestal approach for Sinus lifting using Collagen Graft 2



Pre-op CT / Post-op CT

Similar case 1

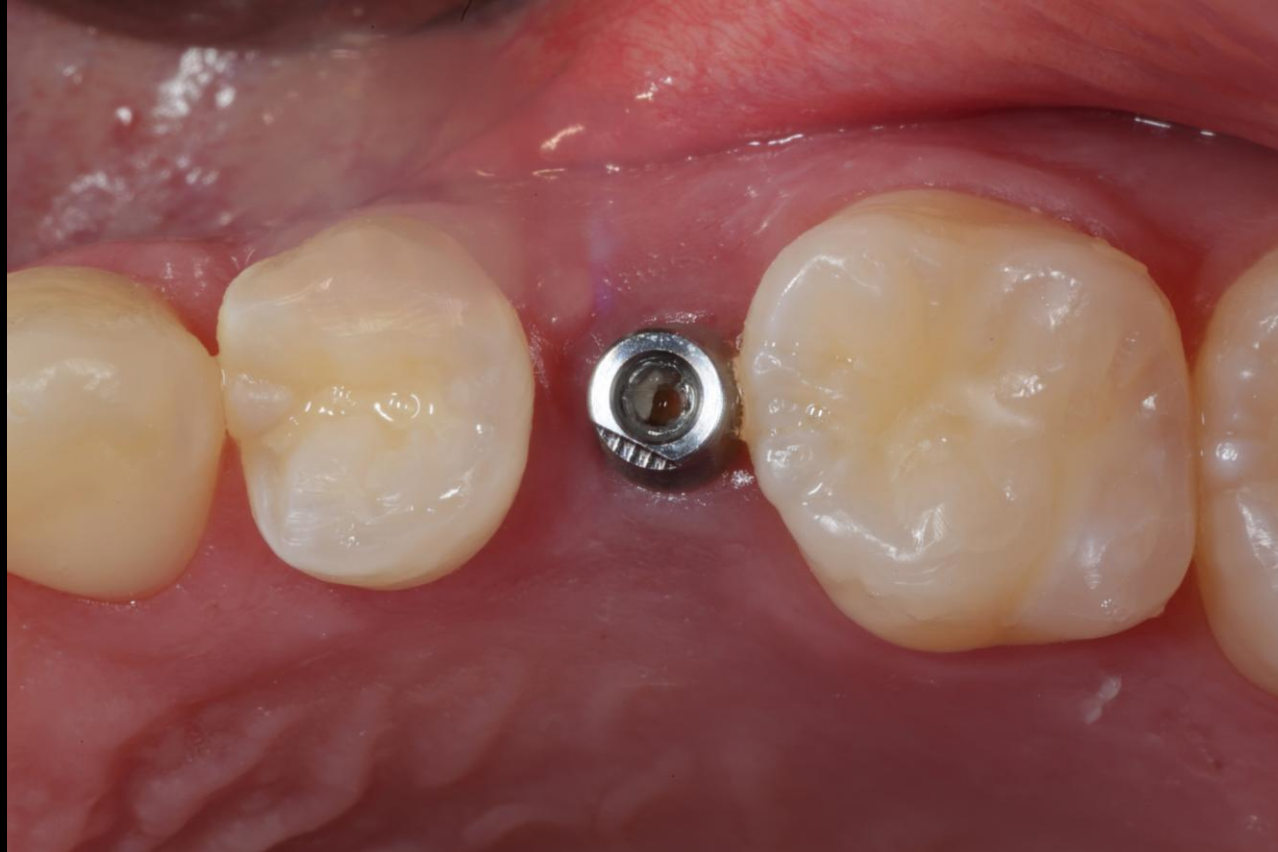
Crestal approach for Sinus lifting using Collagen Graft 2



Post-op

Similar case 1

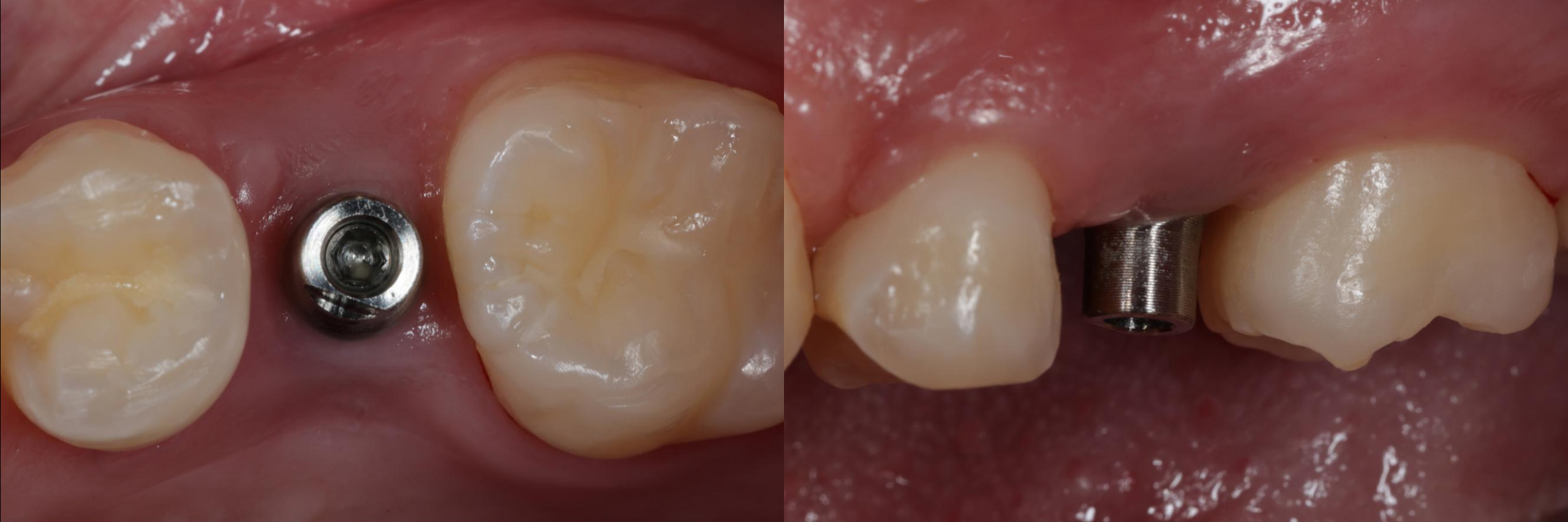Crestal approach for Sinus lifting using Collagen Graft 2



Healing : 3 weeks

Similar case 1

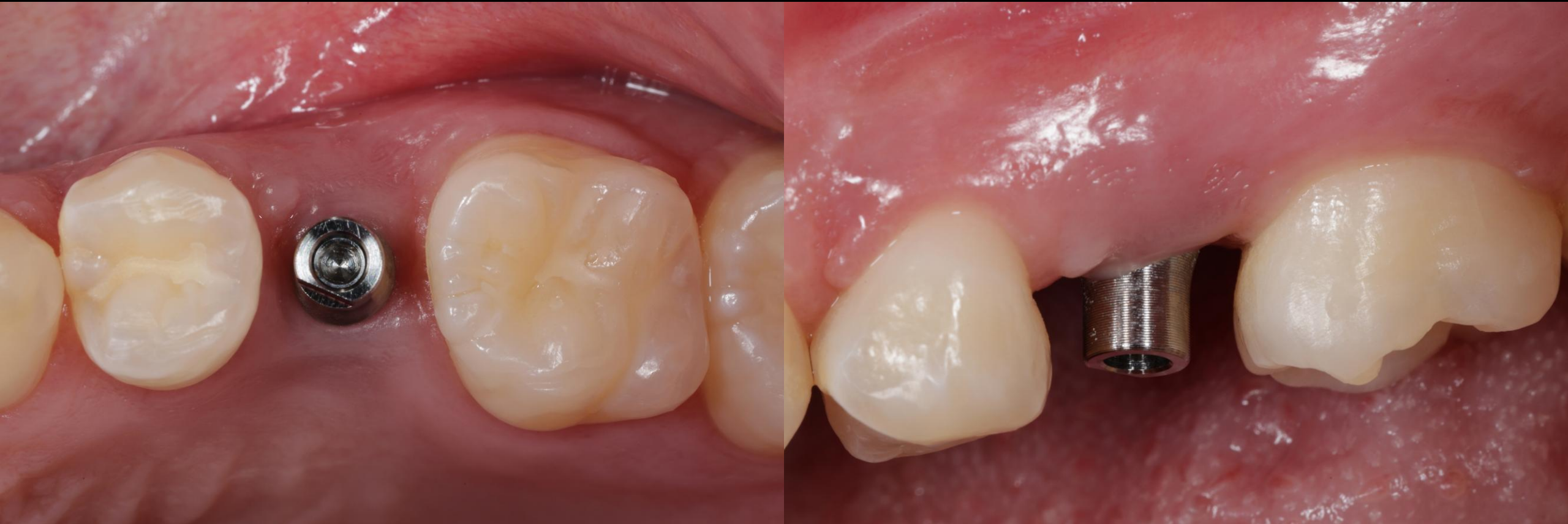Crestal approach for Sinus lifting using Collagen Graft 2



Healing : 3 months

Similar case 1

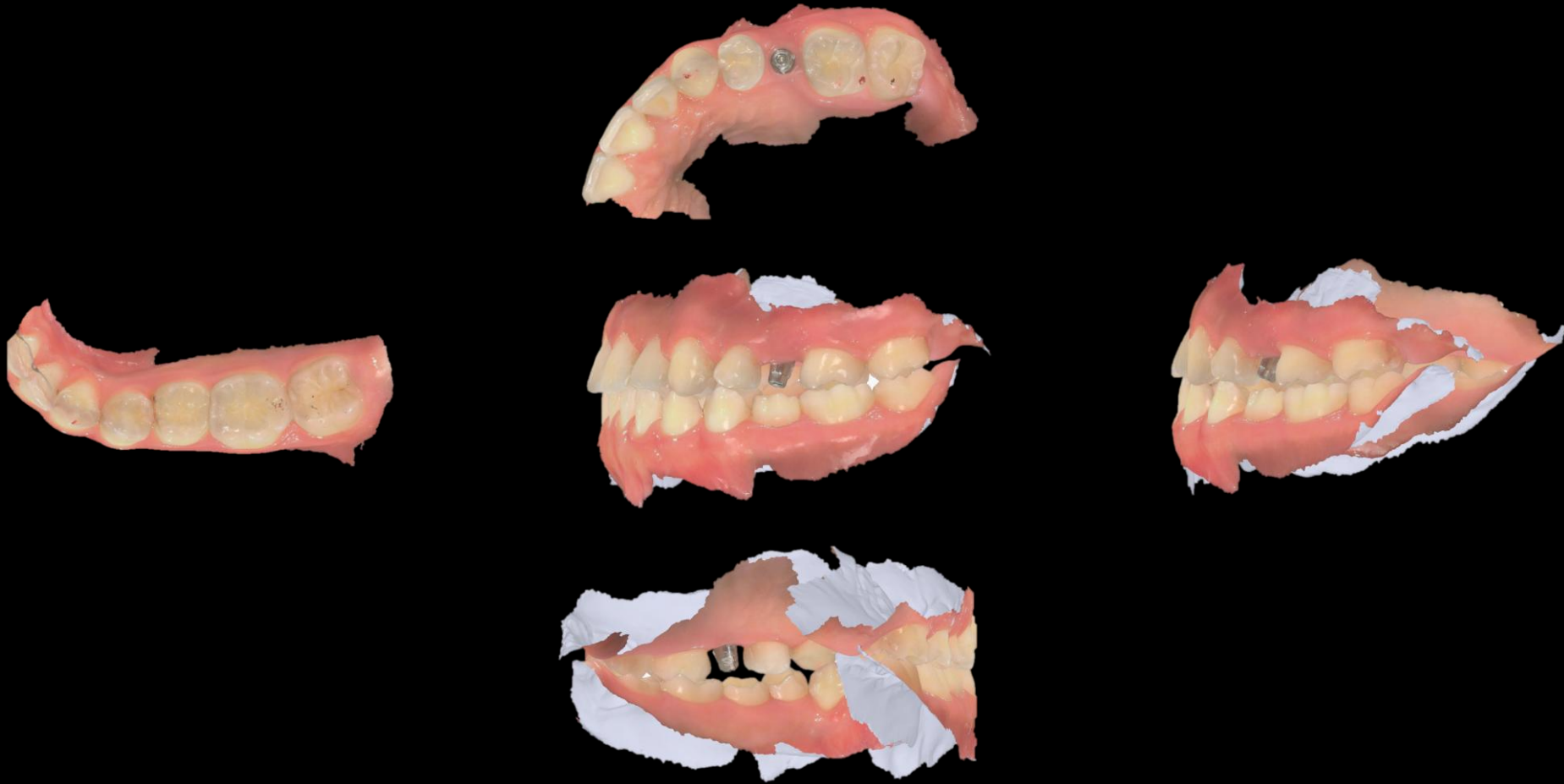Crestal approach for Sinus lifting using Collagen Graft 2



Healing : 6 months

Similar case 1

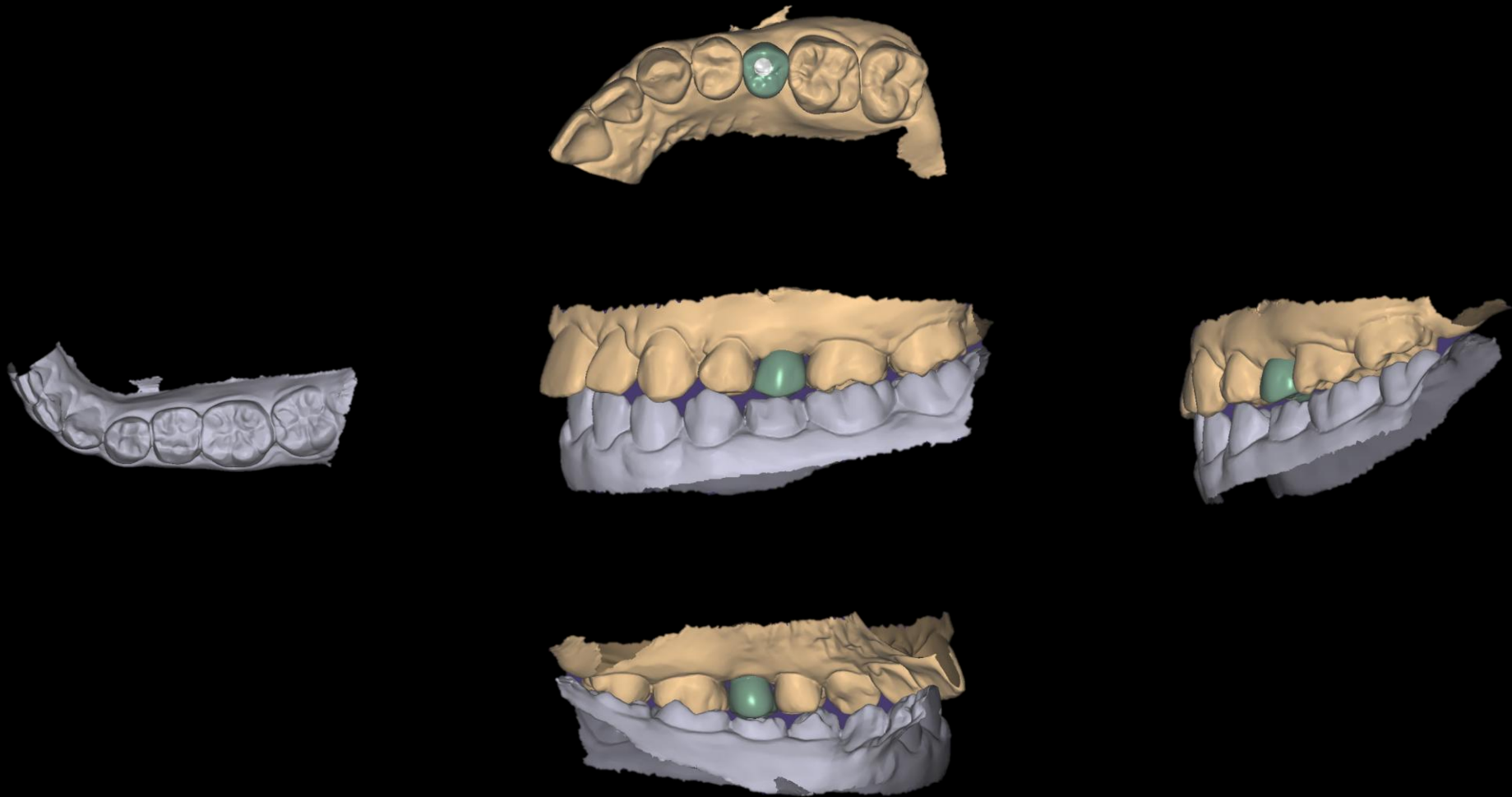
Crestal approach for Sinus lifting using Collagen Graft 2



Intra Oral Scan

Similar case 1

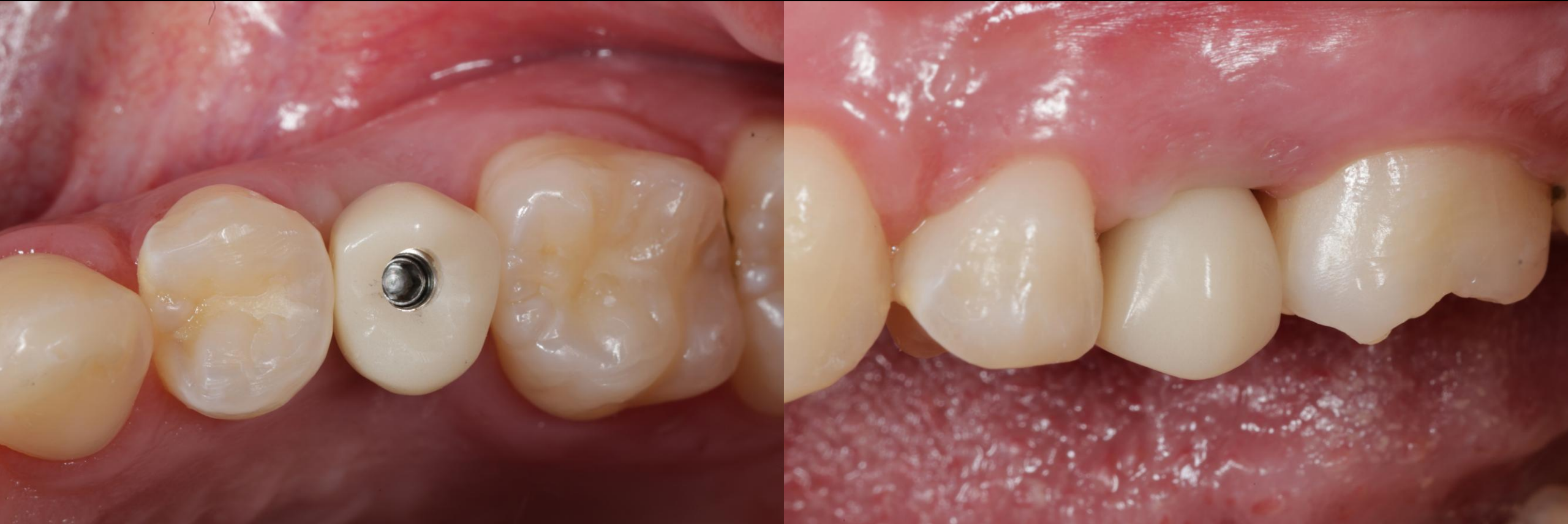Crestal approach for Sinus lifting using Collagen Graft 2



CAD(Temp)

Similar case 1

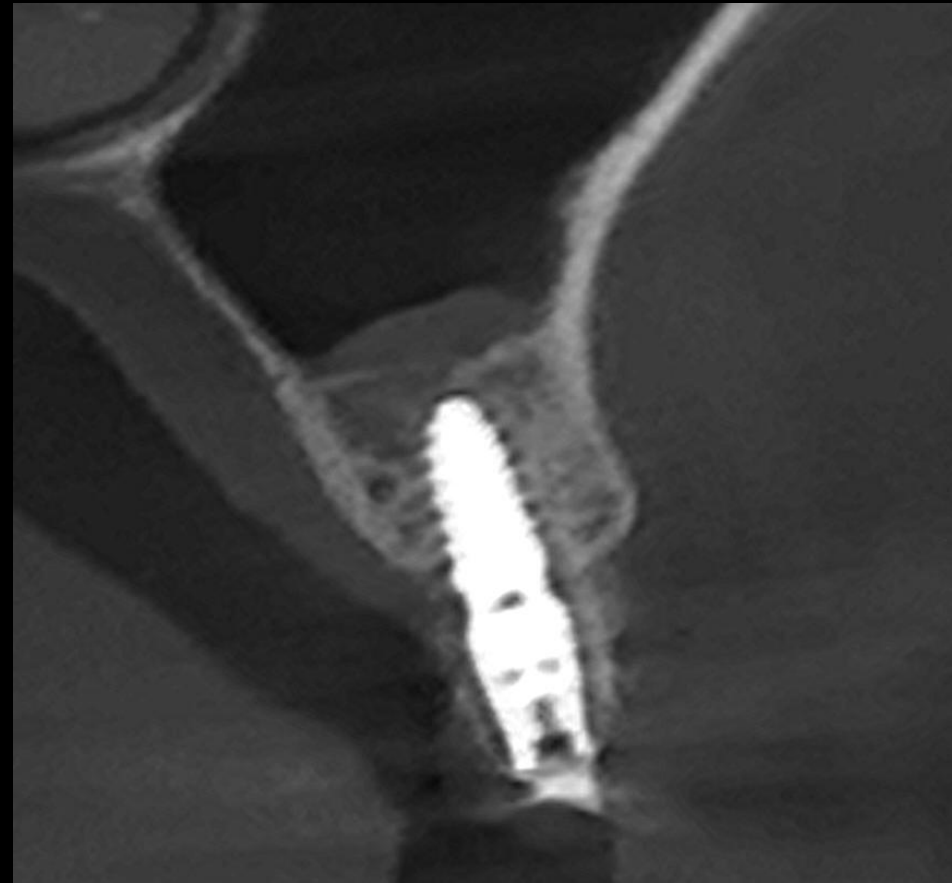
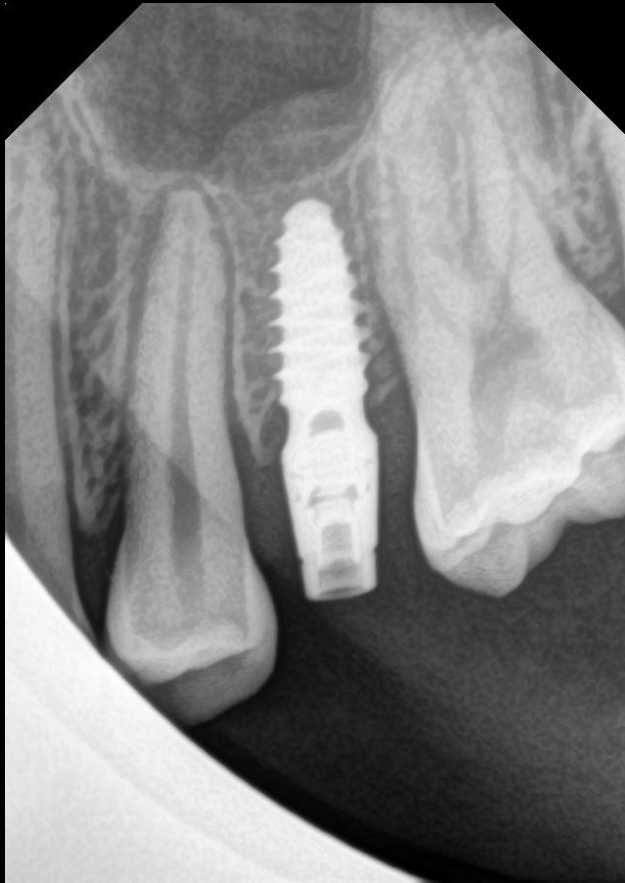Crestal approach for Sinus lifting using Collagen Graft 2



Provisional restoration

Similar case 1

Crestal approach for Sinus lifting using Collagen Graft 2



Healing : 7 months
PA / CT

