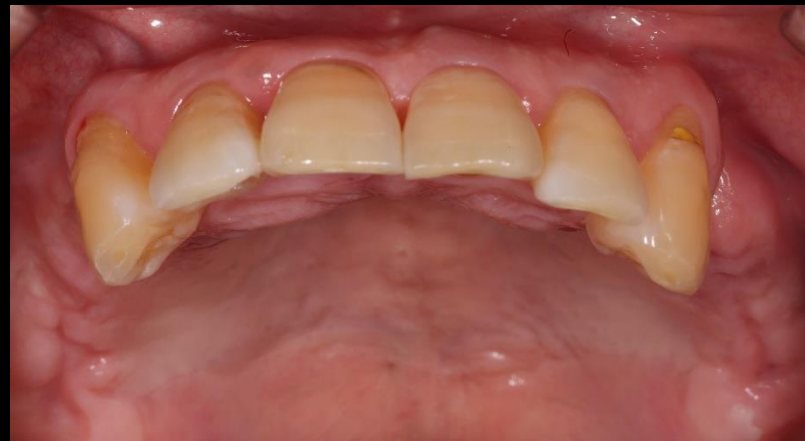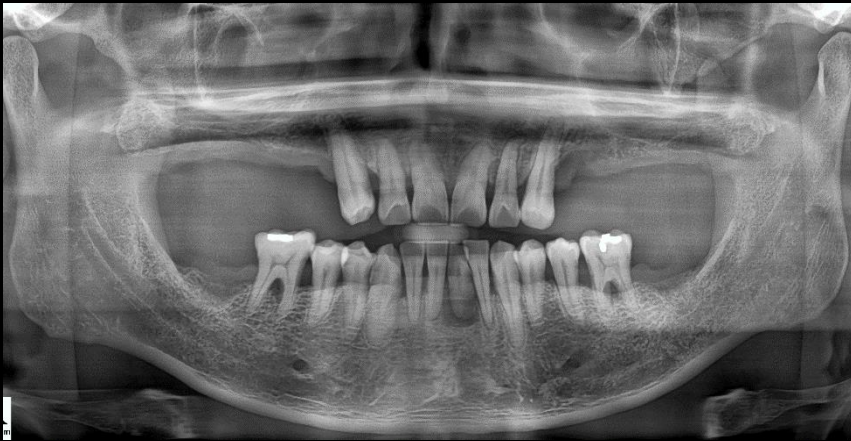


LIVE & Follow up

Bilateral Sinus approach with DASK simple



Dr. SM Chung
2022.12.02 (Fri)

Patient Information

Age :43

Sex : Male

Chief Complaint

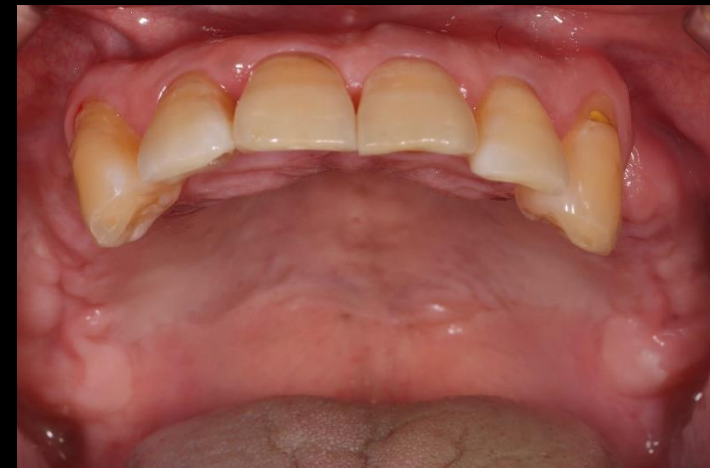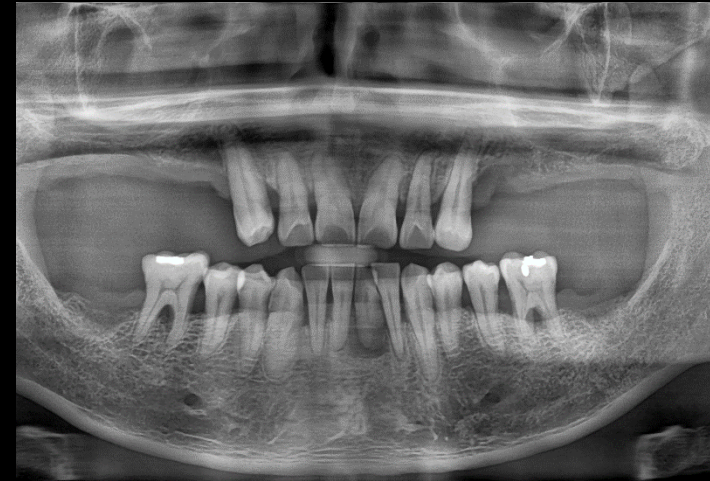
: I want fixed prosthesis

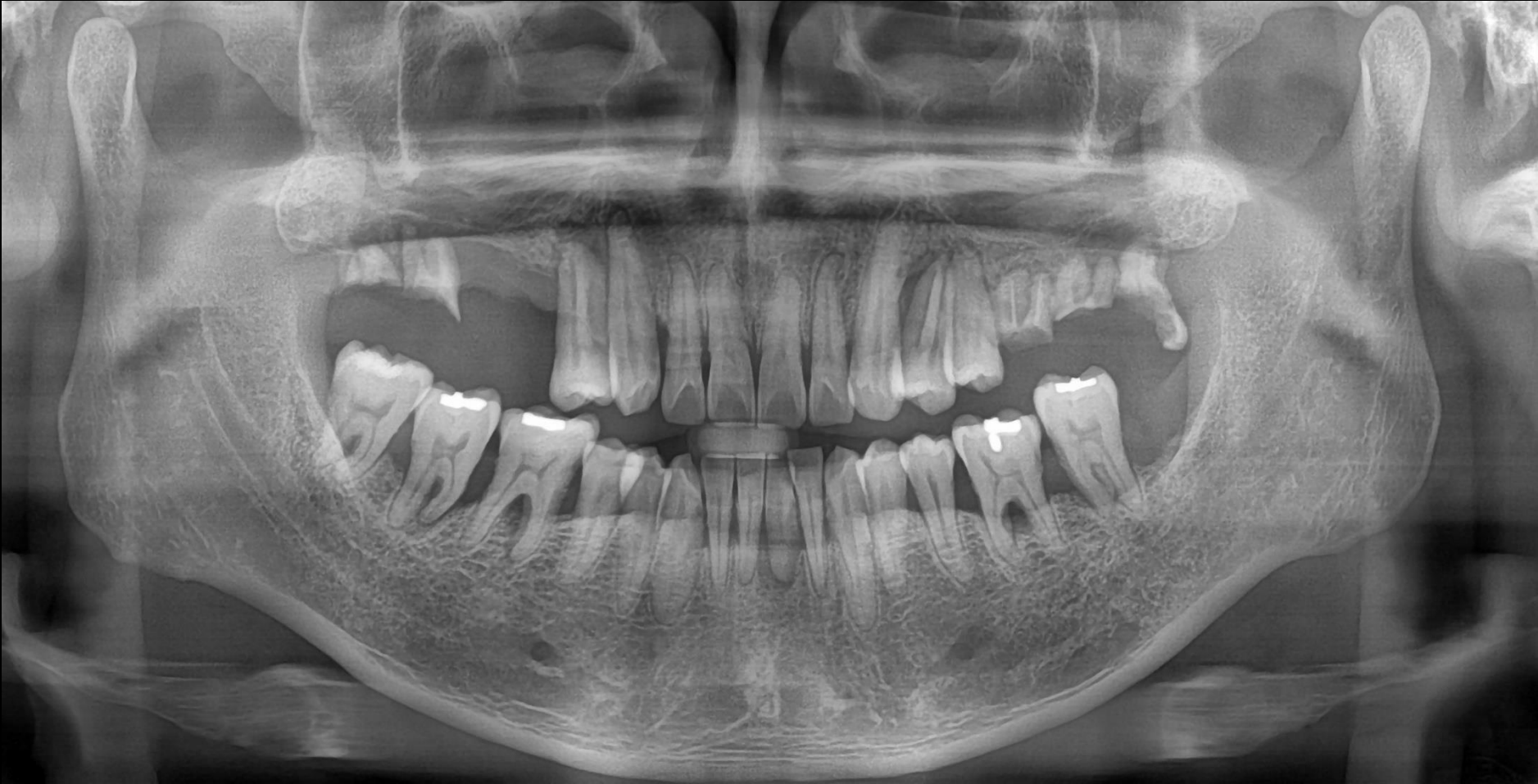Past Dental History

: root rest removal and extraction on Maxillary molar

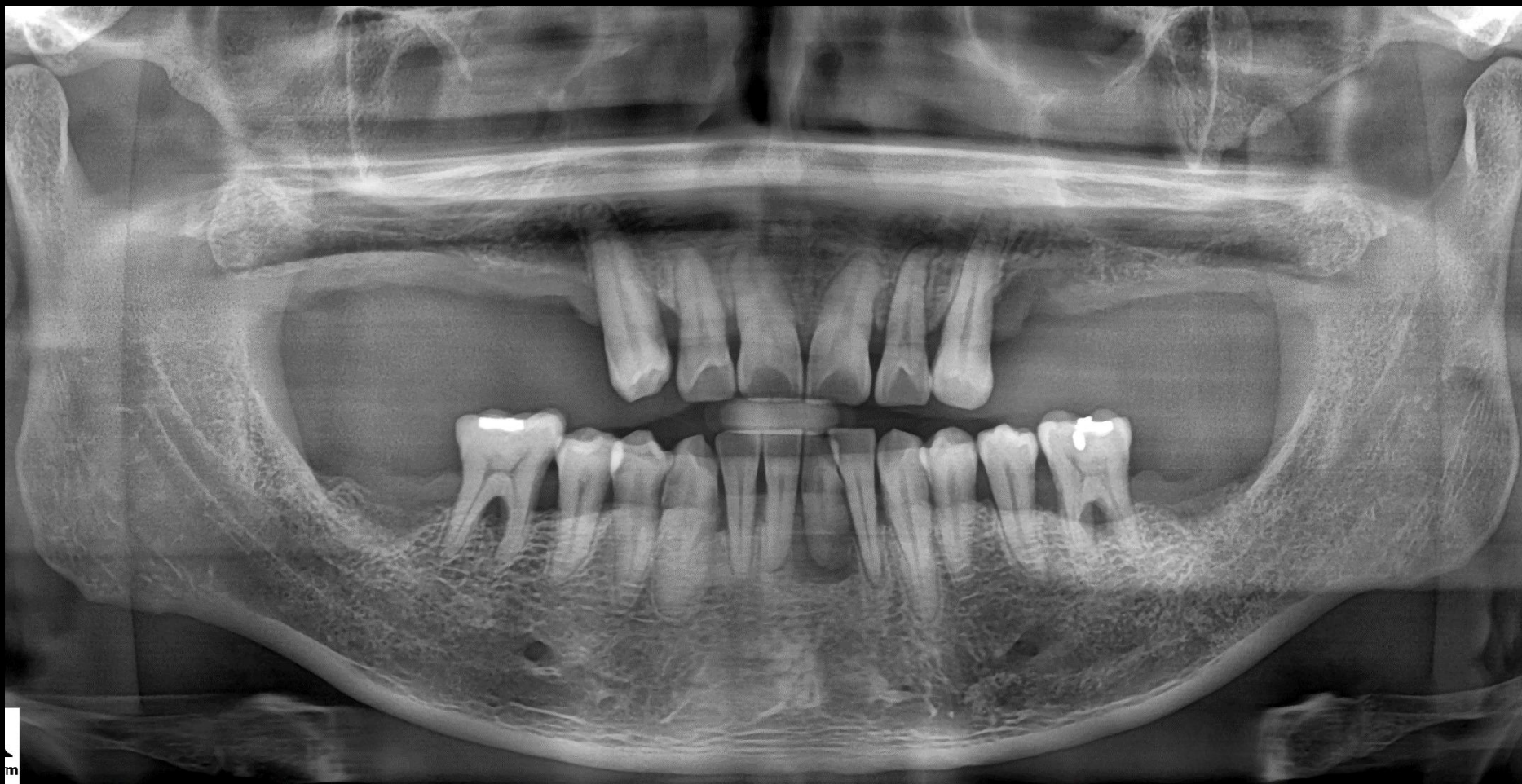Past Medical History

: diabetes mellitus

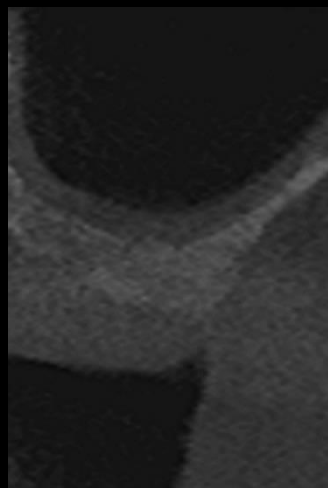




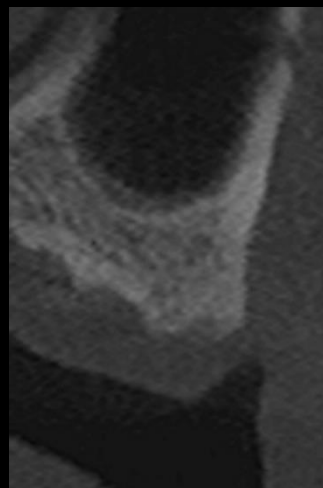
Pre-op



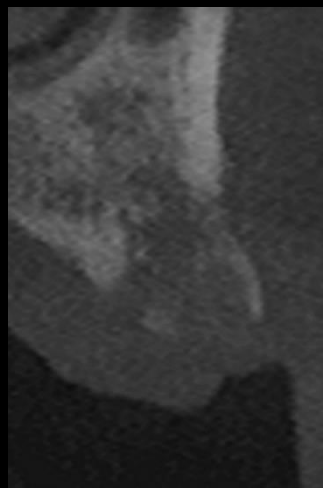
3



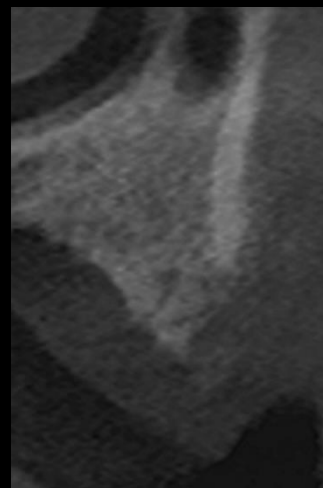
#17



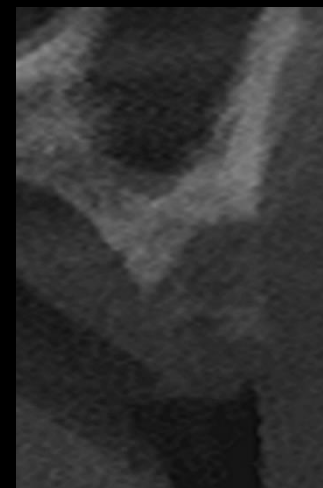#15



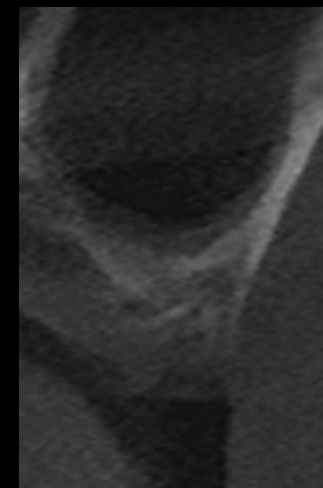#14



#24

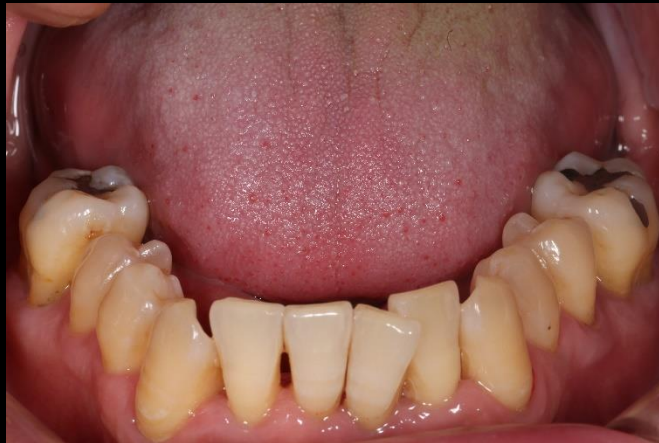
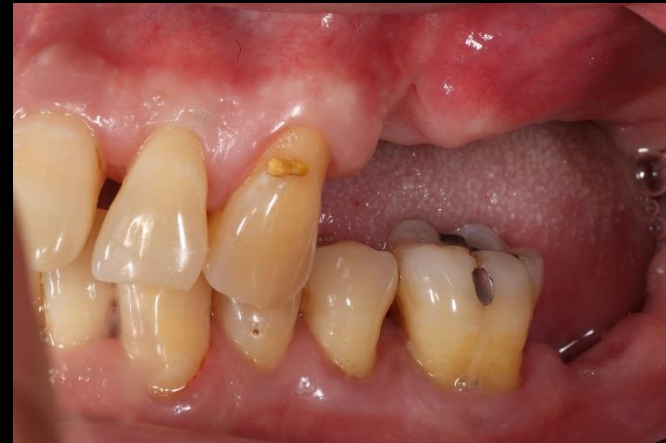
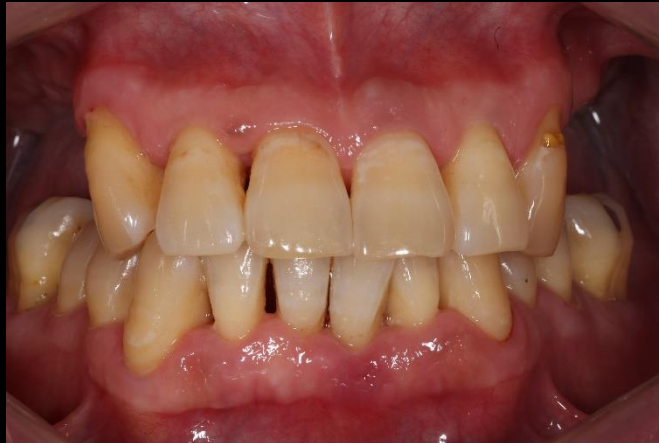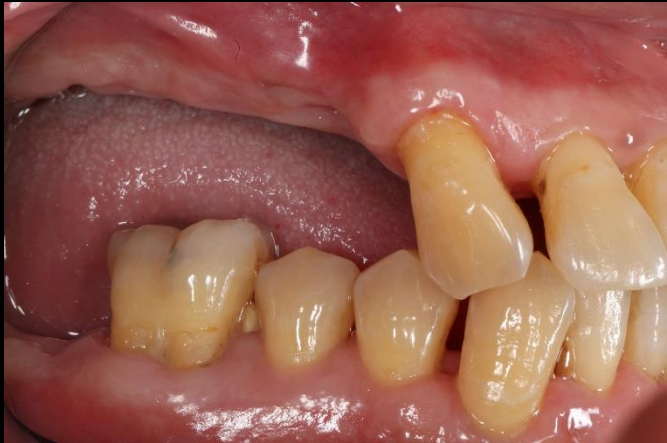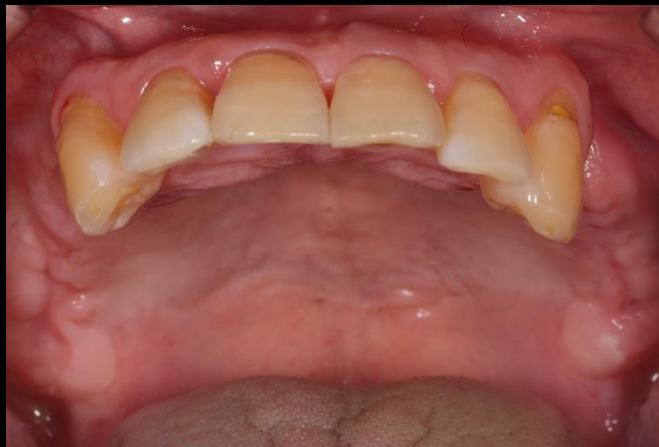#25

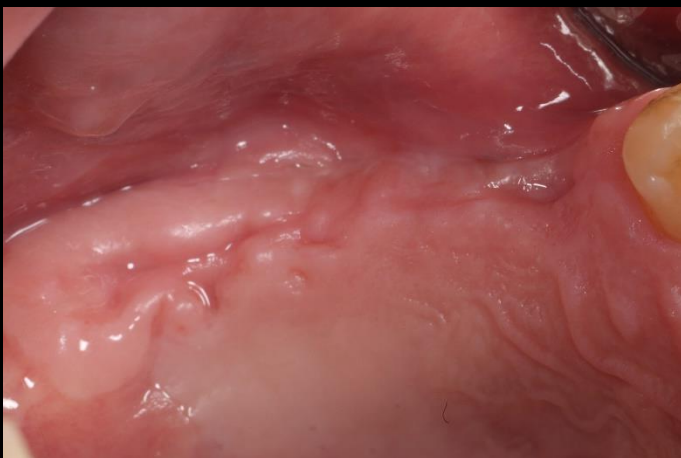
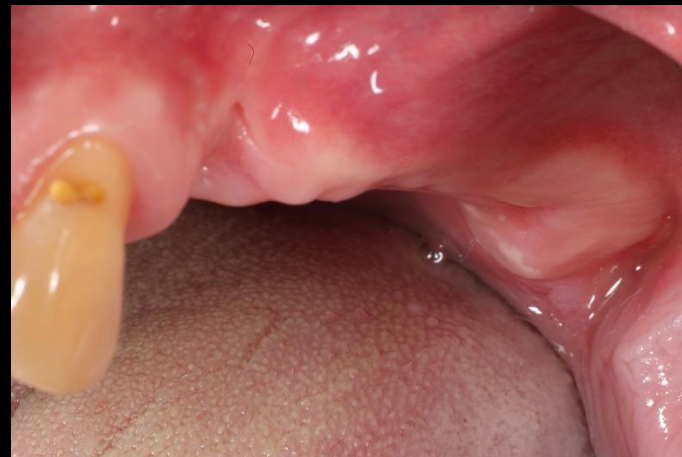
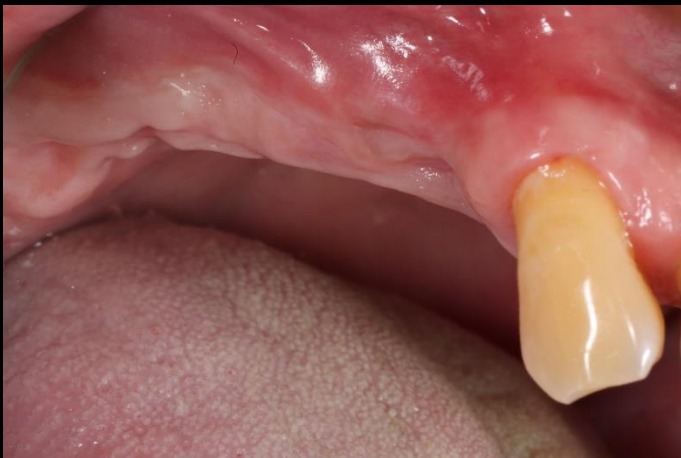#26

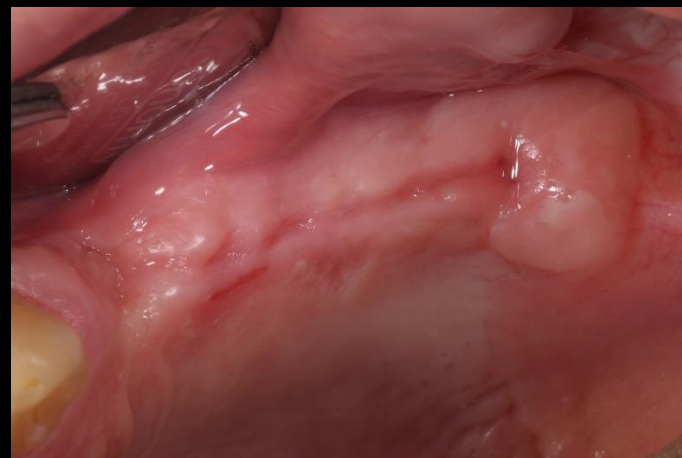Pre-op



Pre-op

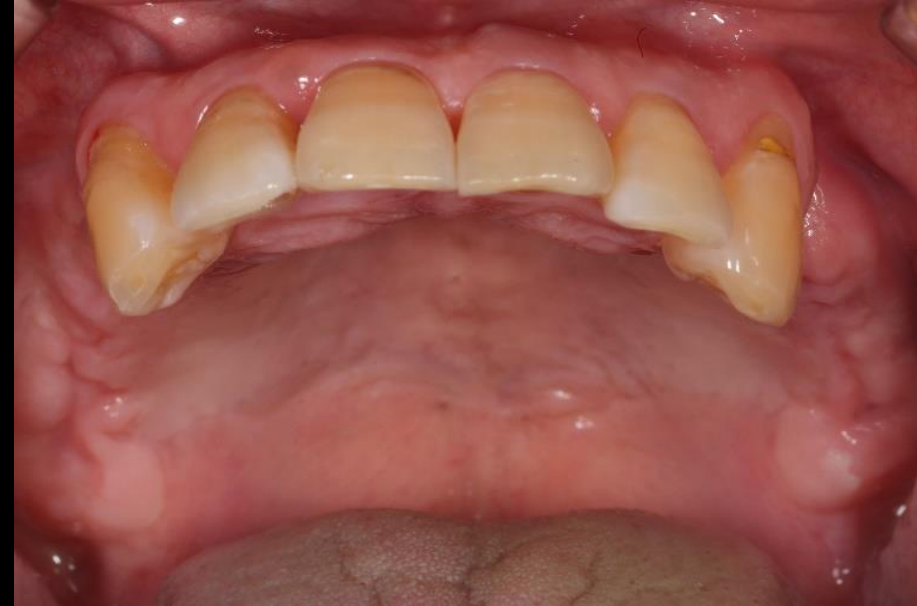
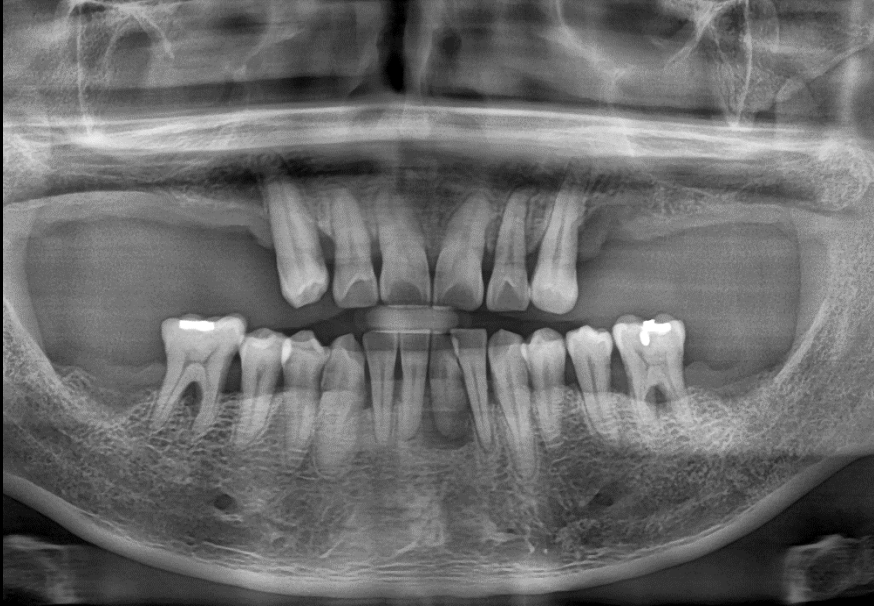
#10



#20

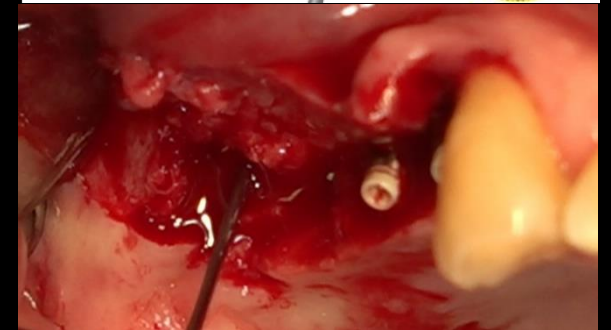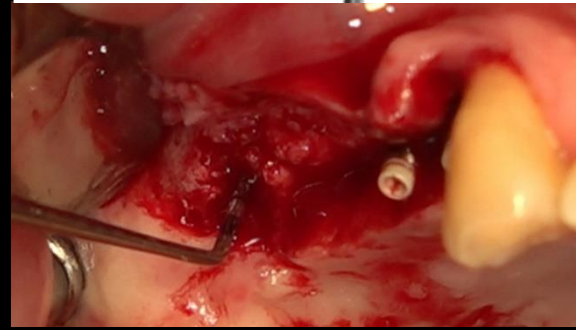
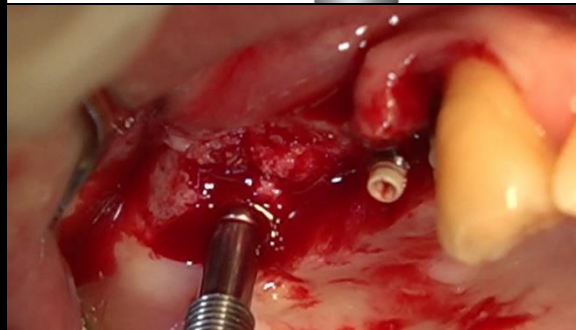
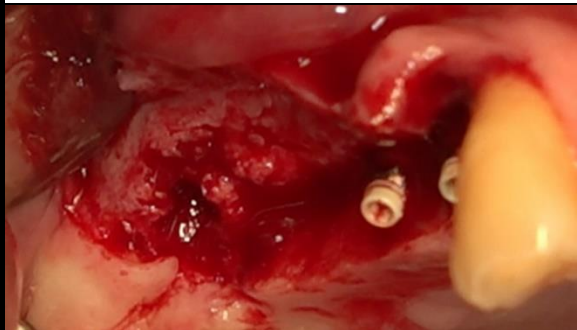
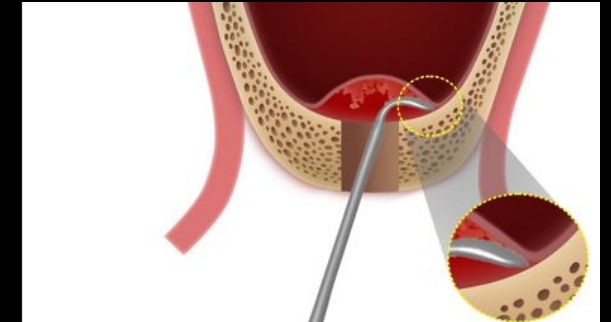
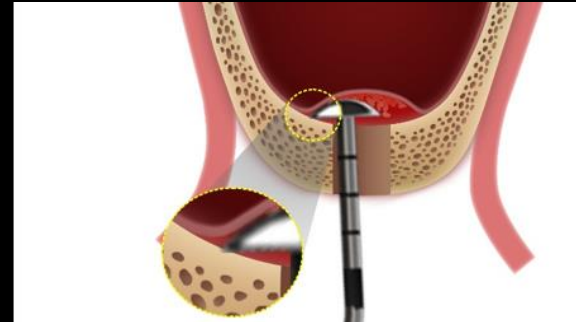
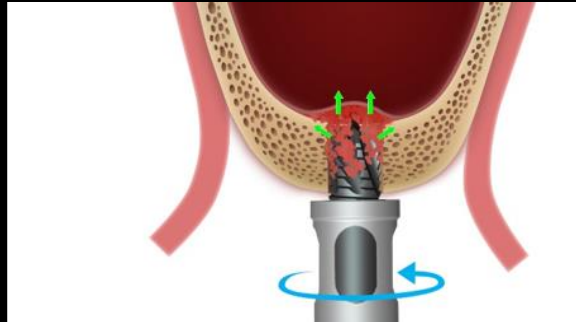
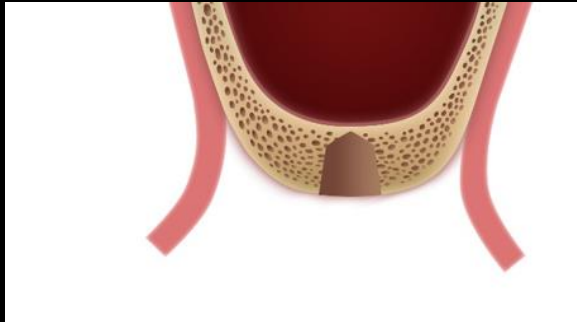

Surgery Plan (#14,15,17,24,25,26)



- Implantation on #14,15,17,24,25,26 using **bright implant**
- Both Sinus augmentation using **DASK simple** with **Osteon™ 3 Collagen**

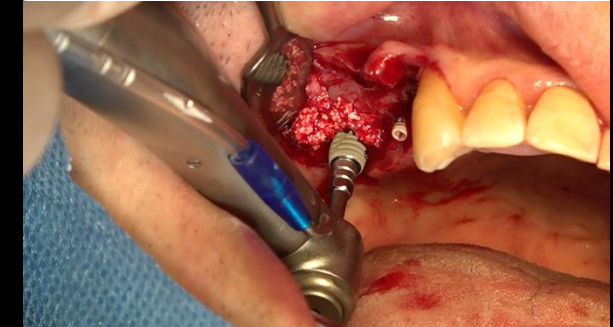
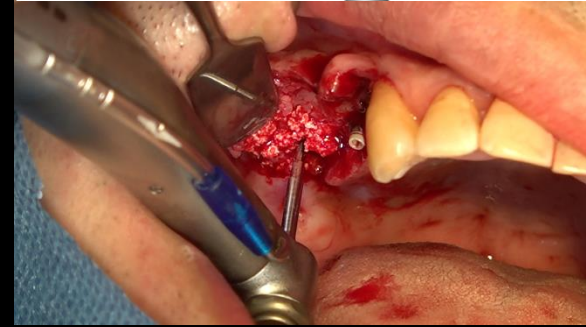
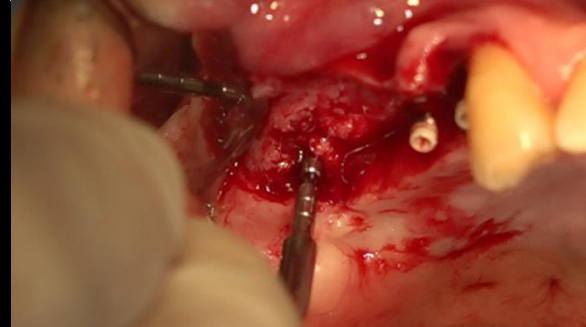
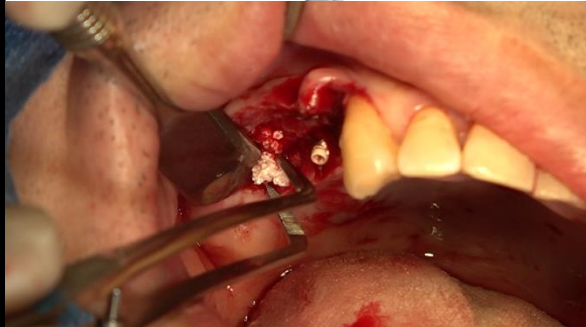
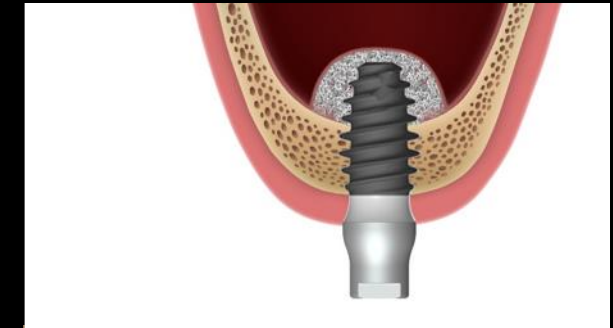
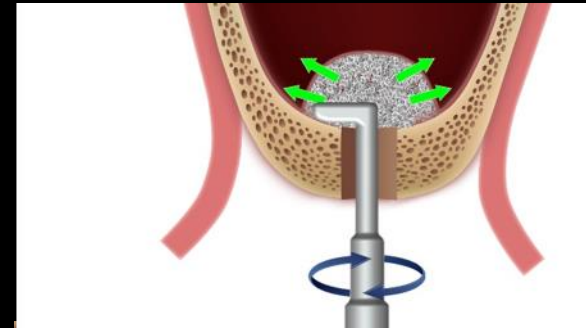
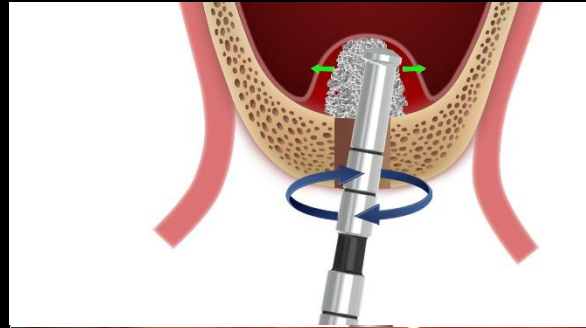
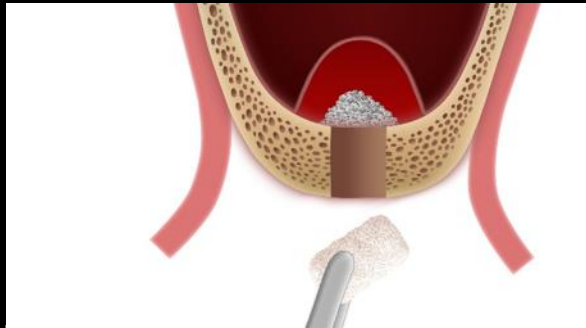
Dentium

Sinus Kit : DASK Simple




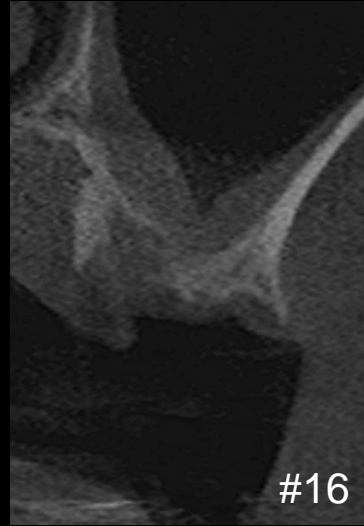
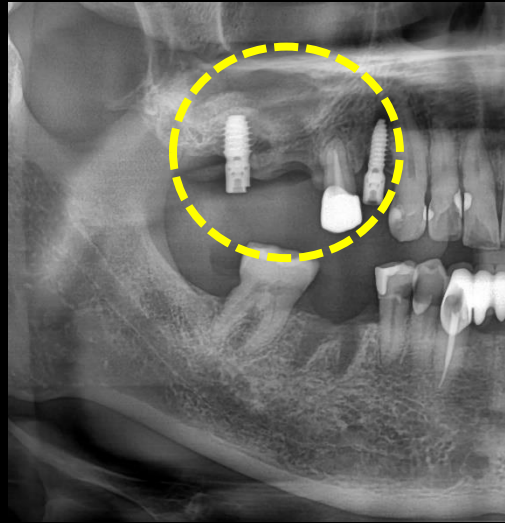
Dentium

Sinus Kit : DASK Simple



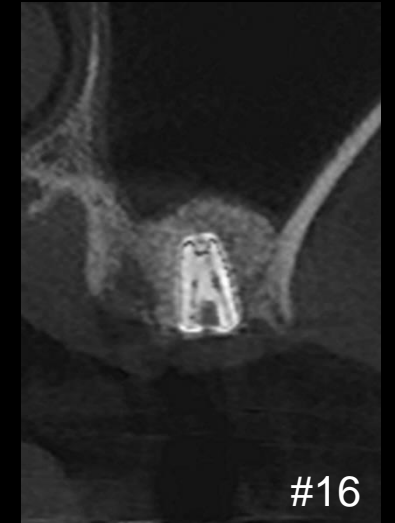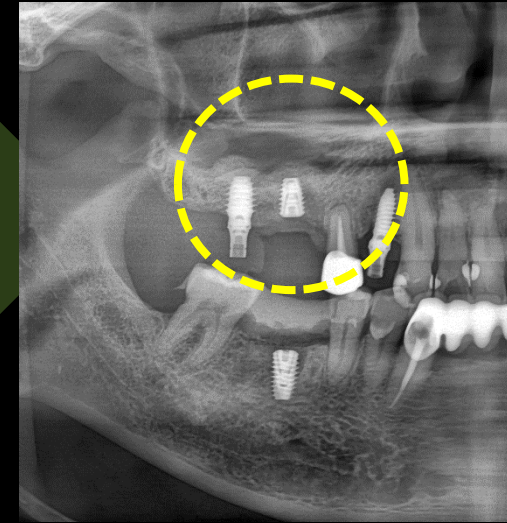
Dentium

Sinus Kit : DASK Simple



Sinus lifting
Using **Crestal drill** &
Graft spreader

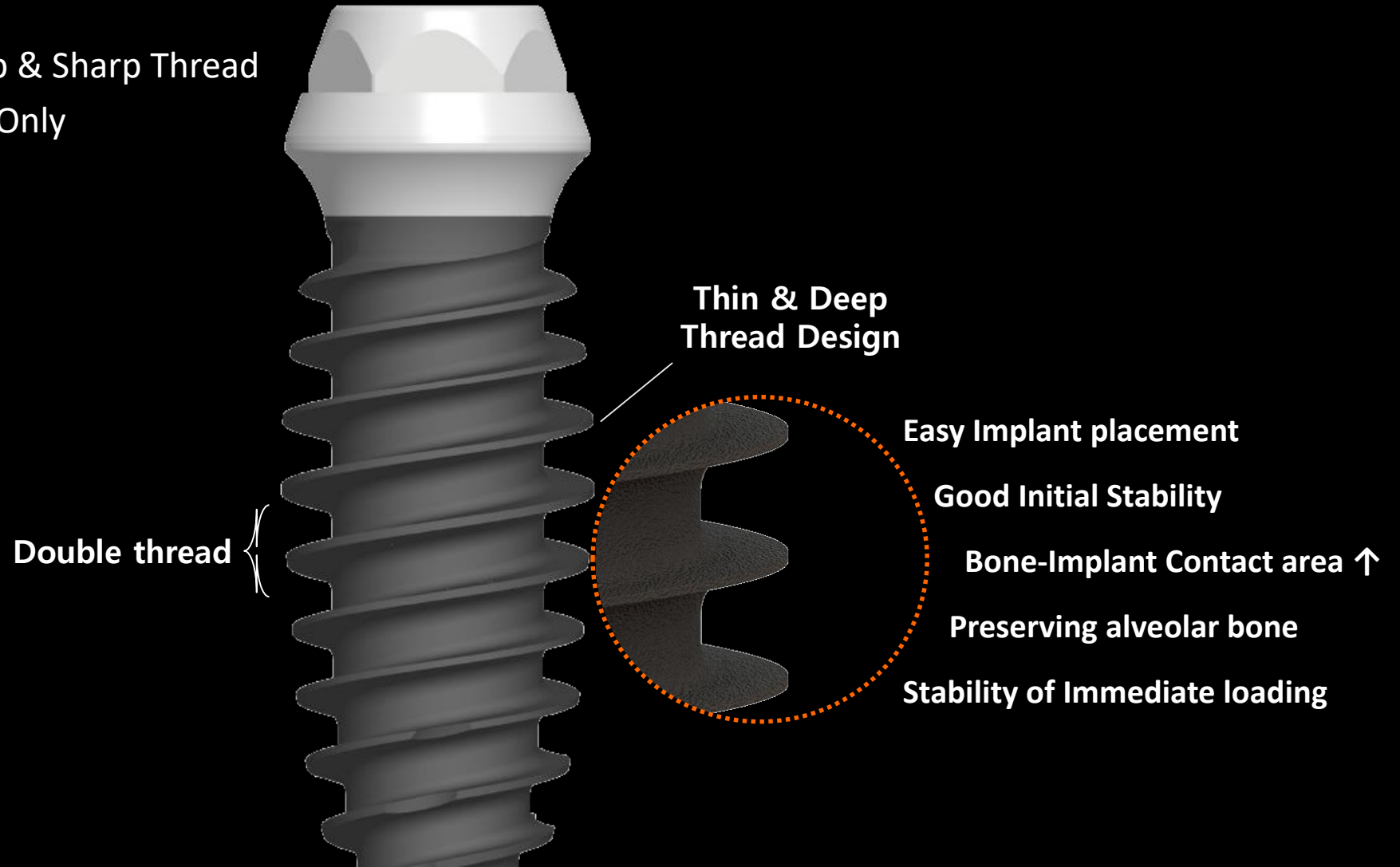
(DASK simple)



bright Tissue Level

For **Simplify Surgical Procedure**

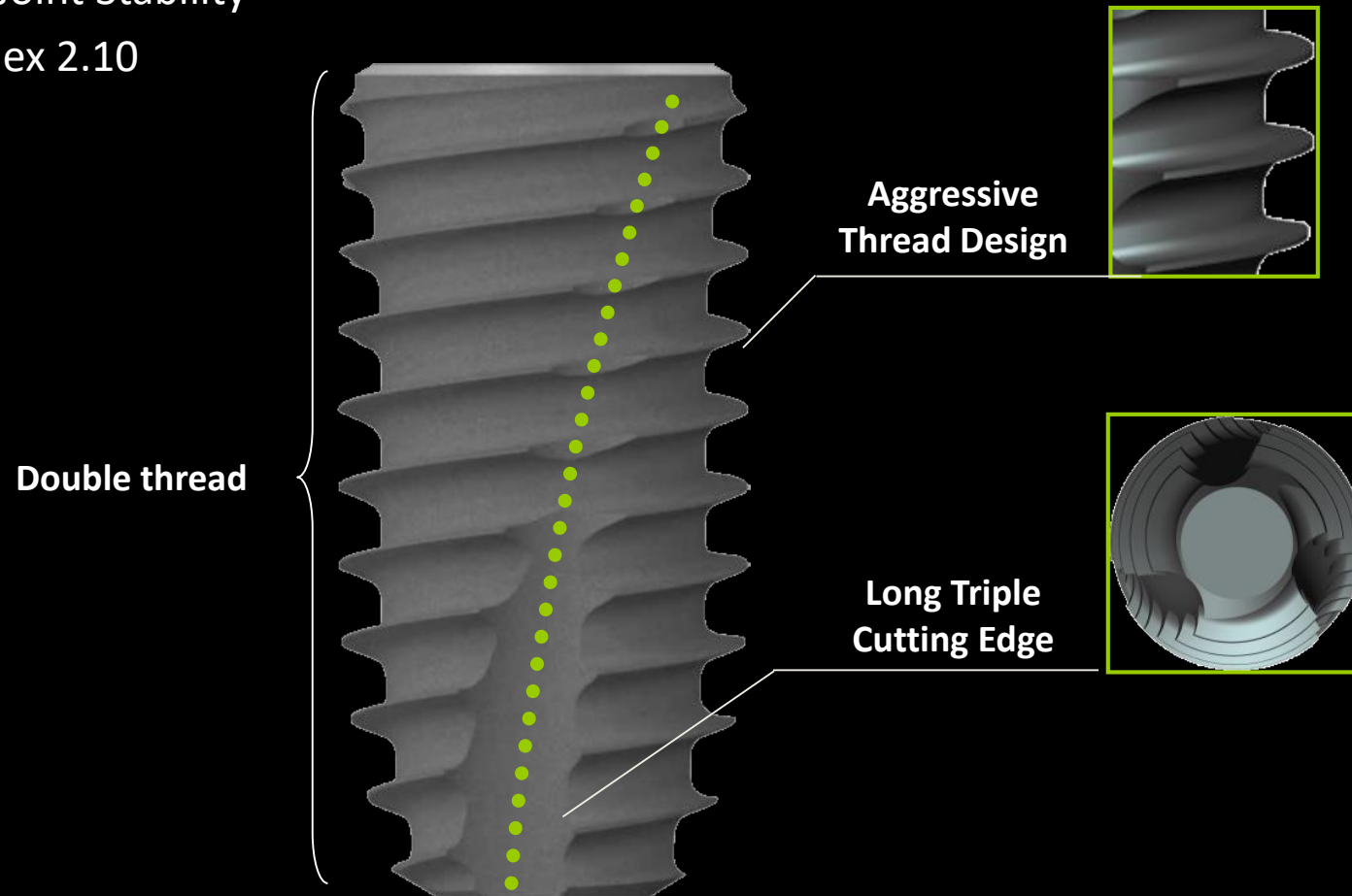
- Thin, Deep & Sharp Thread
- Final Drill Only



bright Bone Level

10° , 3.70 mm Deep Connection

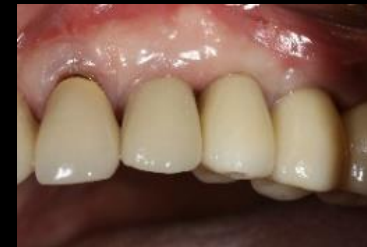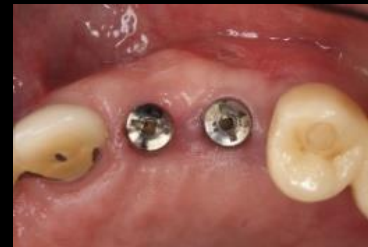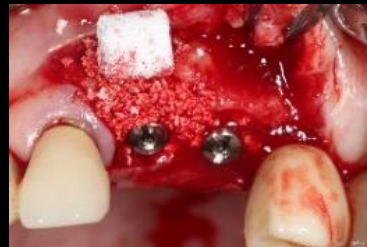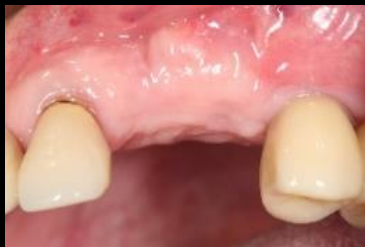- Excellent Joint Stability
- Internal Hex 2.10



OSTEON™ 3 Collagen

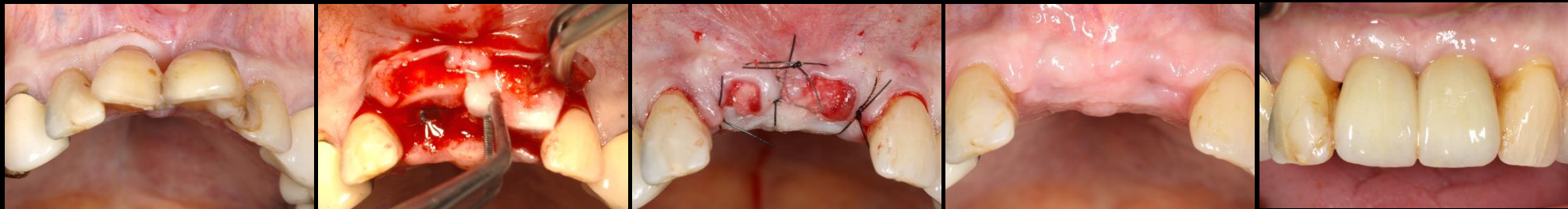OSTEON™ 3 hybridized with pure Type I collagen

- Moldable to various defect shapes during wetting
- Easy handling to reduce chair time
- Collagen is absorbed within a few weeks after grafting



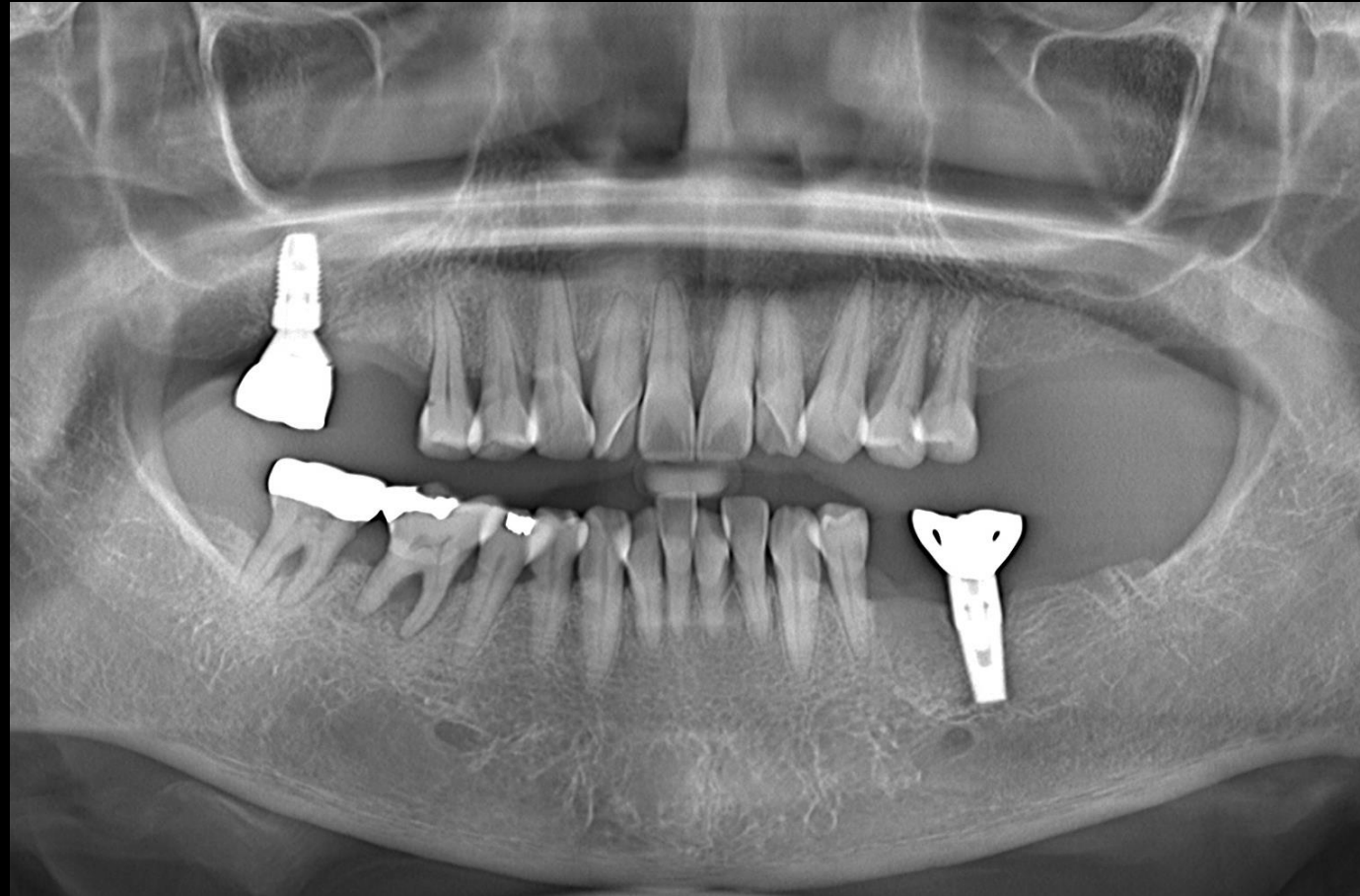
Collagen Graft 2

- Ridge preservation
- Porcine tendon derived type I collagen
- Faster soft tissue healing by epithelization



Similar case 1

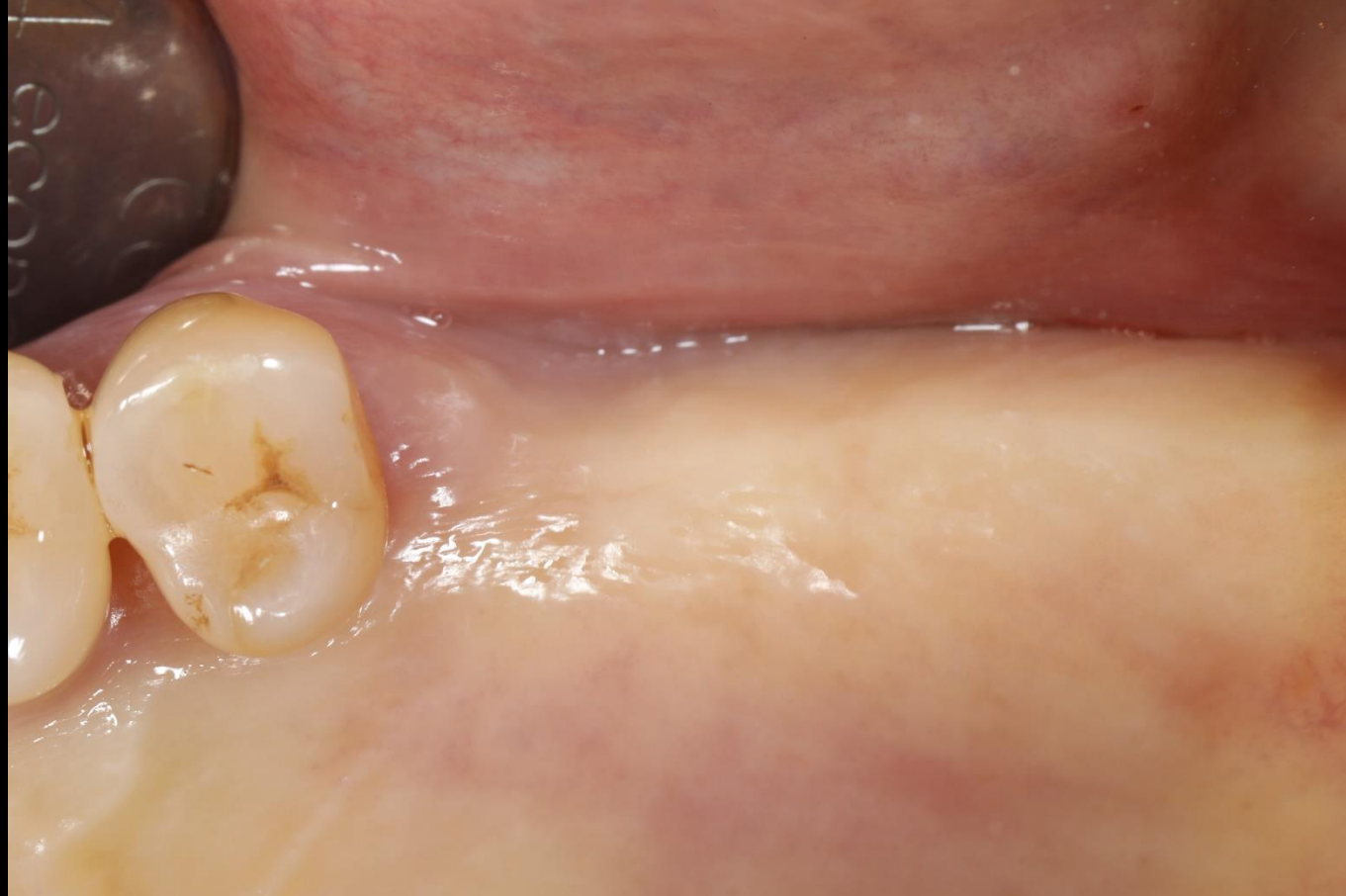Overcoming Sinus Perforation



Pre-op

Similar case 1

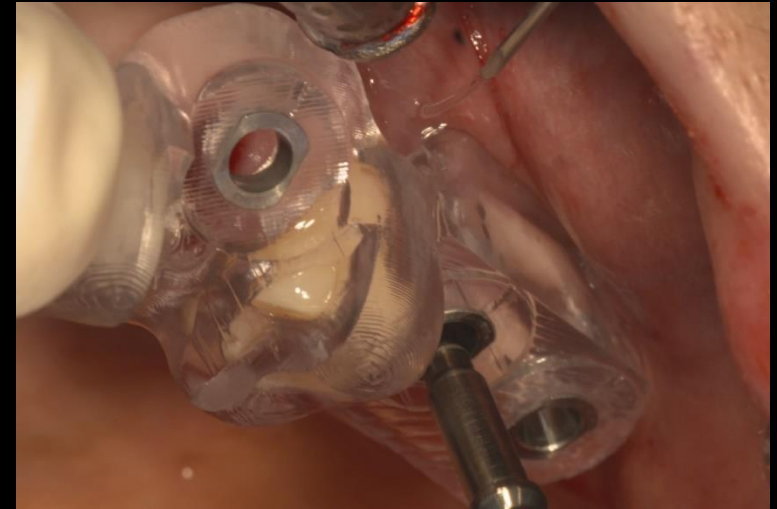
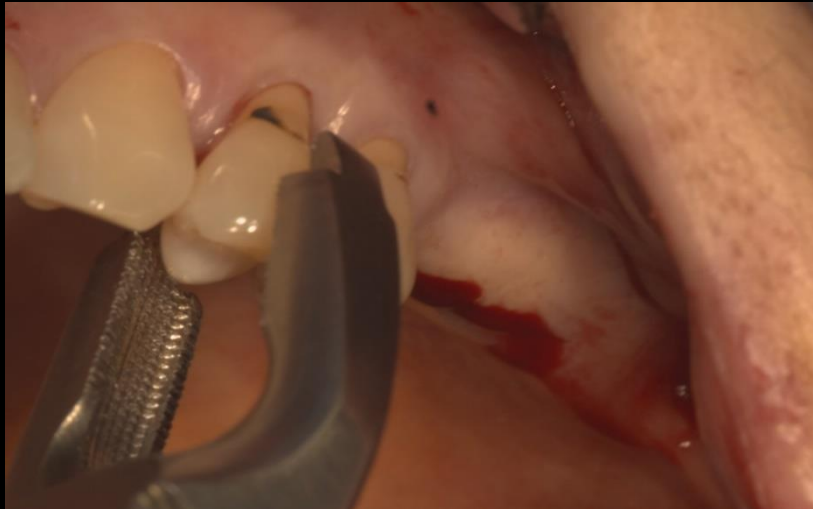
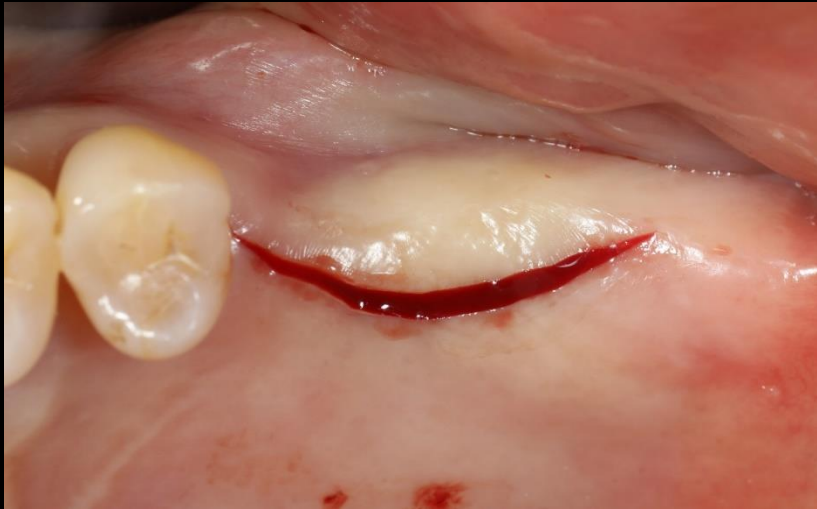Overcoming Sinus Perforation



Pre-op

Similar case 1

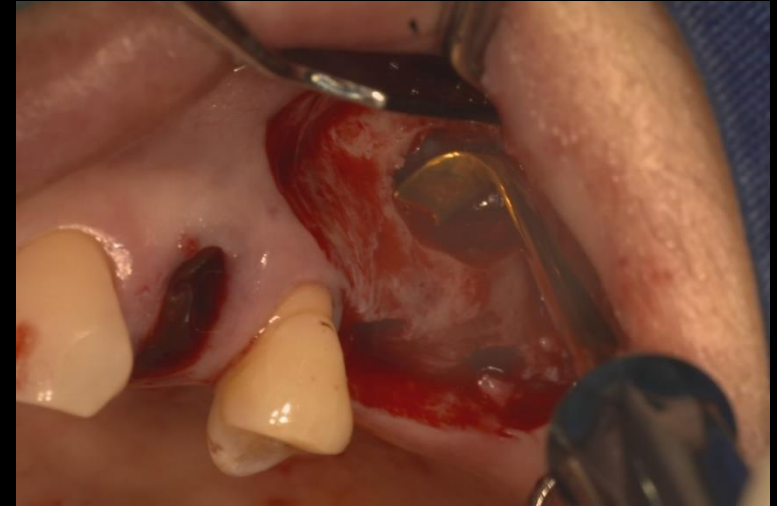
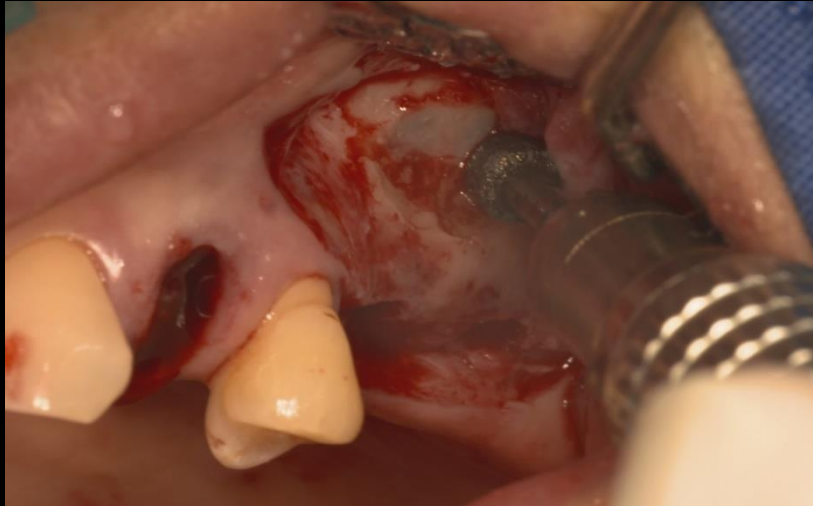
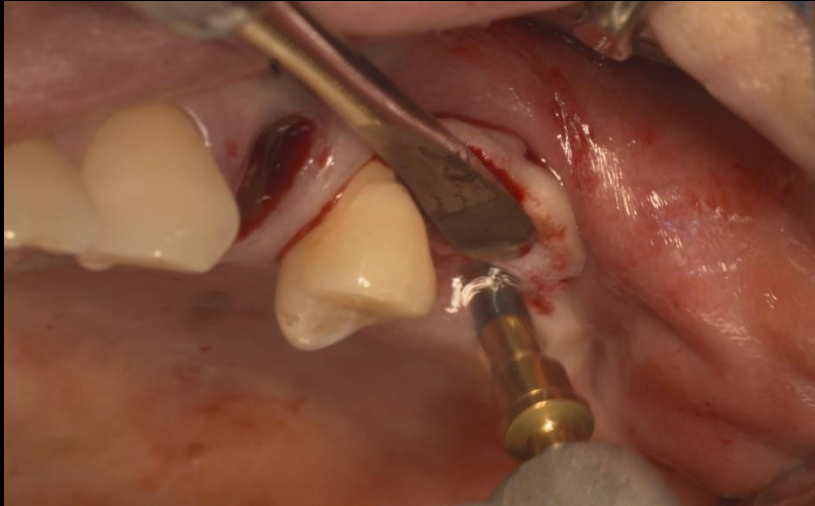
Overcoming Sinus Perforation



Surgery

Similar case 1

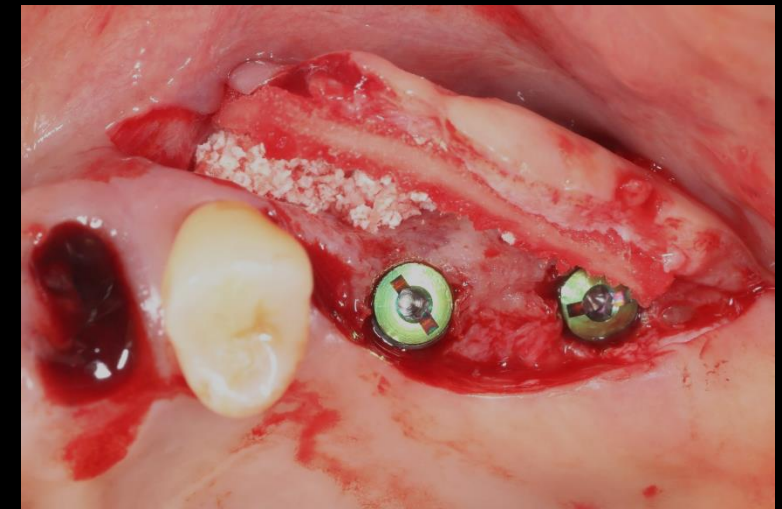
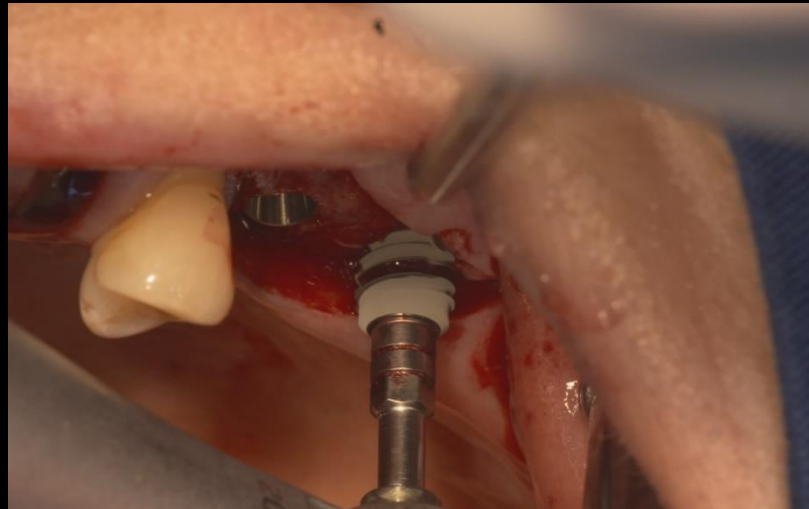
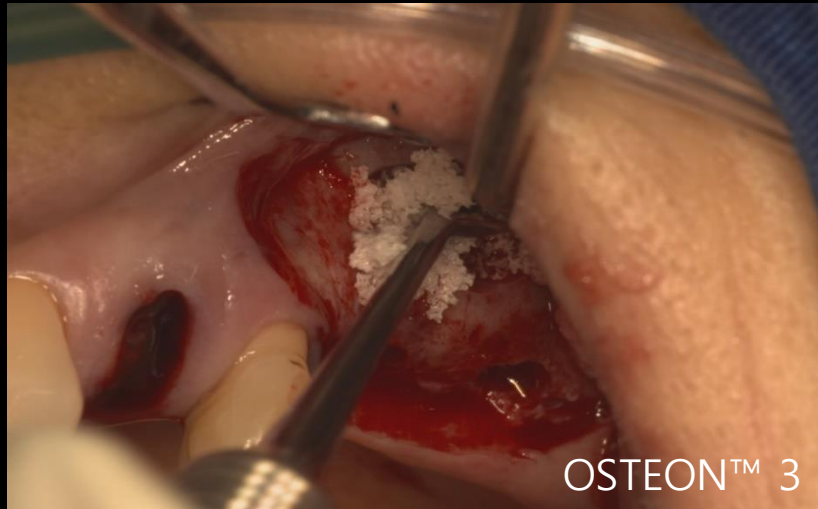
Overcoming Sinus Perforation



Surgery

Similar case 1

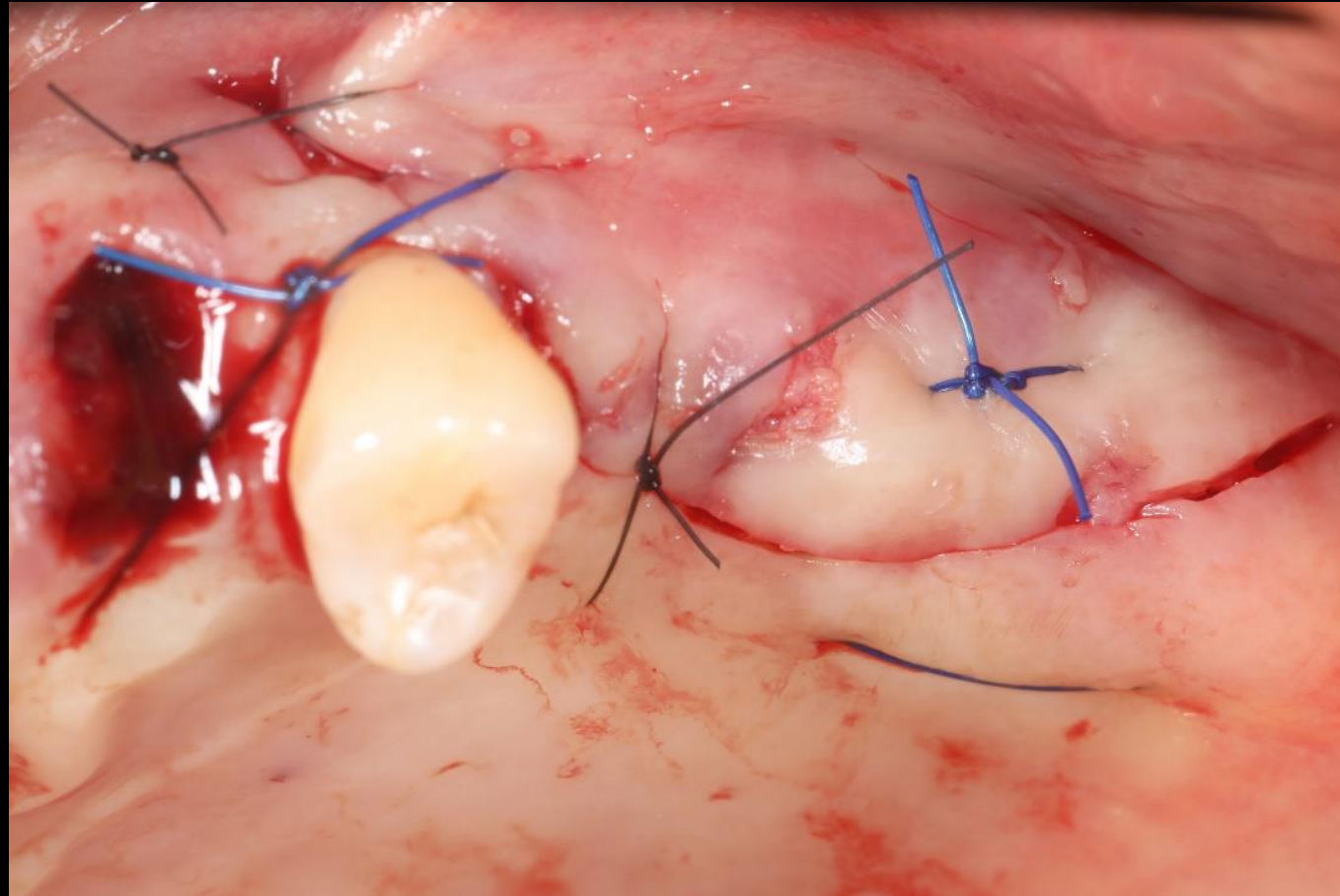
Overcoming Sinus Perforation



Surgery

Similar case 1

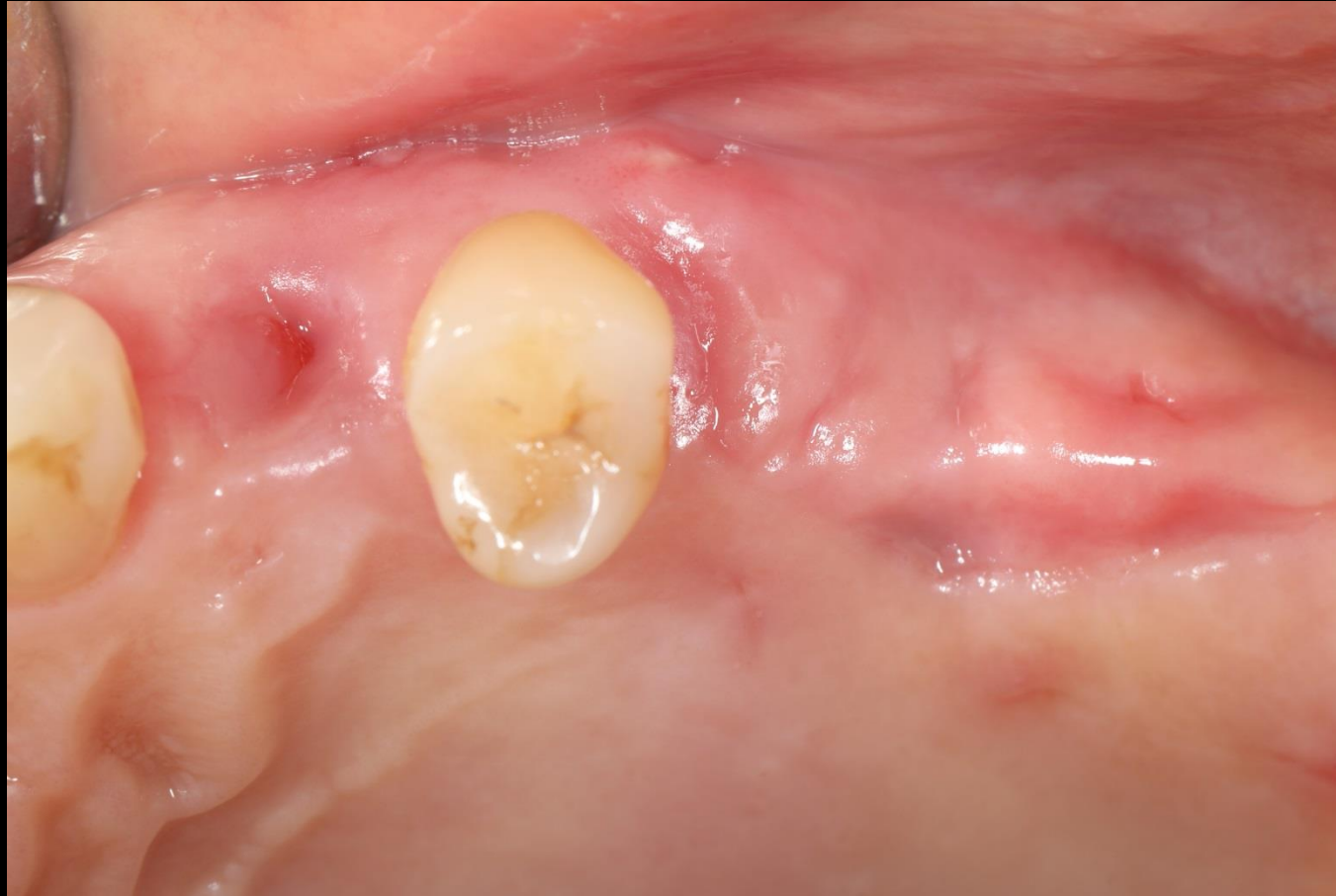
Overcoming Sinus Perforation



Post-op

Similar case 1

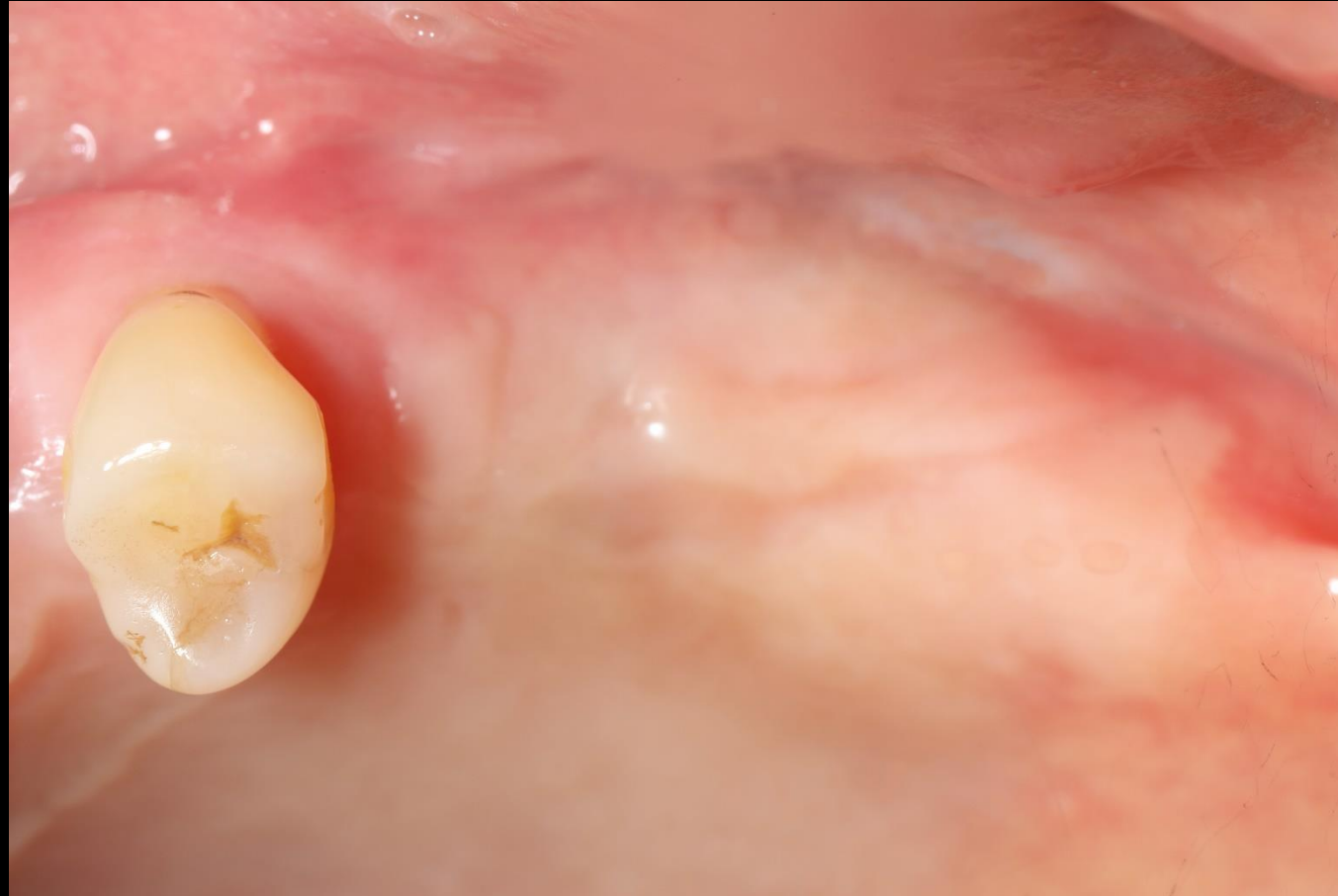Overcoming Sinus Perforation



Healing 3 week

Similar case 1

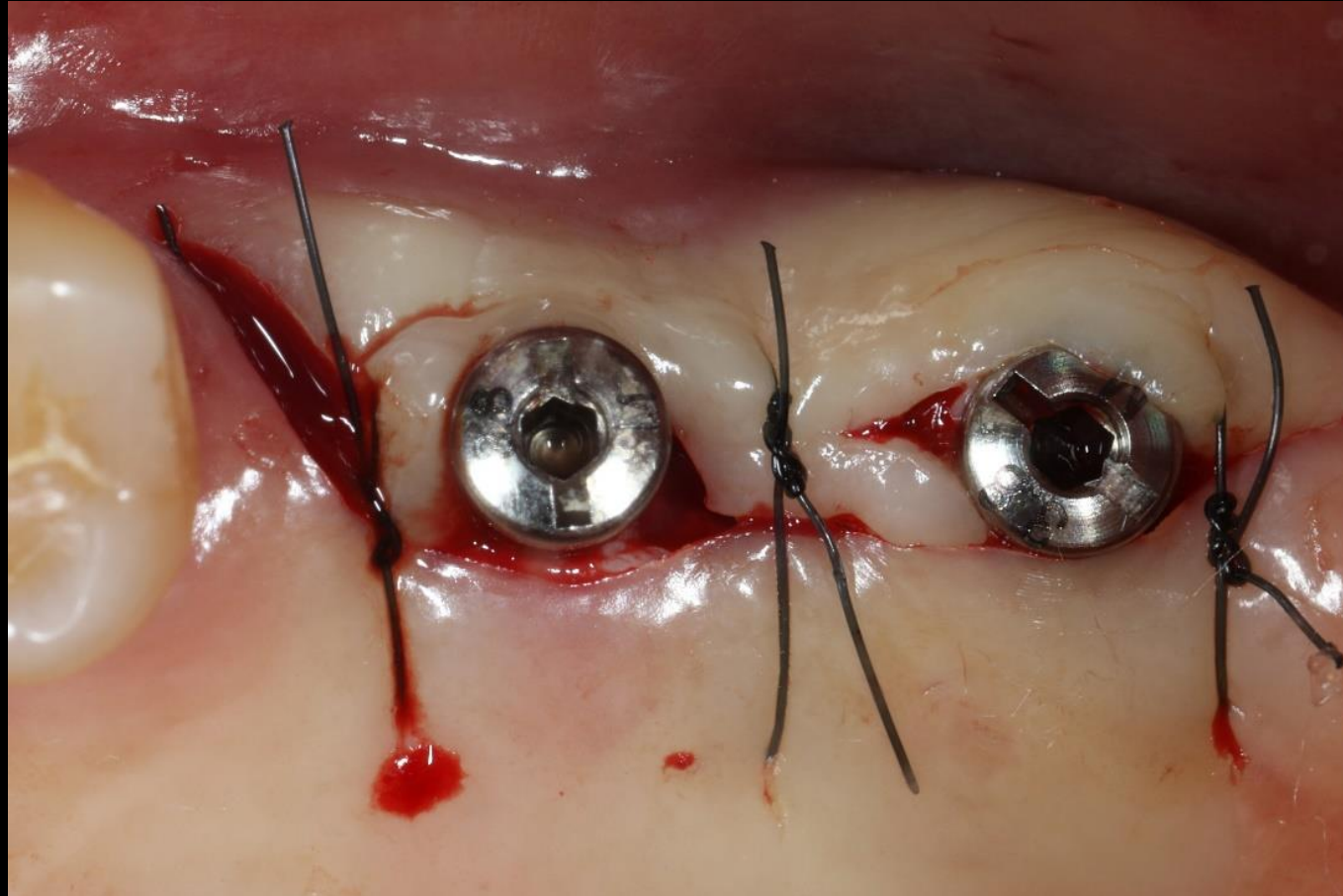
Overcoming Sinus Perforation



Healing 1 month 3 weeks

Similar case 1

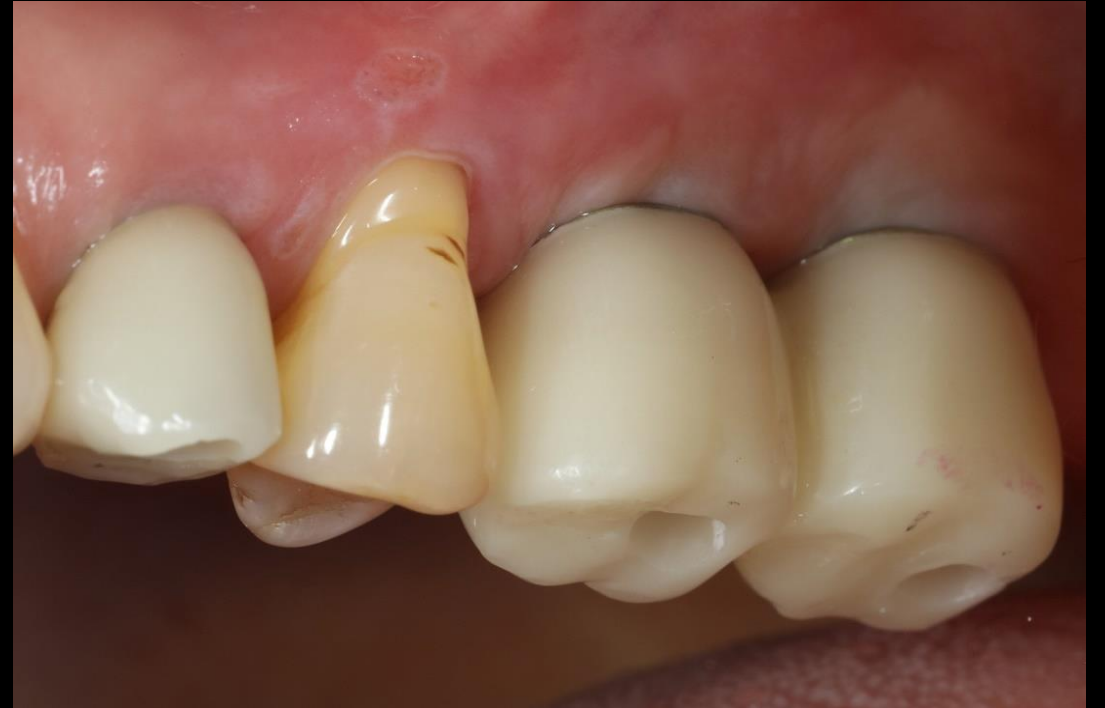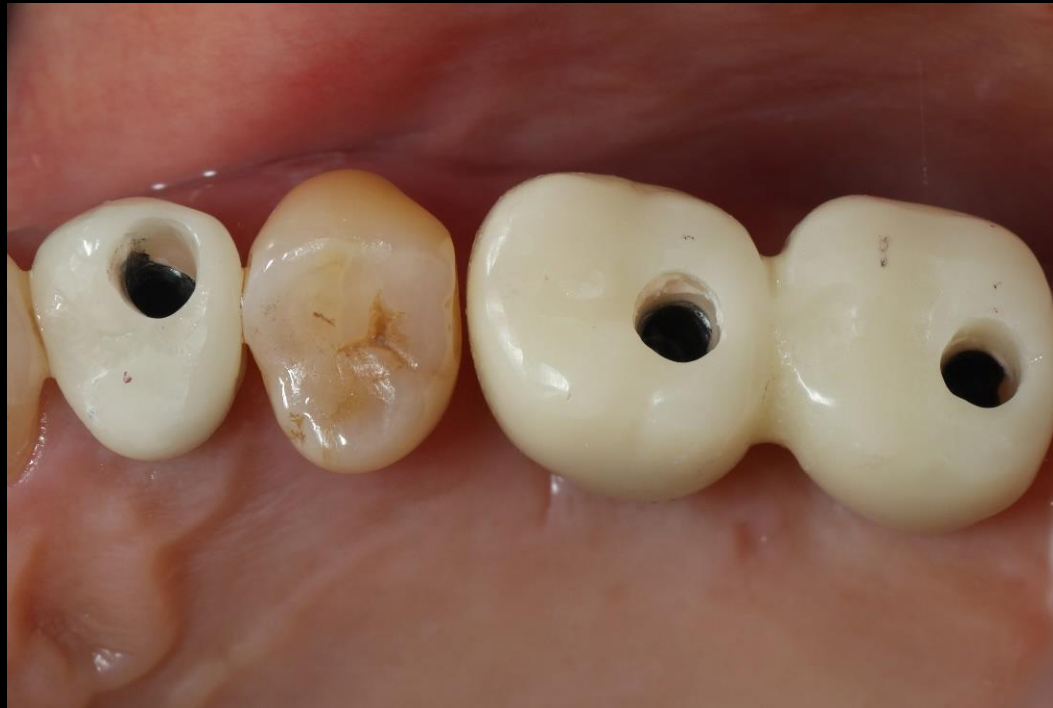Overcoming Sinus Perforation



2nd Surgery

Similar case 1

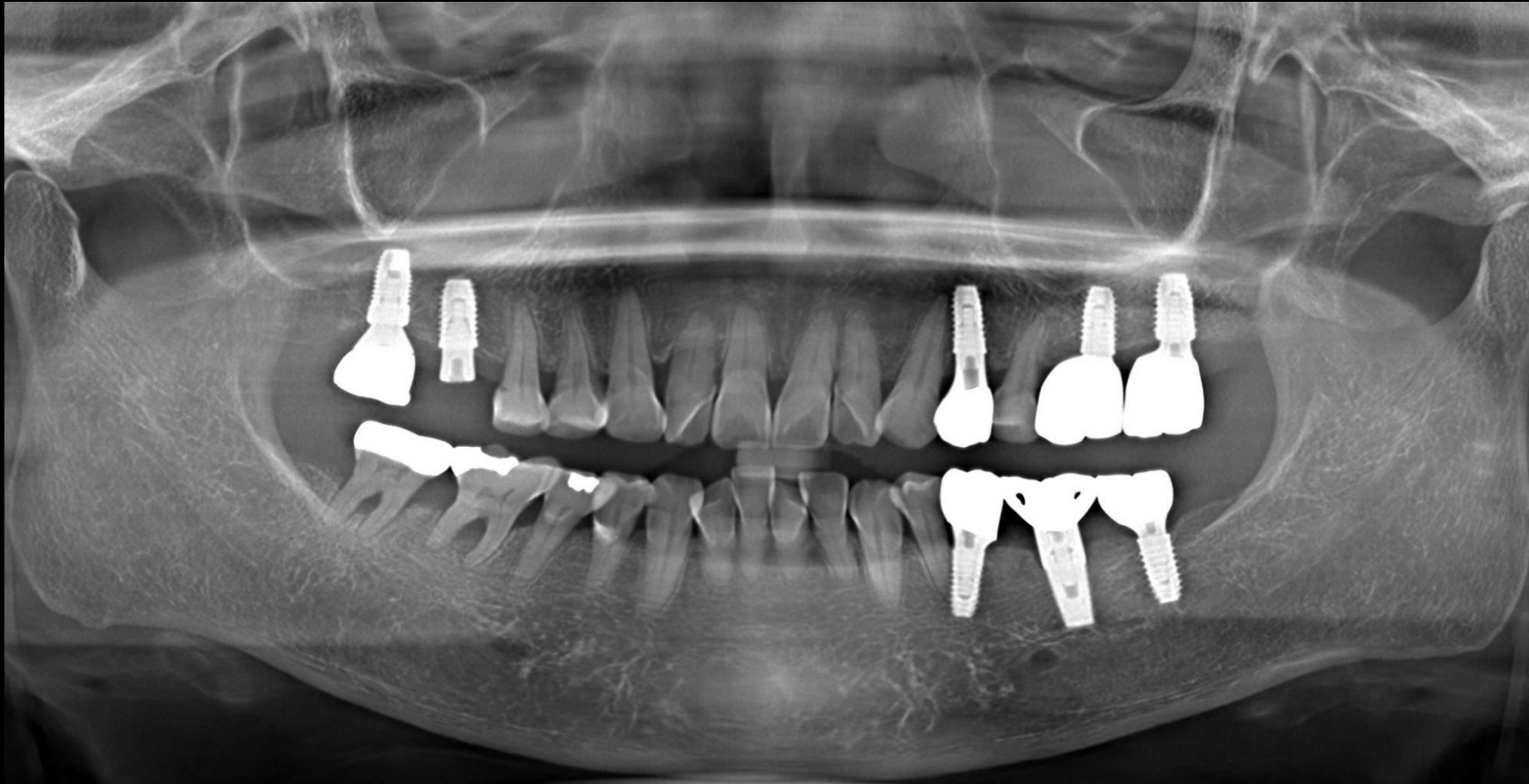Overcoming Sinus Perforation



Provisional restoration

Similar case 1

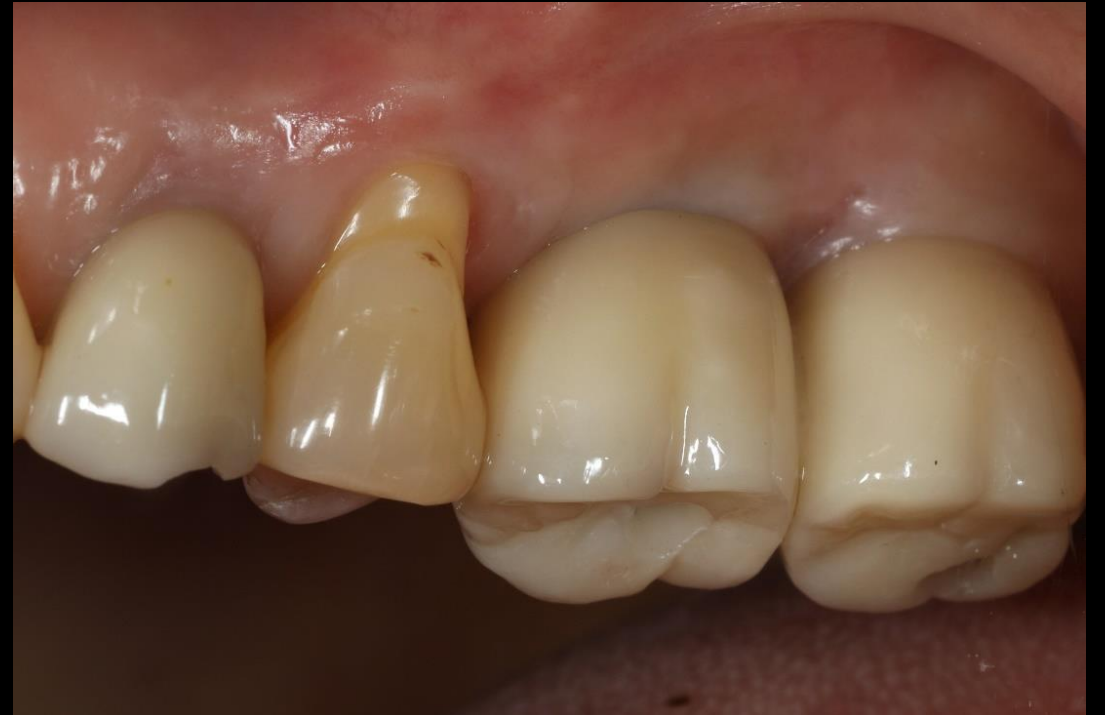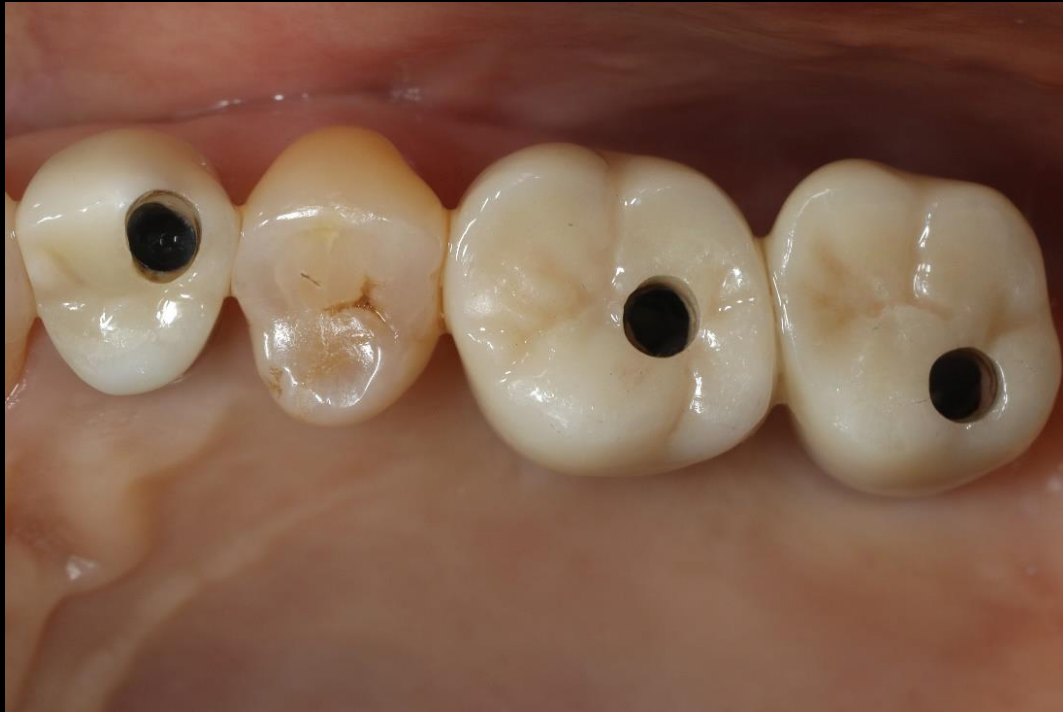Overcoming Sinus Perforation



Final prosthesis

Similar case 1

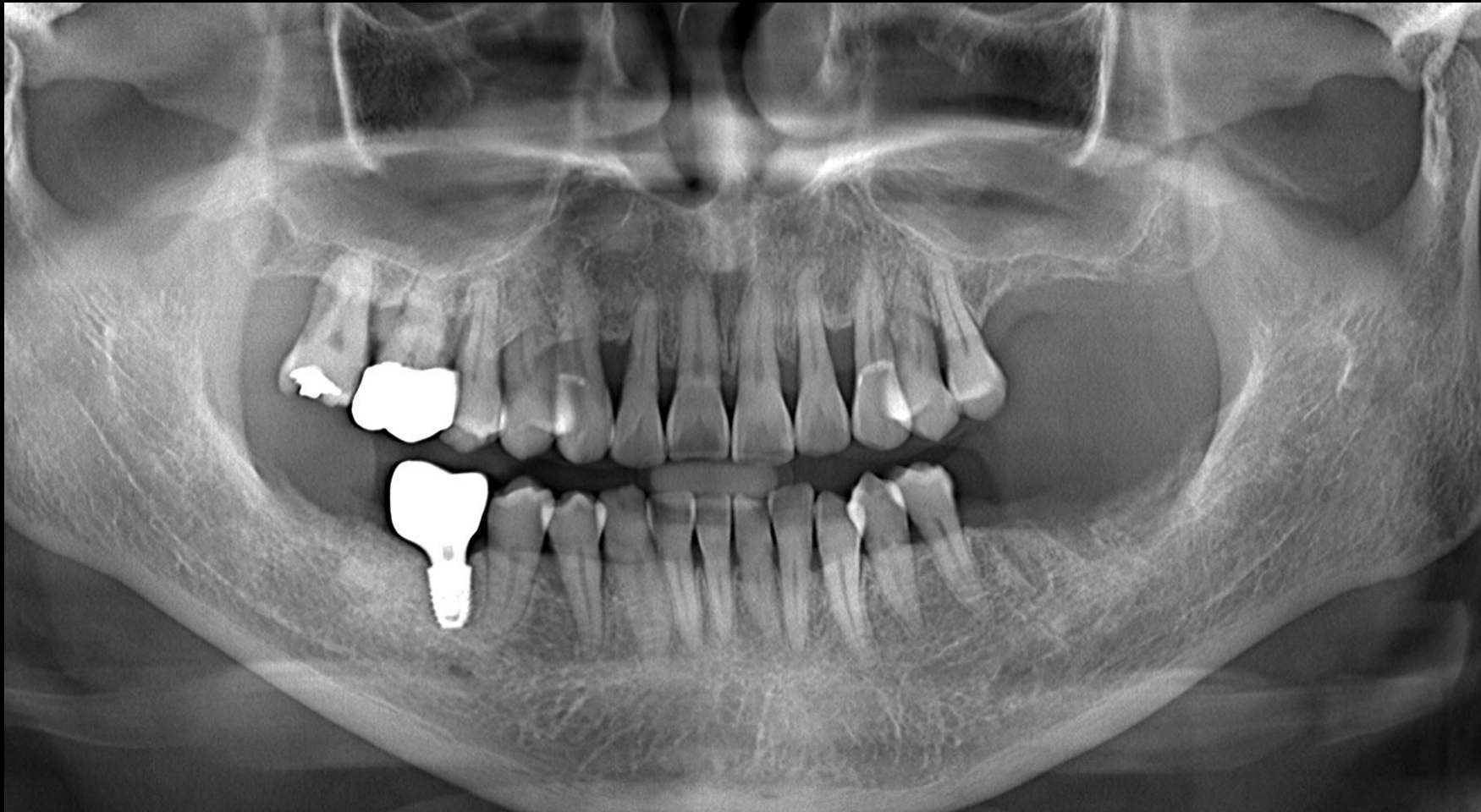
Overcoming Sinus Perforation



Final prosthesis

Similar case 2

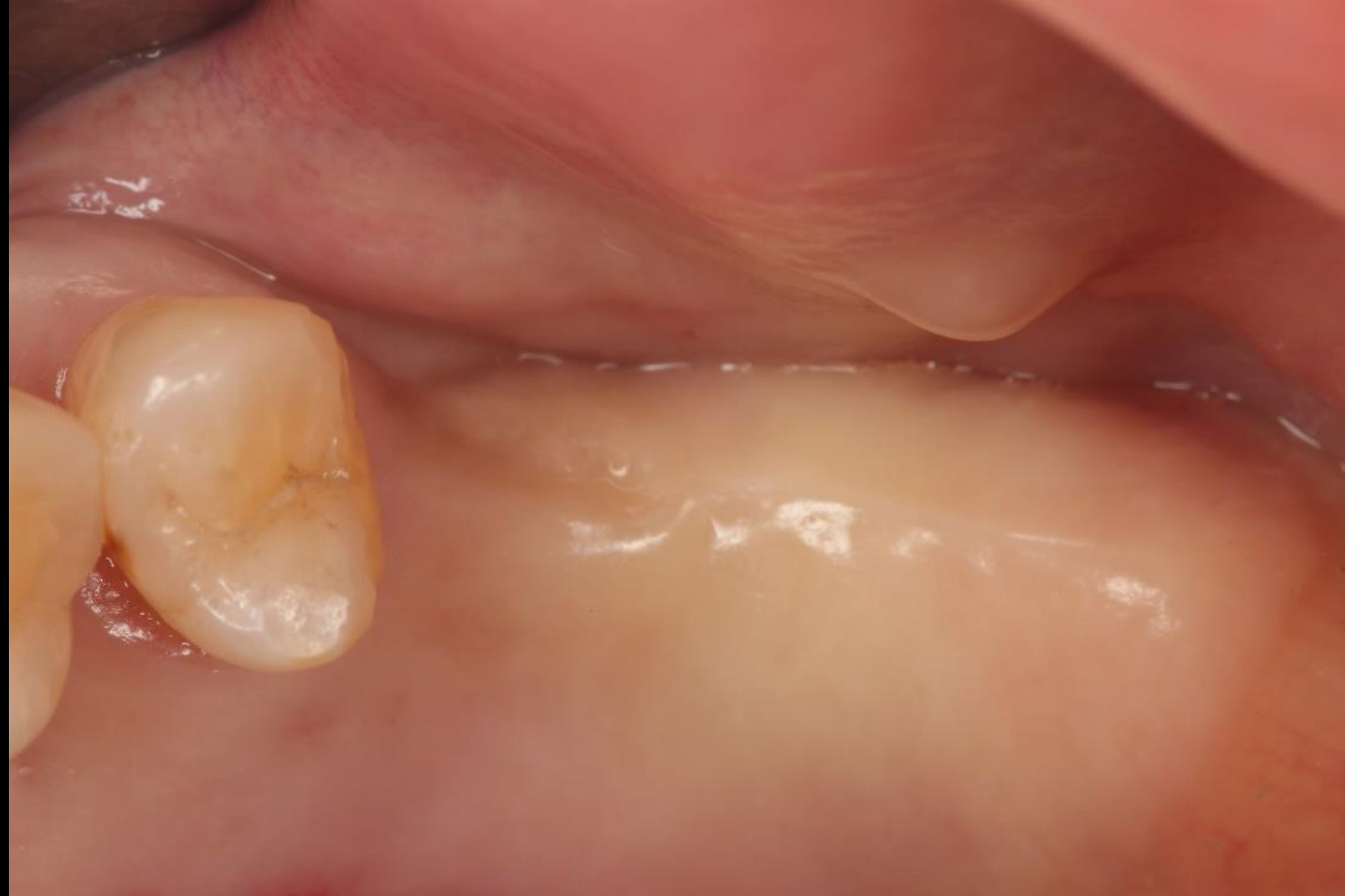Sinus lifting using DASK



Pre-op

Similar case 2

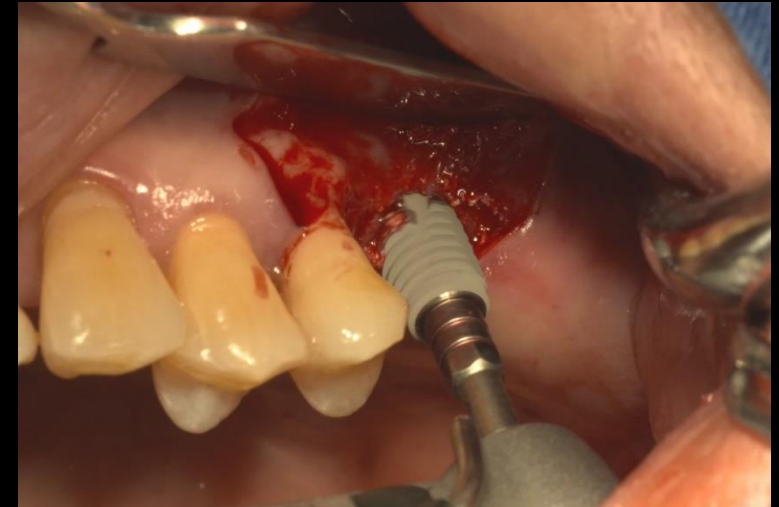
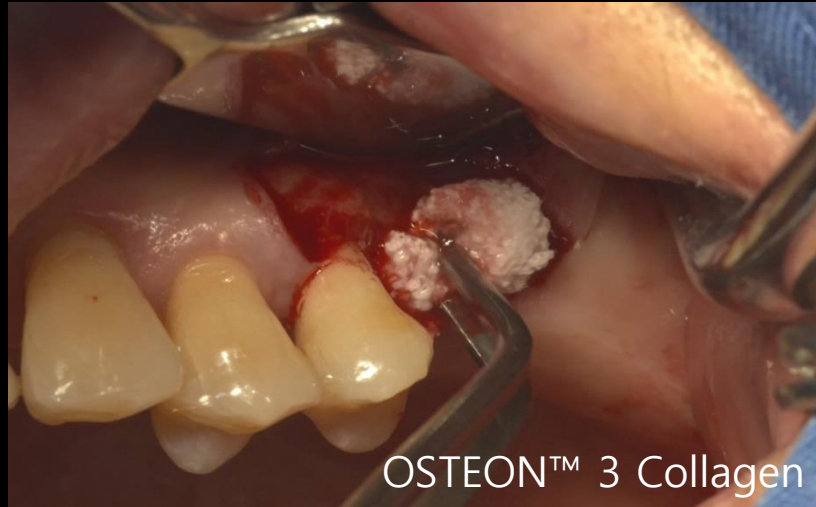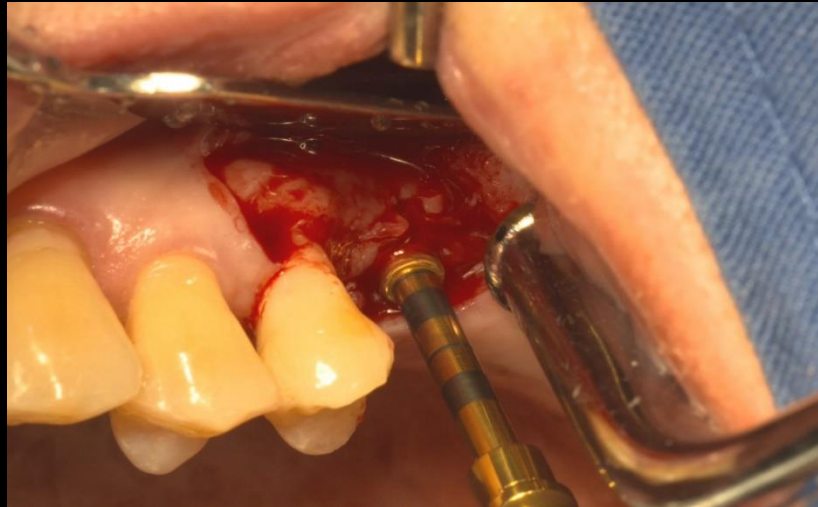
Sinus lifting using DASK



Pre-op

Similar case 2

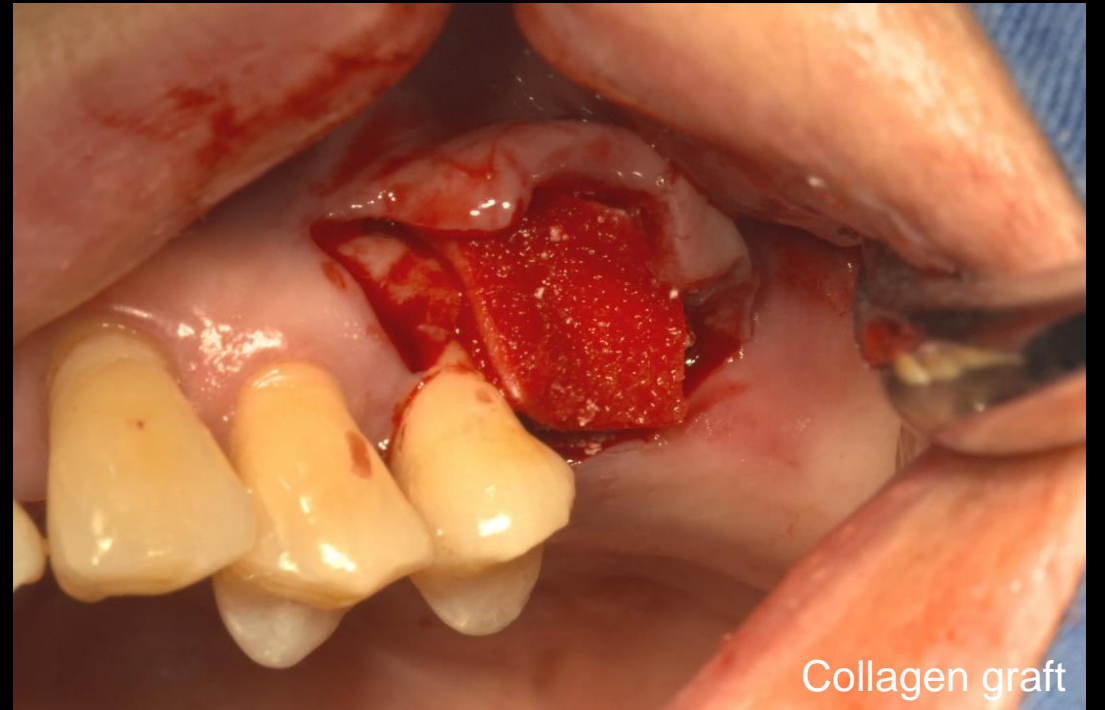
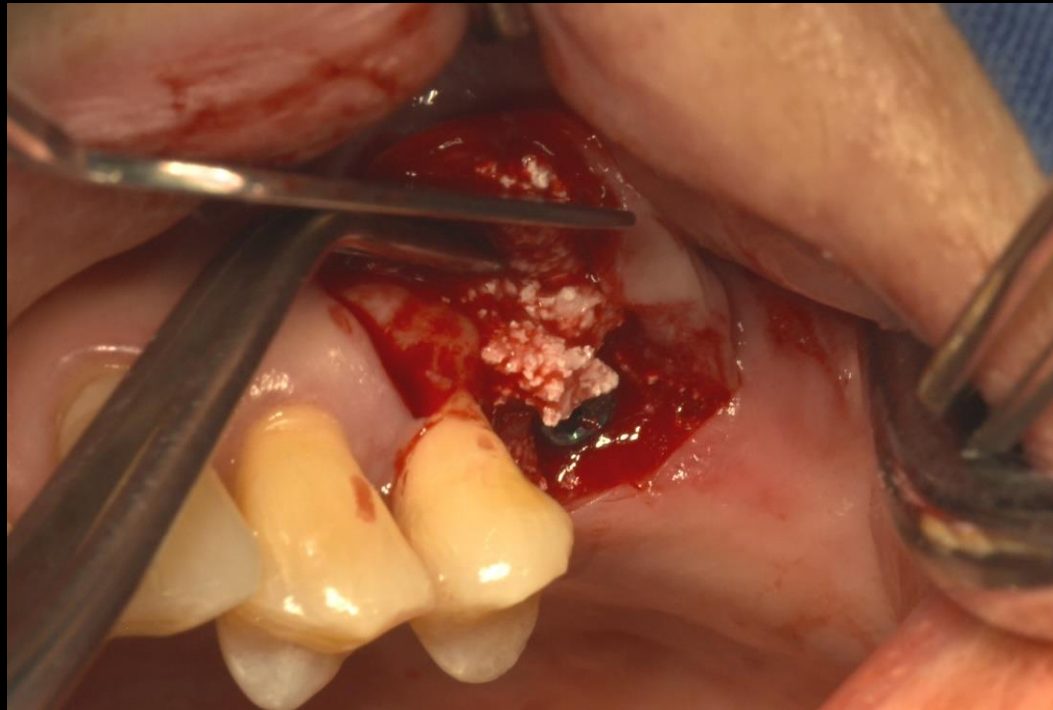
Sinus lifting using DASK



Surgery

Similar case 2

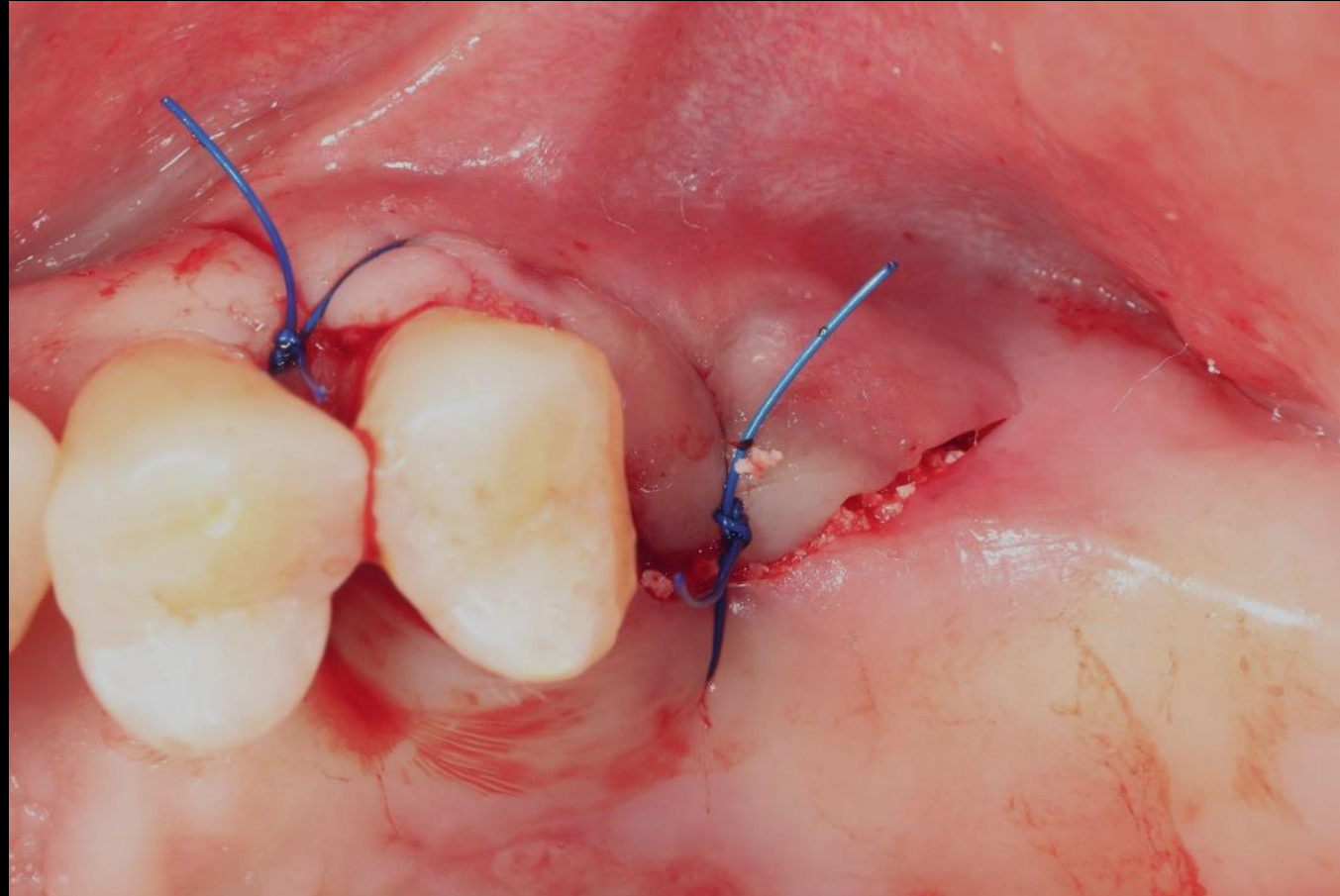
Sinus lifting using DASK



Surgery

Similar case 2

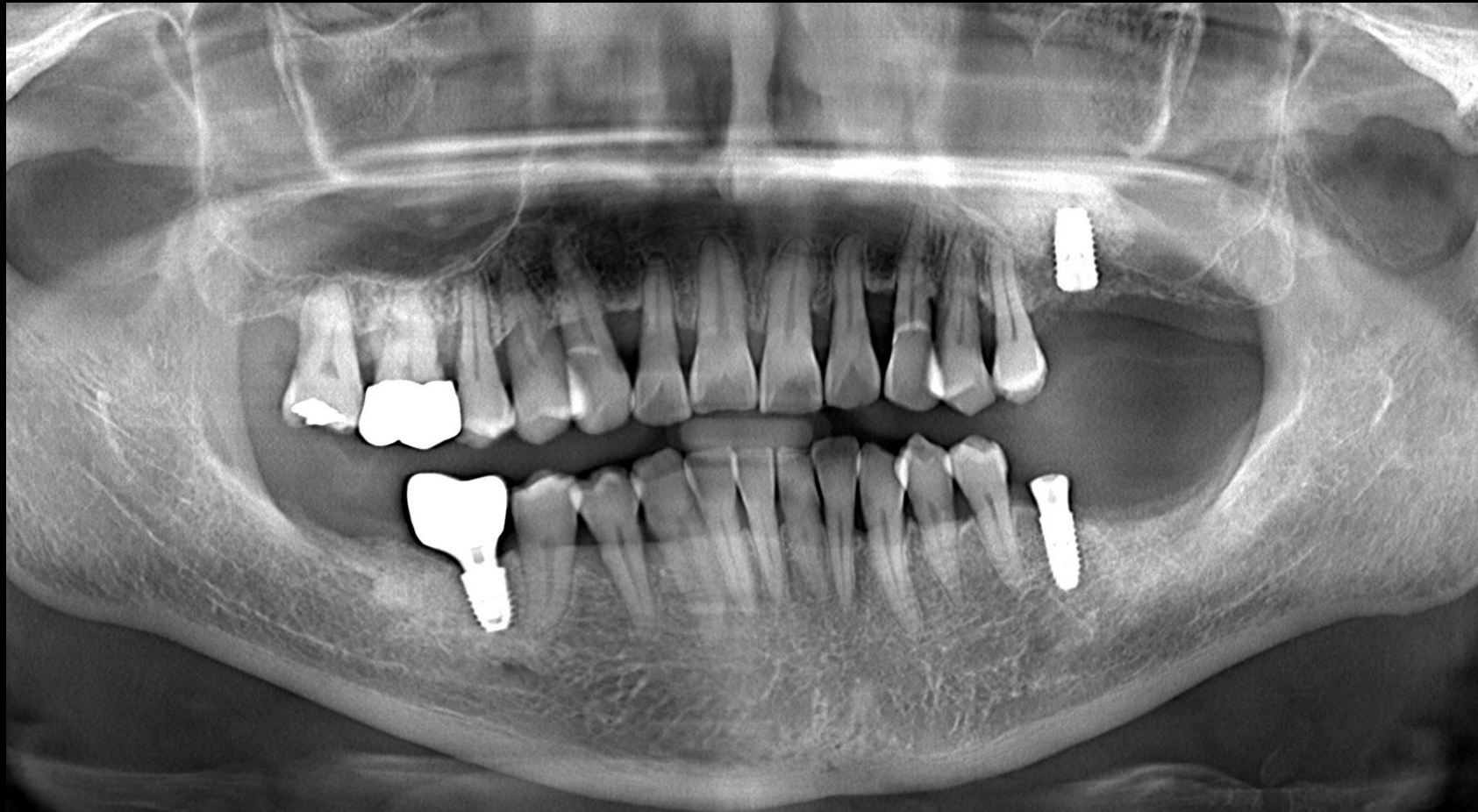
Sinus lifting using DASK



Post-op

Similar case 2

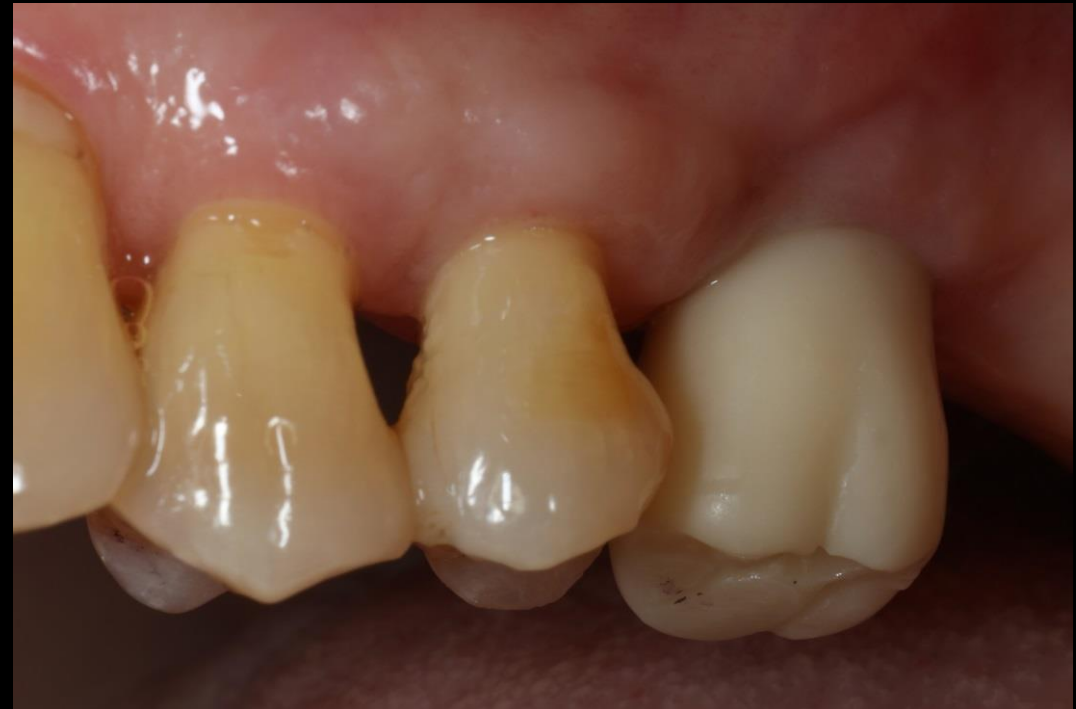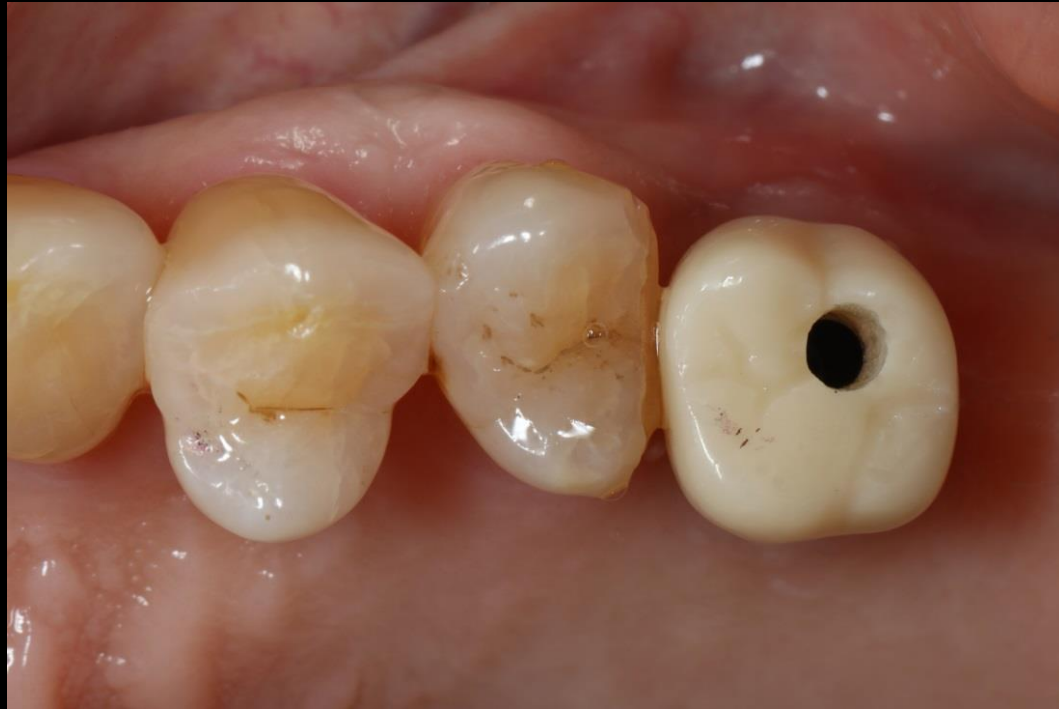Sinus lifting using DASK



Post-op

Similar case 2

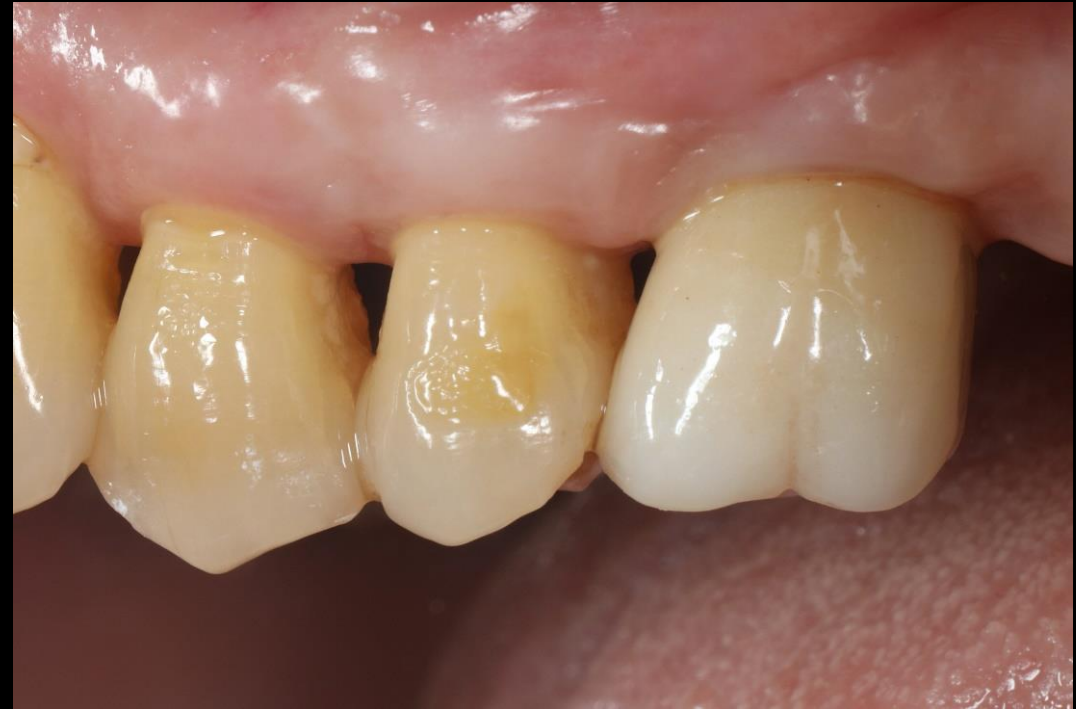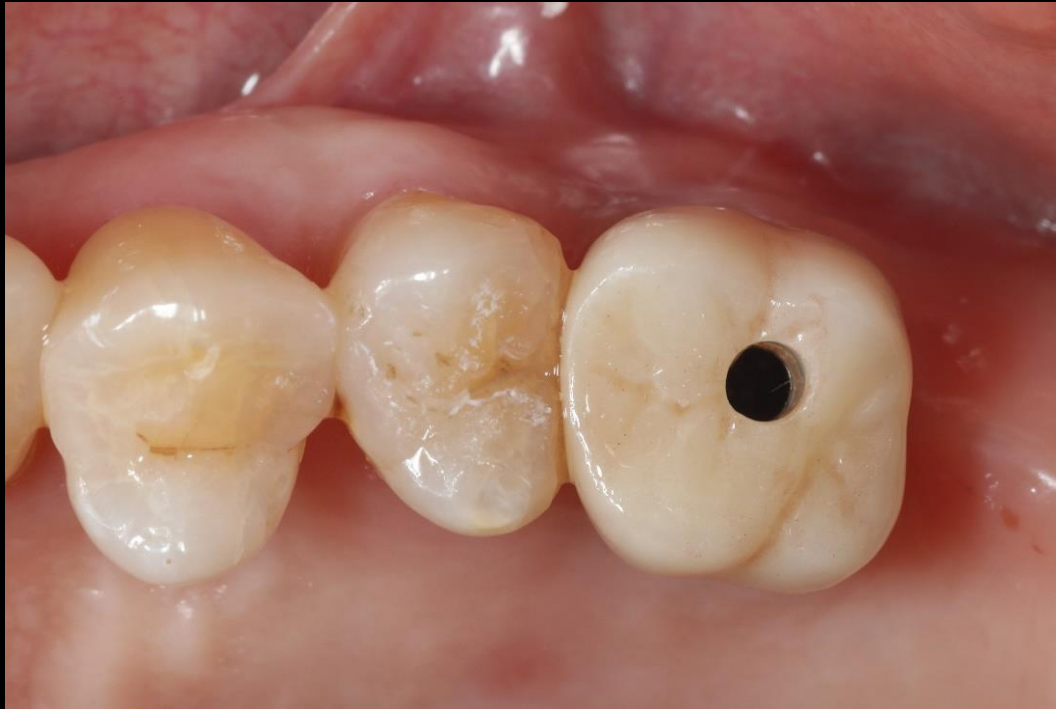Sinus lifting using DASK



Provisional restoration

Similar case 2

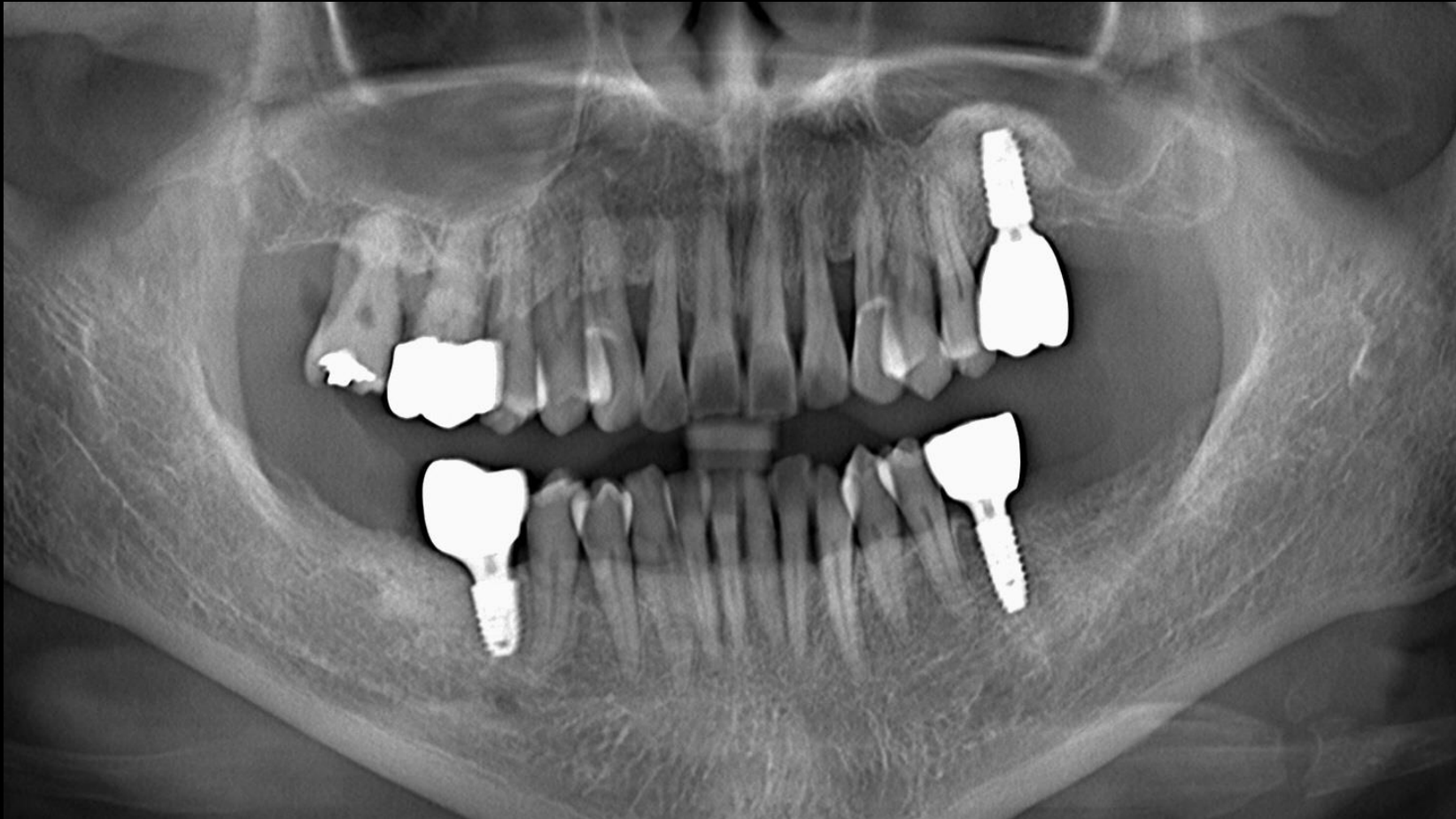
Sinus lifting using DASK



Final prosthesis

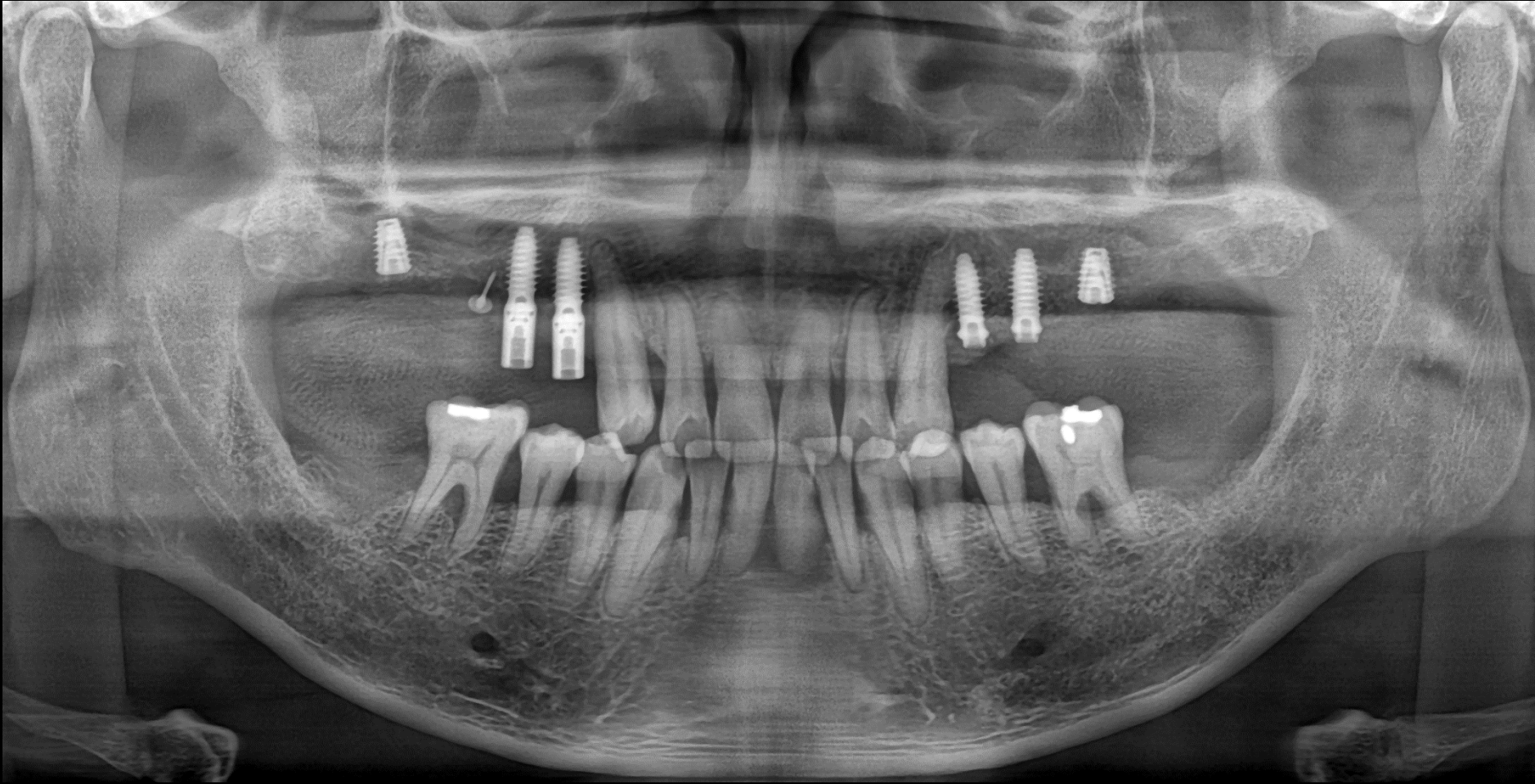
Similar case 2

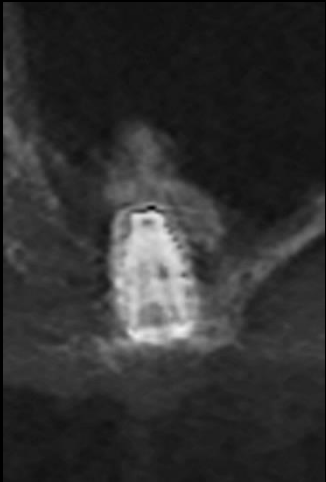
Sinus lifting using DASK



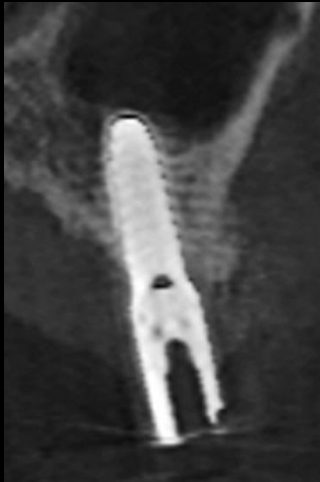Final prosthesis

Post-op

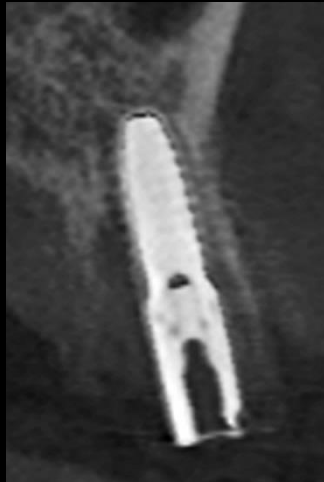



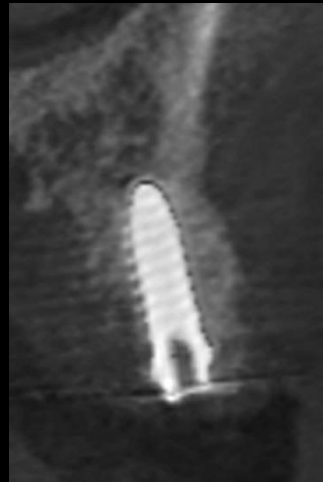#17



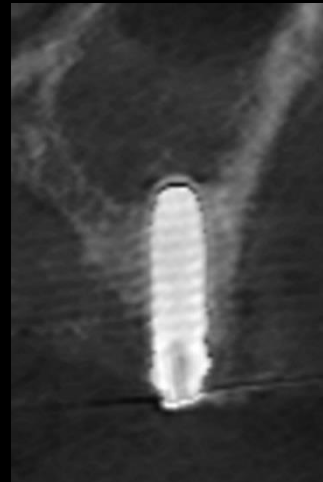
#15



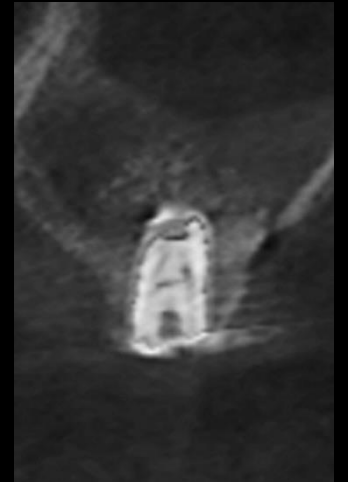#14



#24

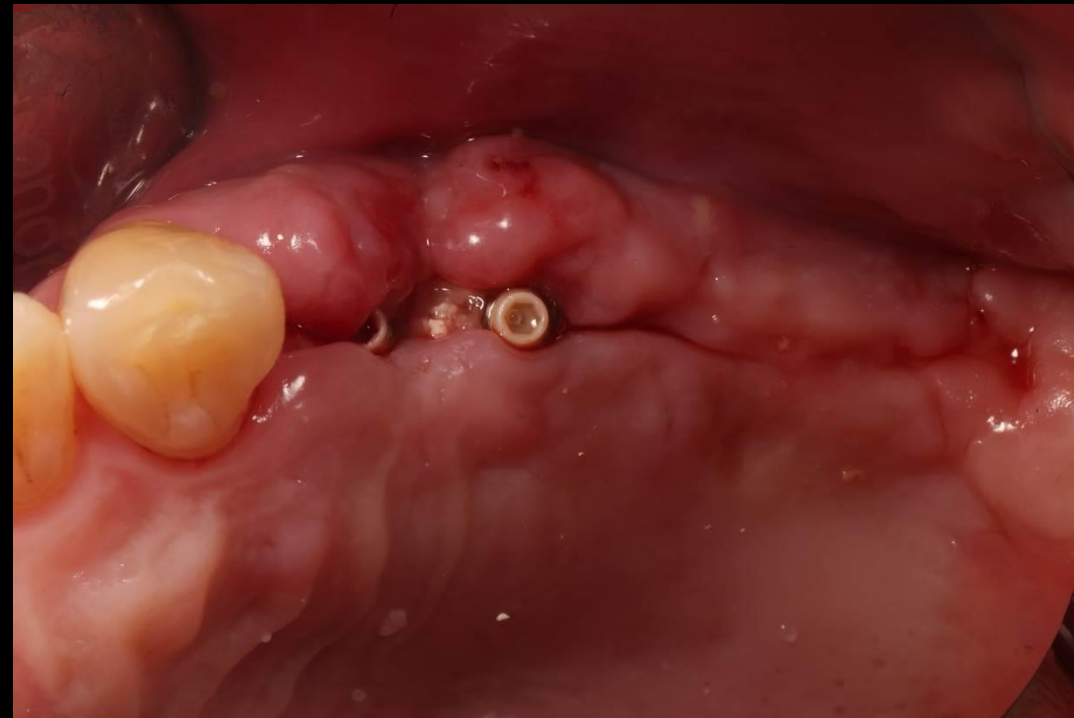
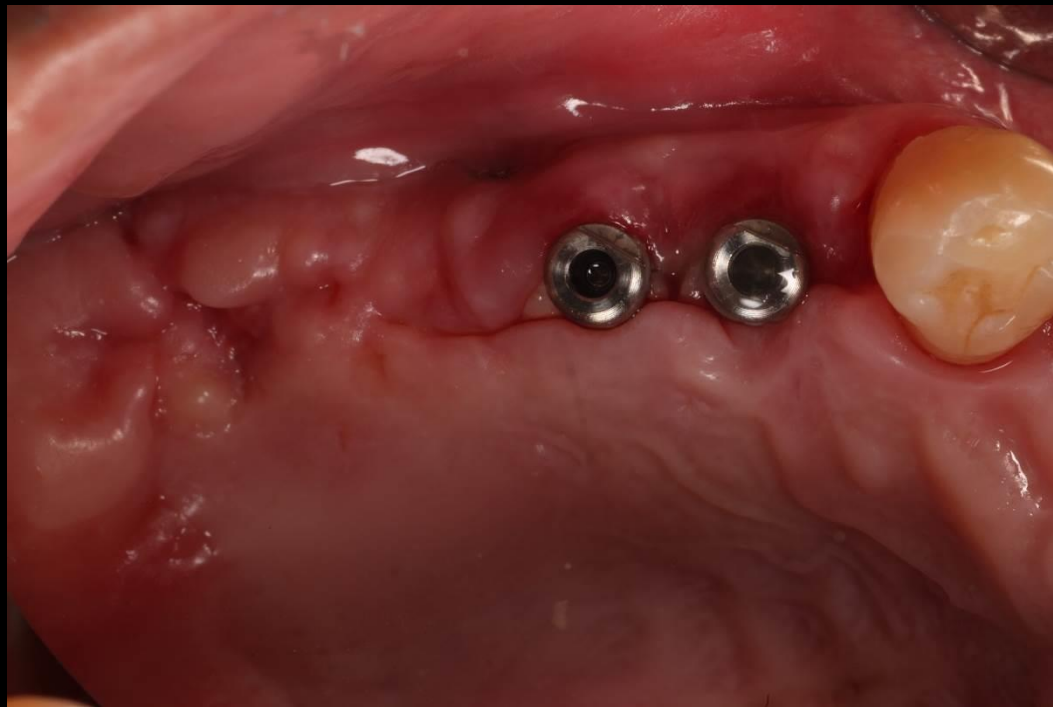

#25

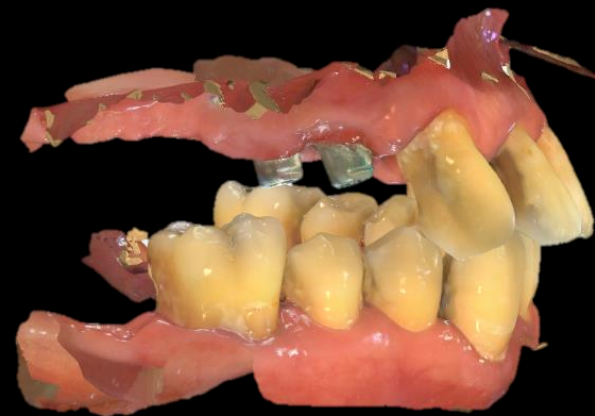
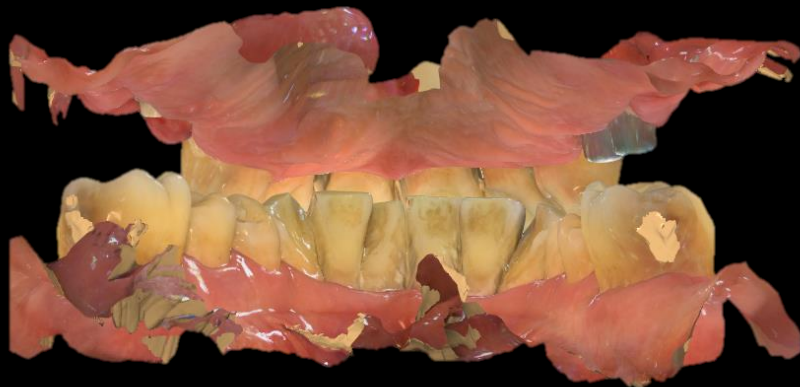
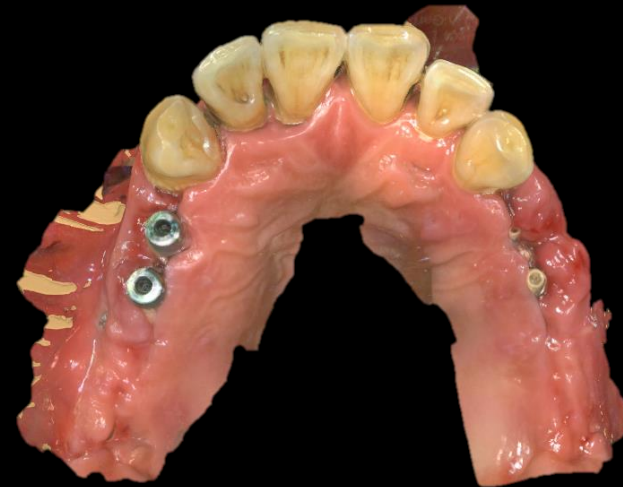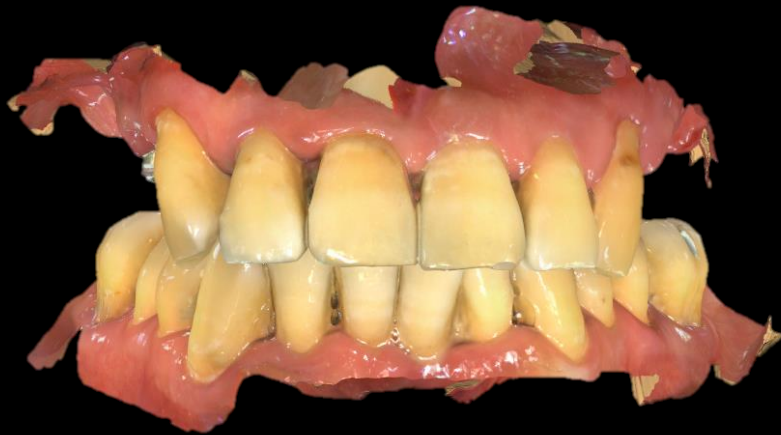#26

Healing 1 weeks



Intra oral scanning



CAD (Provisional restoration)

