



# Surgey

Dr. Jae-Wook Jung

2024. 04. 19 (FRI.)



## [Case Preview]

Implantation on narrow ridge and severe bone loss area  
for immediate loading

using **bright Tissue Level** and OSTEON™ Xeno collagen

## Patient Information

**Age** : 57

**Sex** : Male

### Chief Complaint

Multiple missing teeth

## Past Dental History

Extraction # 14~24, 25,37

Implantation on #16,15,25,27 #46=44,43=42=,  
#34

## Present illness

Periodontitis

Severe Bone loss on #upper ant. missing area,  
and #25 implant

Severe mobility on #35,36

Implant sleeping state on #27

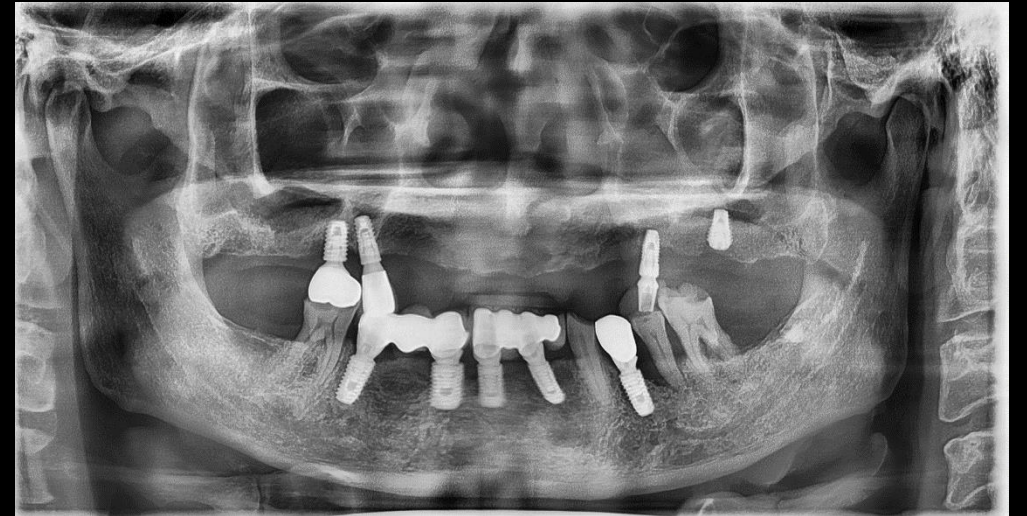
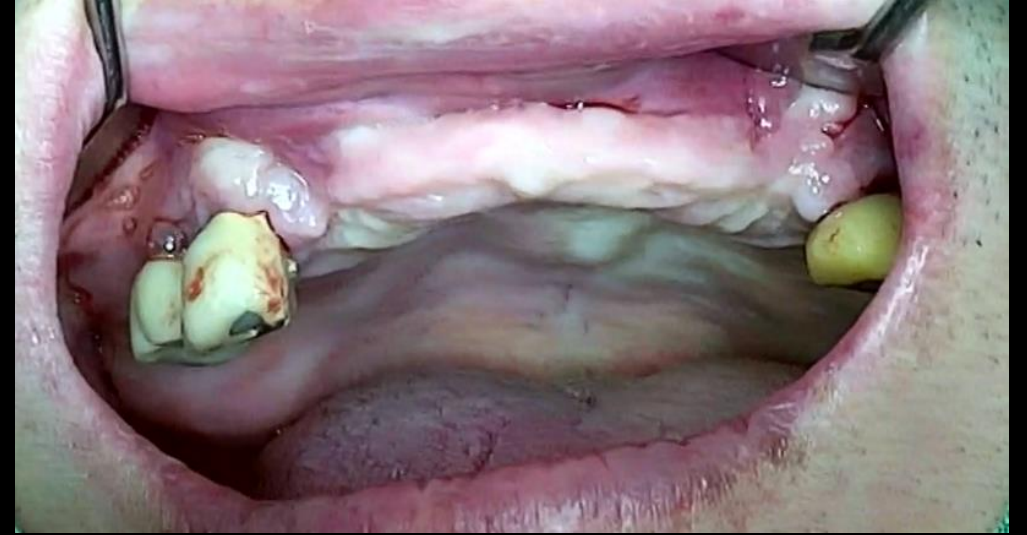
# Today's Surgery Plan

**#14, 12, 22, 24**

- Implant at surgery on # 14, 12, 22, 24 with bright Tissue Level implant and bone grafting with OSTEON™ Xeno collagen

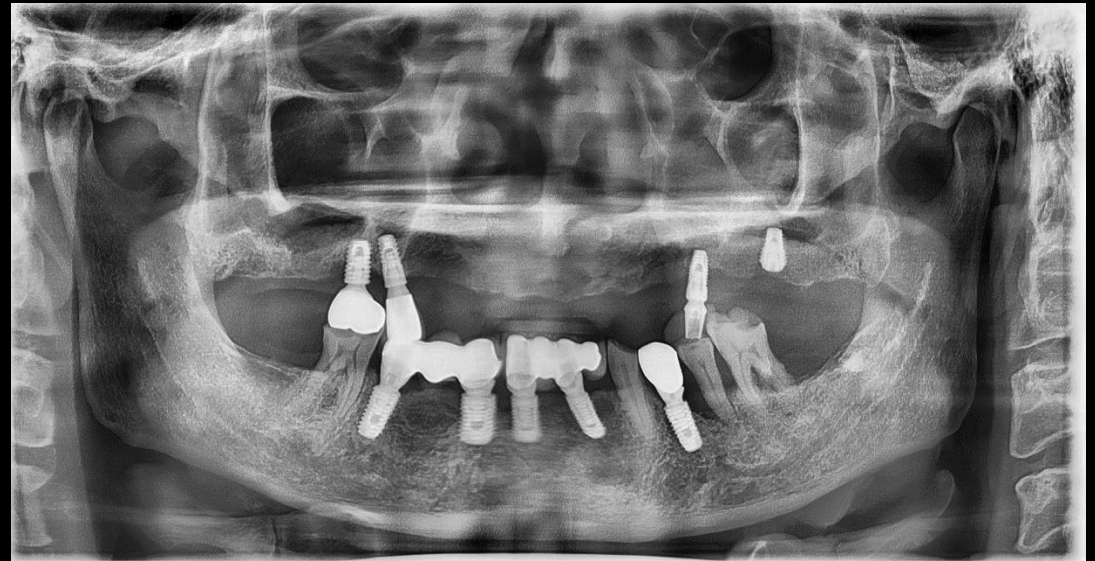
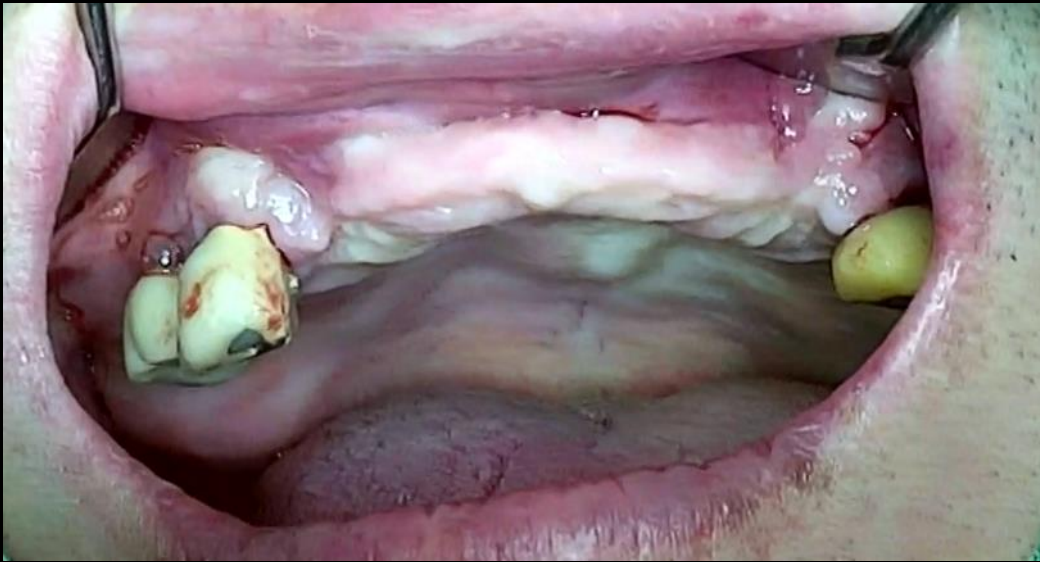
## Prosthetic Plan

- Immediate provisionalizaion on #14=12=22=24 with digital technique
- Removal of #25 implant before final prosthetic treatment



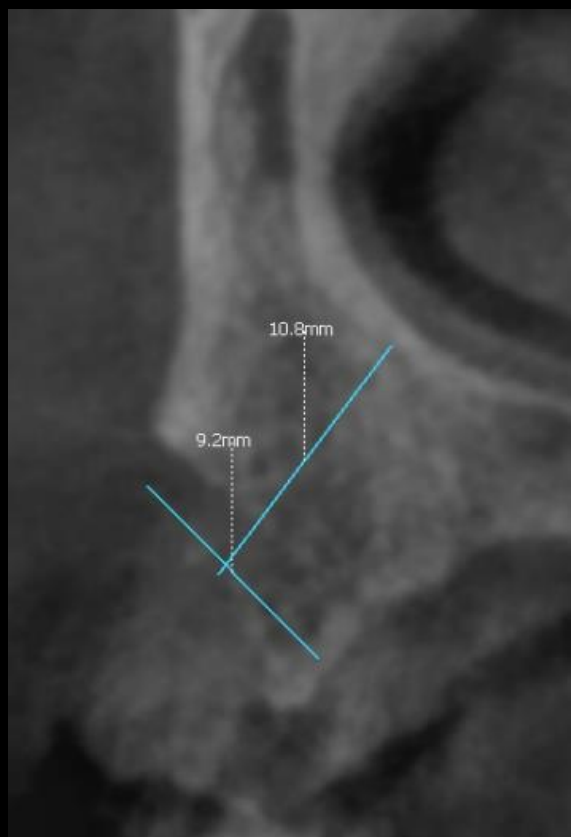
Pt. Ahn (57/Male)

Oral exam

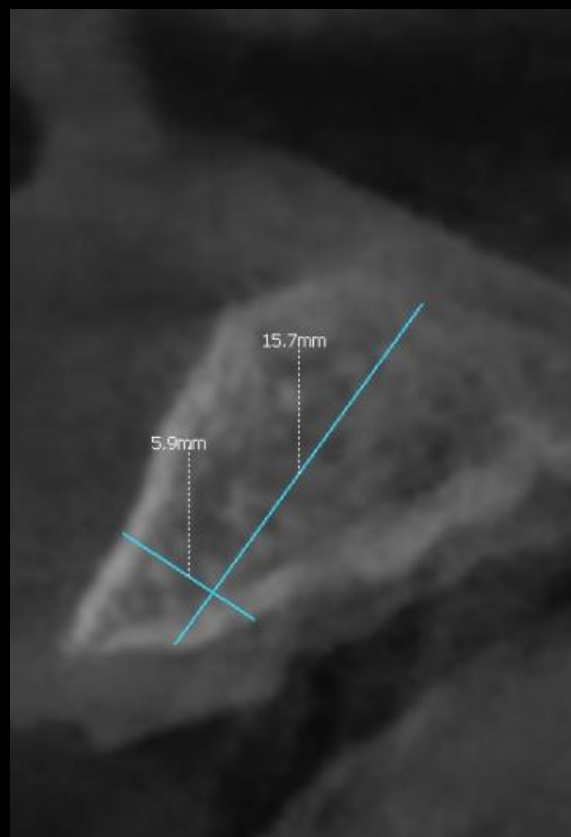


# Pt. Ahn (57/Male)

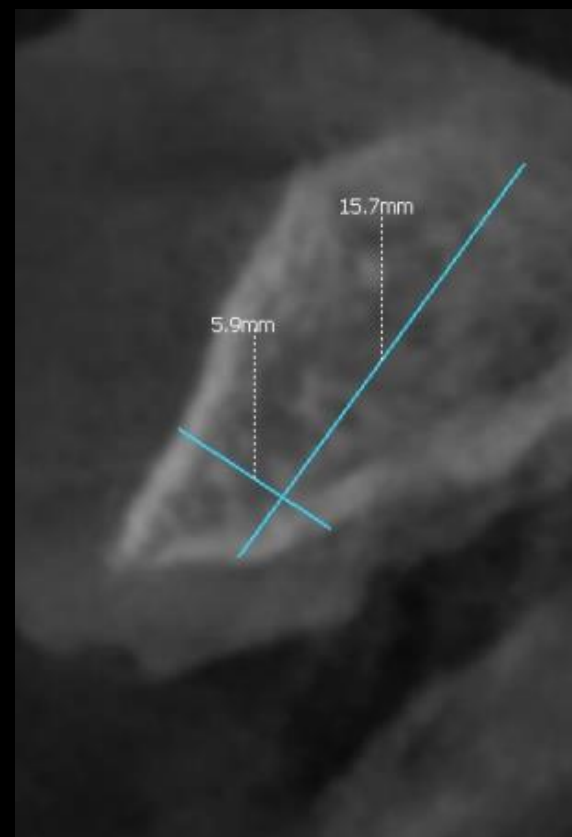
#14



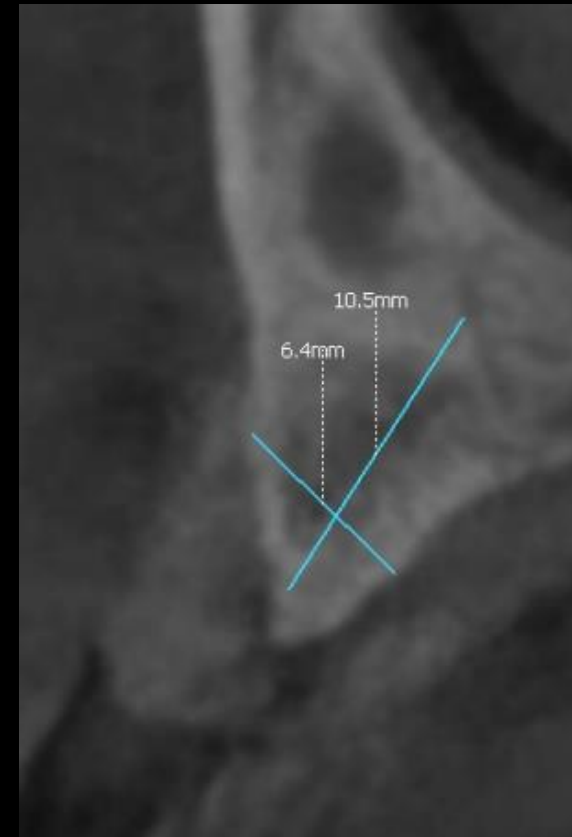
#12



#22



#24




# bright Tissue Level

For **Simplify Surgical Procedure**

- Thin, Deep & Sharp Thread
- Final Drill Only

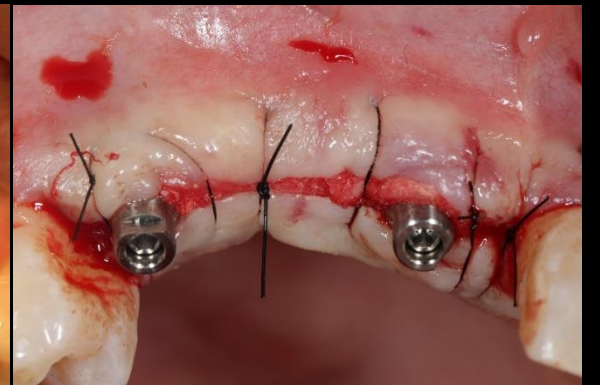
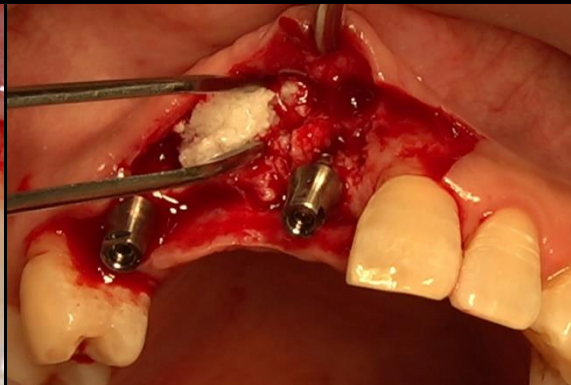
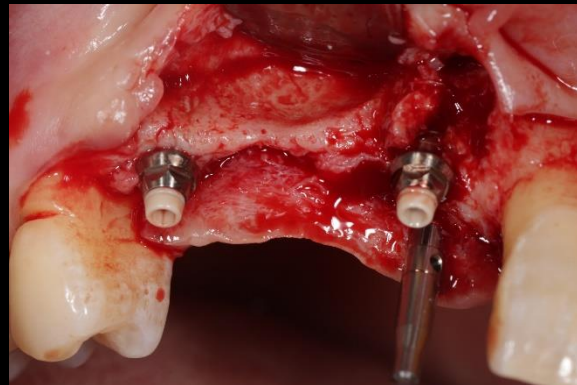
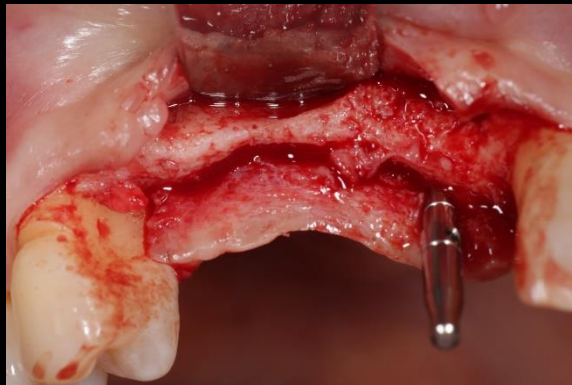
For **Simplify Prosthetic Procedure**



# OSTEON™ Xeno Collagen



- Ossification ability of Xeno graft
- Easy handling of collagenized bone graft
- Optimal collagen absorption speed



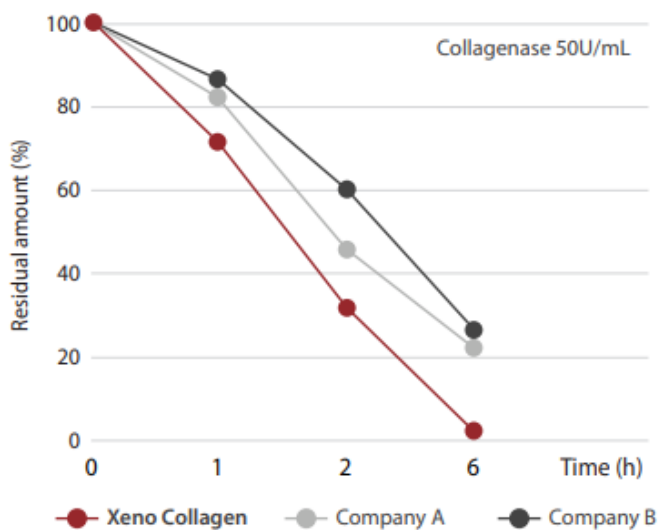


# OSTEON™ Xeno Collagen

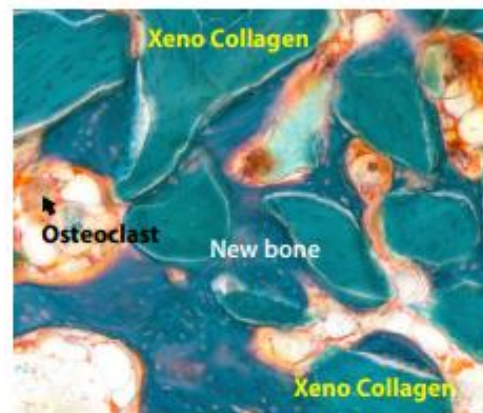


After hydration

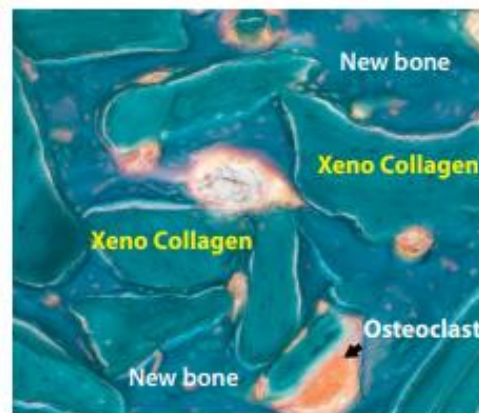
## Collagen Degradation Rate



## Animal Test Rabbit calvaria model

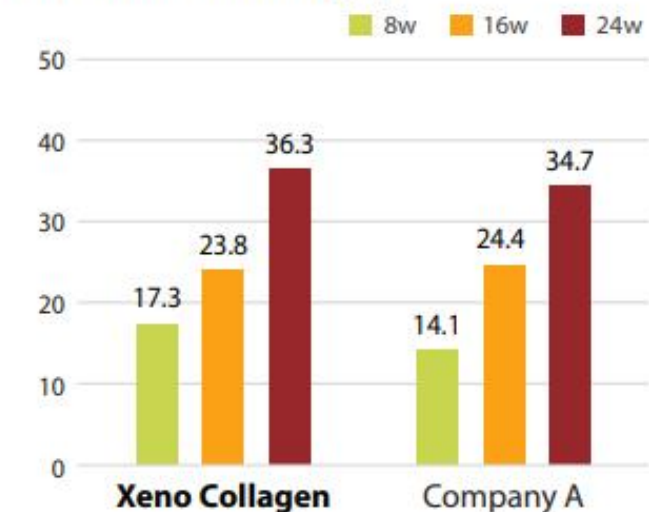


8 weeks



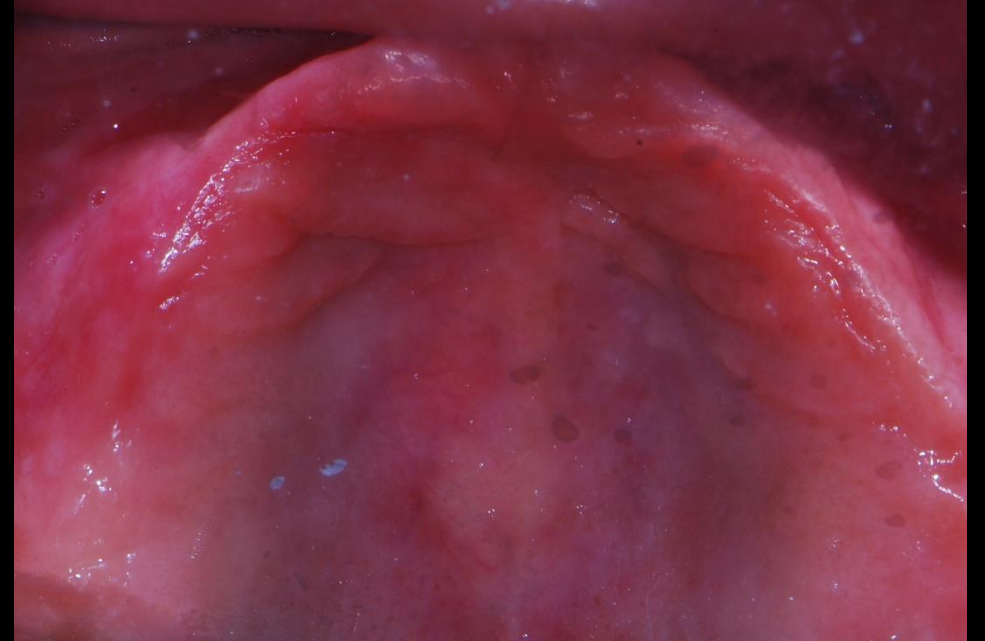
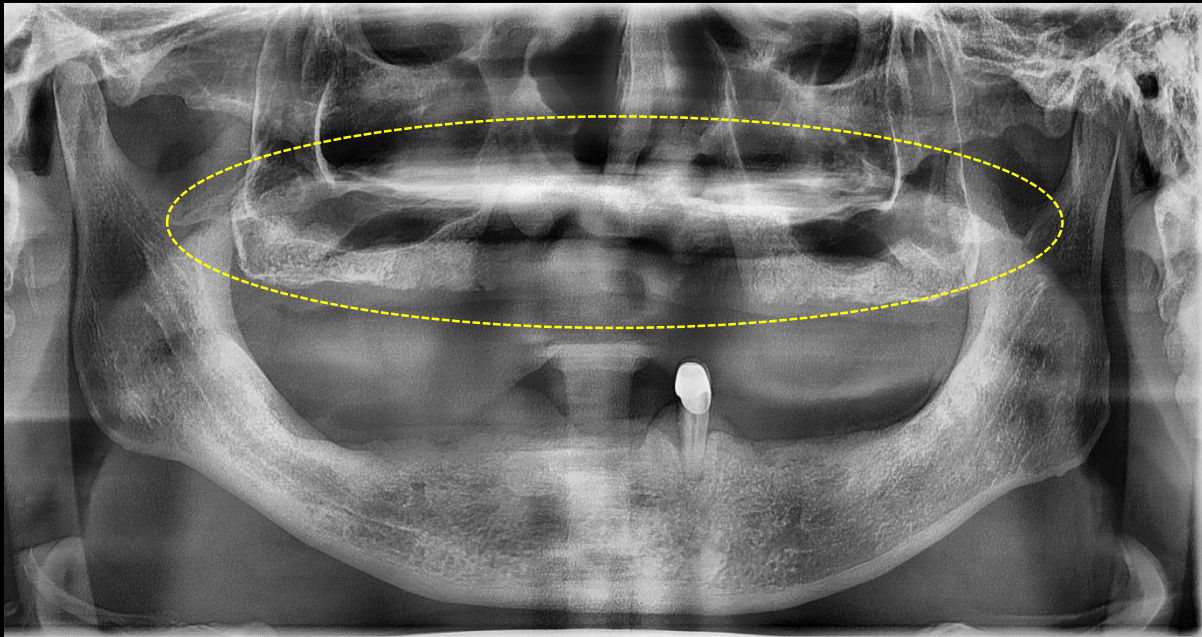
16 weeks

## New Bone Volume (%)



## Similar case

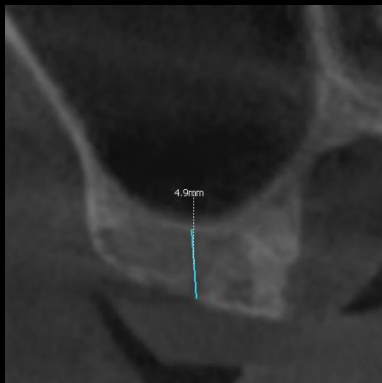
Implantation on narrow and short ridge with **bright** Tissue Level



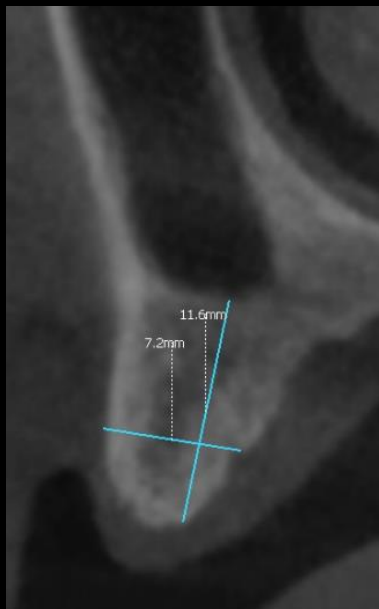
# Similar case

Implantation on narrow and short ridge with **bright Tissue Level**

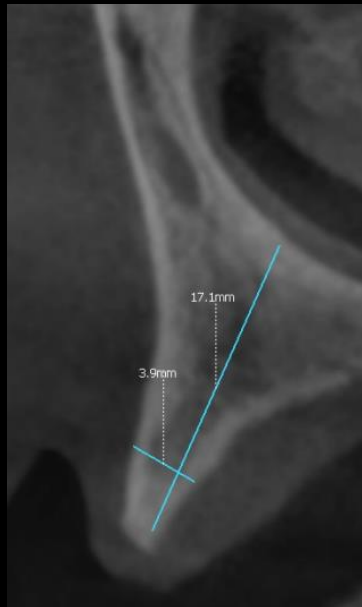
#16



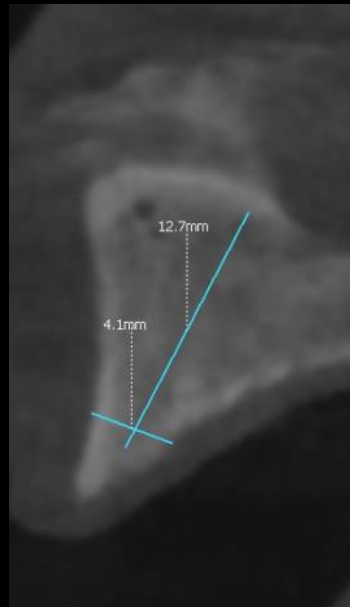
#14



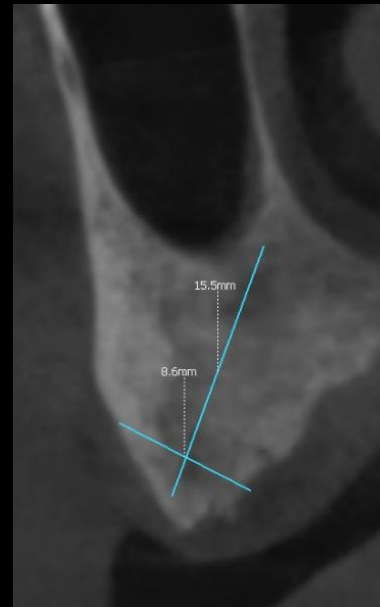
#13



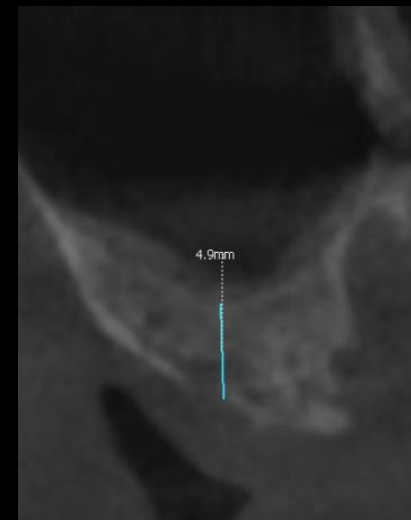#21



#24

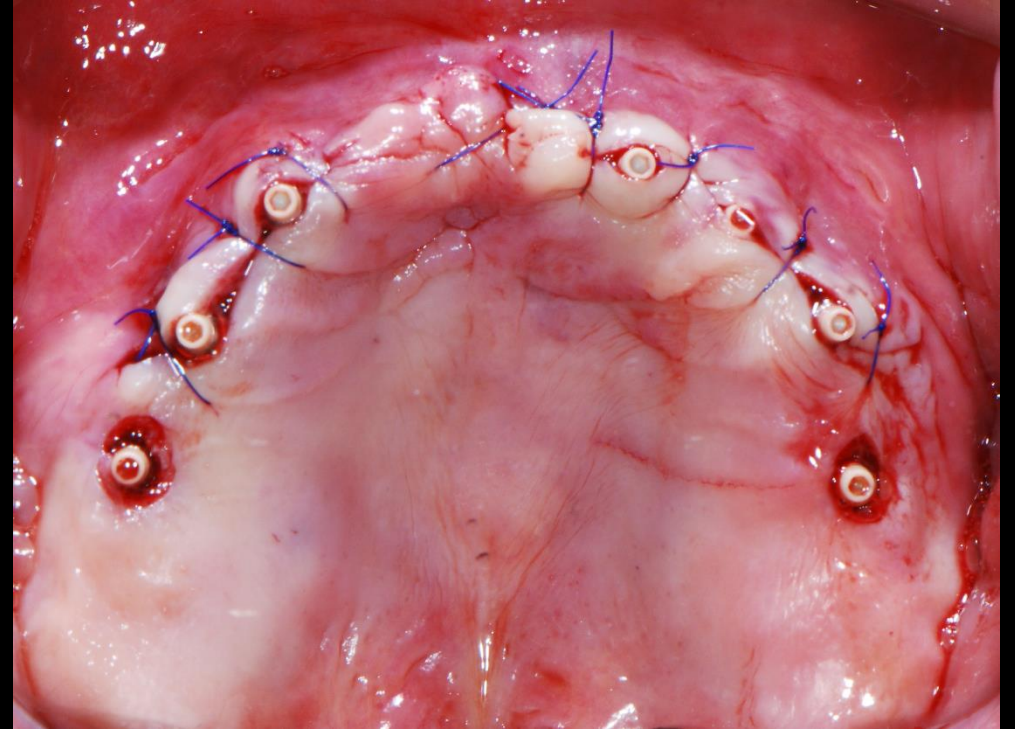
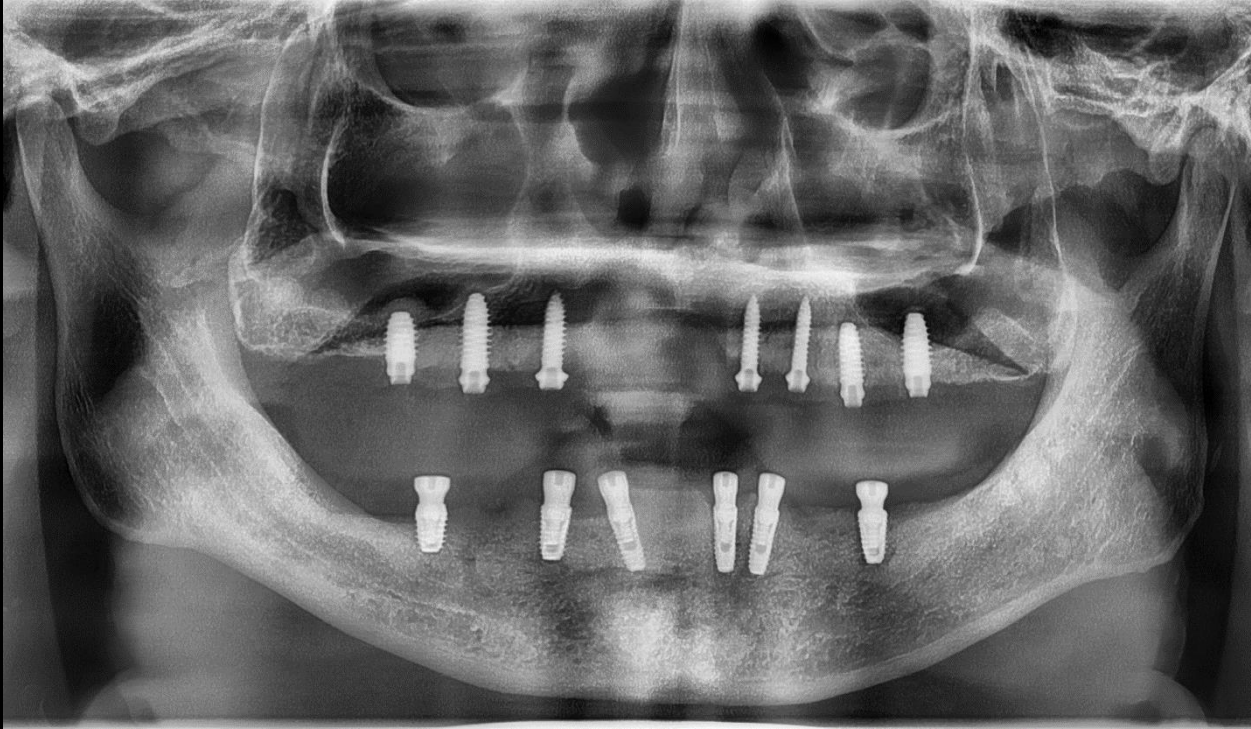


#26



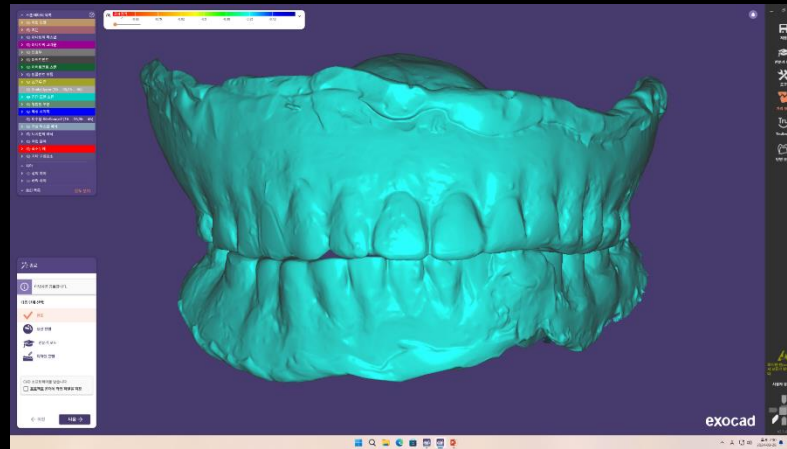
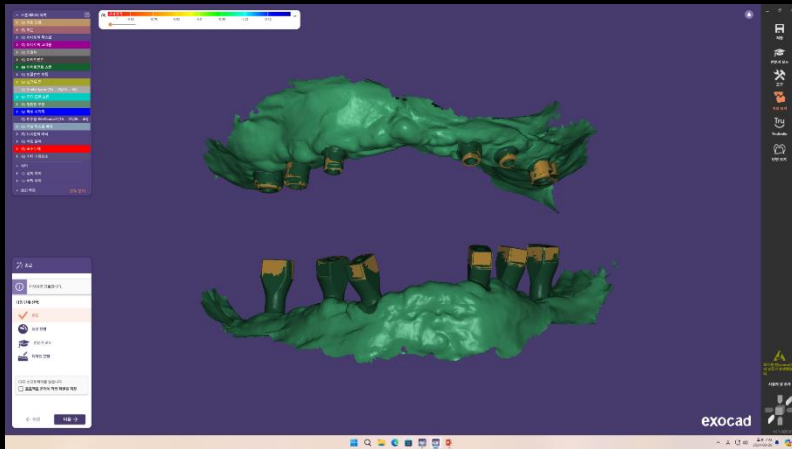## Similar case

Implantation on narrow and short ridge with **bright** Tissue Level



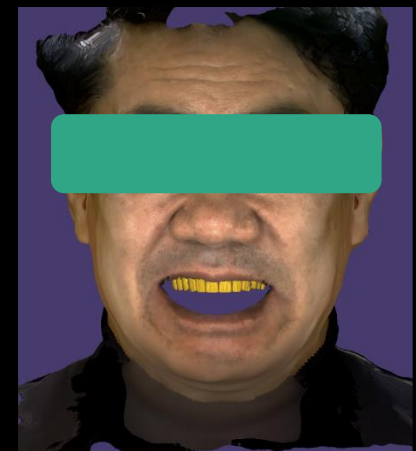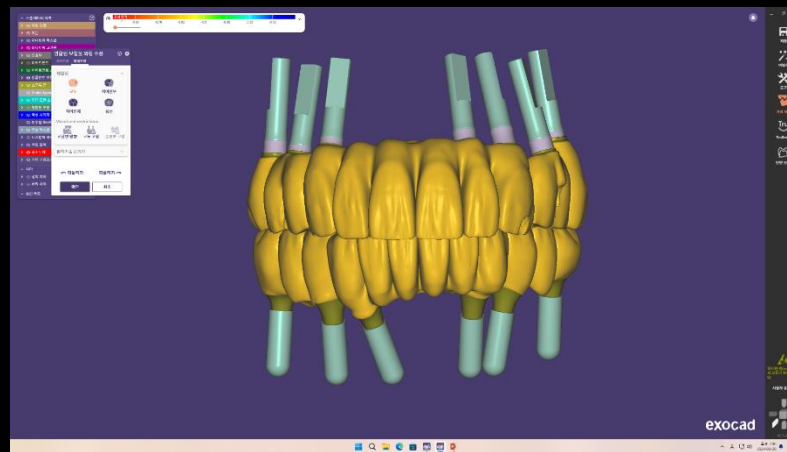
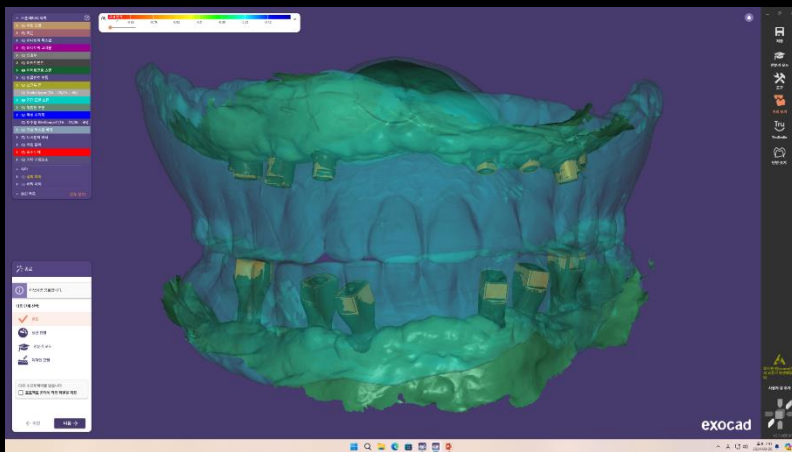
## Similar case

Implantation on narrow and short ridge with **bright** Tissue Level



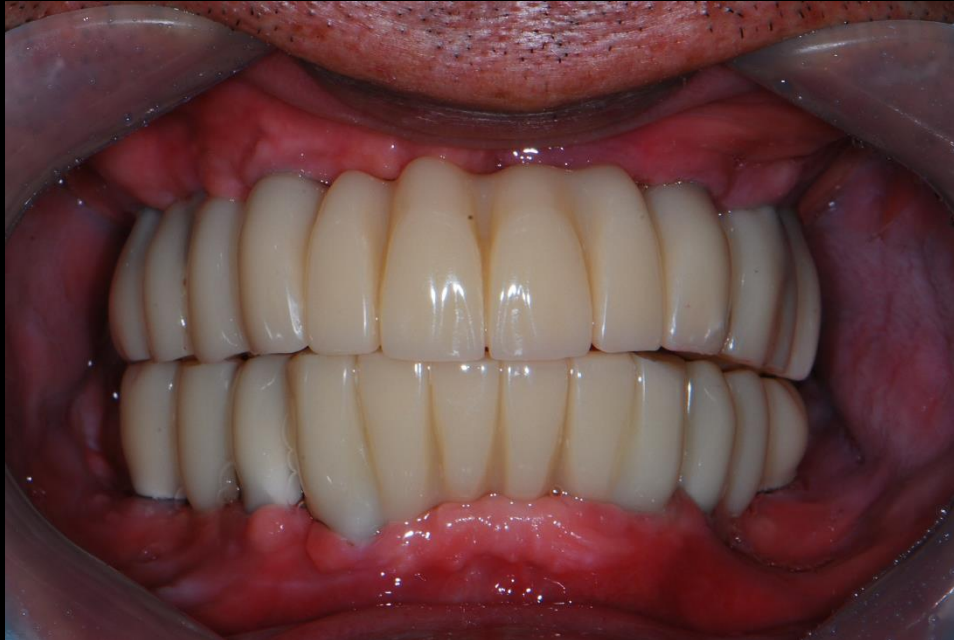Fully digital technique

- IOS, Facial scan
- Reference from Temp.Denture



## Similar case

Implantation on narrow and short ridge with **bright** Tissue Level

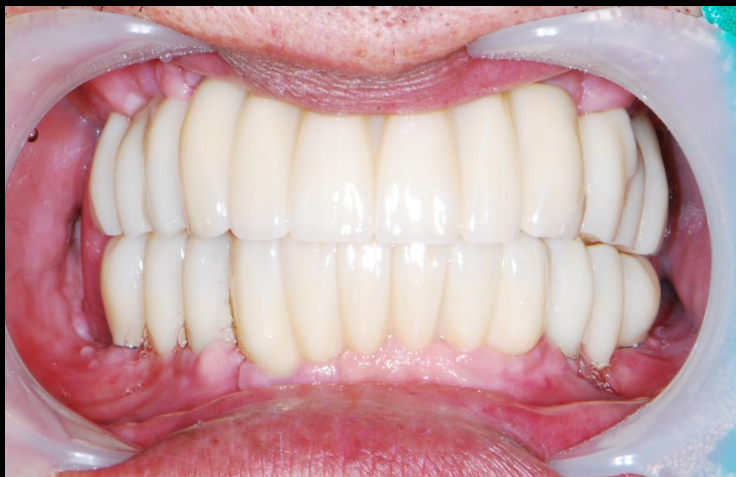
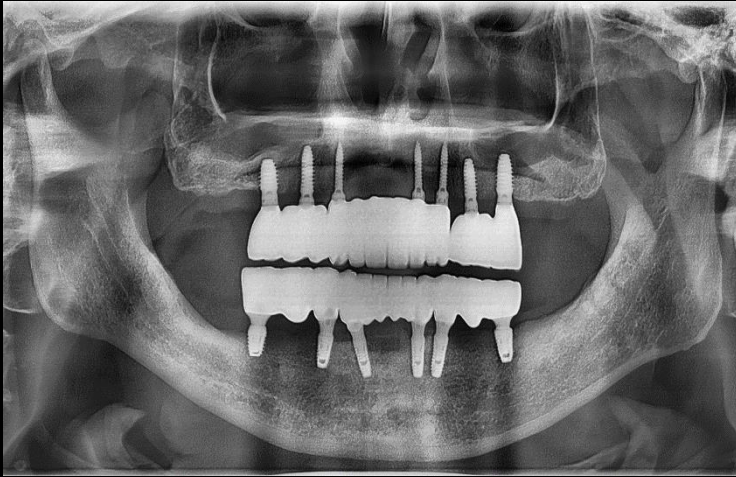
### Provisionalization

- Fully digital technique (modeless)
- Copy of temporary denture

## Similar case

Implantation on narrow and short ridge with **bright** Tissue Level

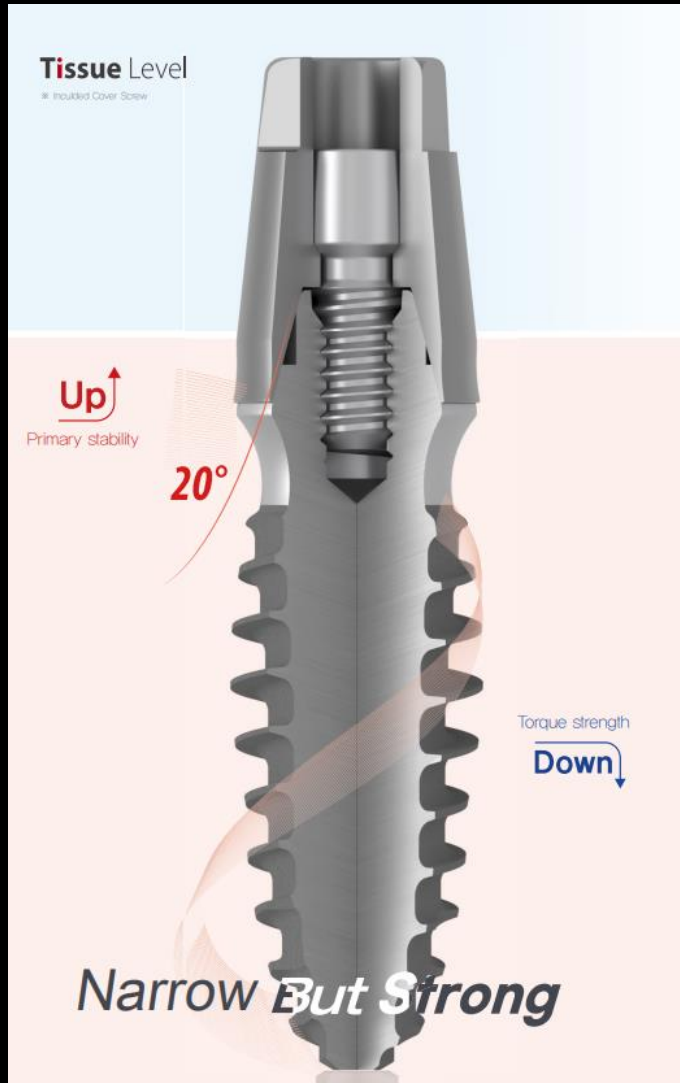


### Final Prosthesis

- Fully digital technique (modeless)
- Copy of temporary prosthesis

## Similar case

Implantation on narrow and short ridge with **bright** Tissue Level



Scan Comfort Cap

Ø3.8 ONE-Platform / 20° External Taper Fit

- Simplified Prosthetic Work Flow
- **Easy digital work flow**
- **Easy immediate prosthetic fabrication (esp. Multiple case)**
- **Minimum visit of dental clinic**



