



LIVE

Surgery

Dr.Byoung Kyou Park

2025. 01. 17(FRI.)



[Case Preview]

bright Implant : A Revolution in Easy, Immediate Implants

Patient Information

Age : 69

Sex : Male

Chief Complaint

I would like to get implants to restore the broken teeth.

Past Dental History

- Old Cr Fracture (#15,12,11,23)

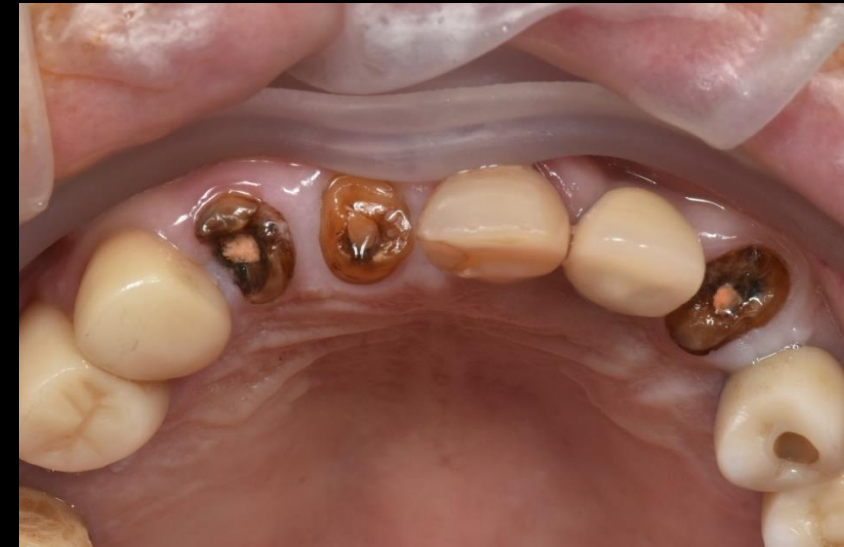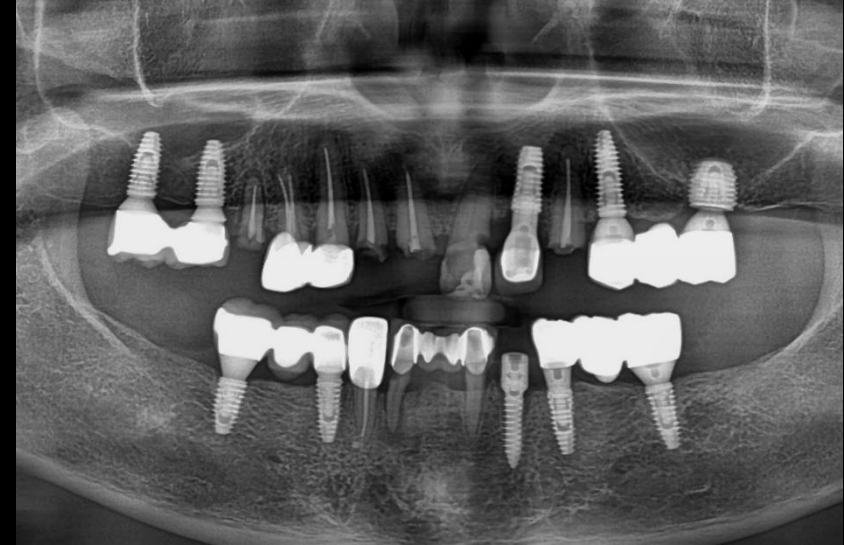Present illness

- #15,12,11,23 : Root rest state (Root caries)

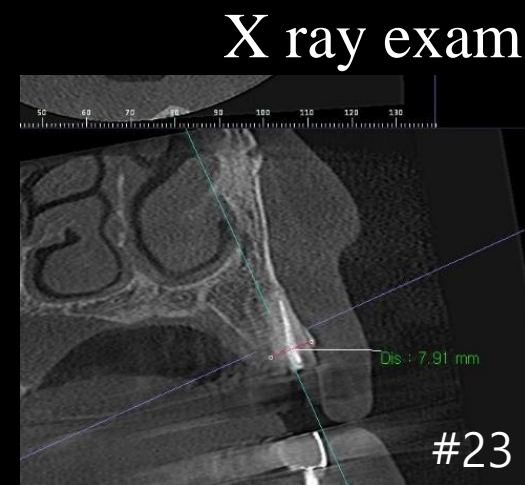
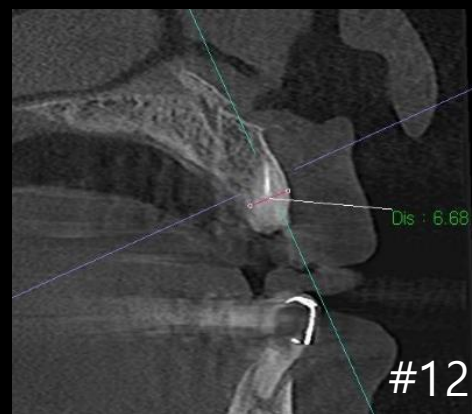
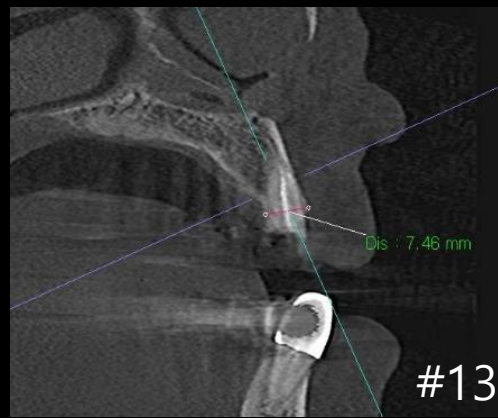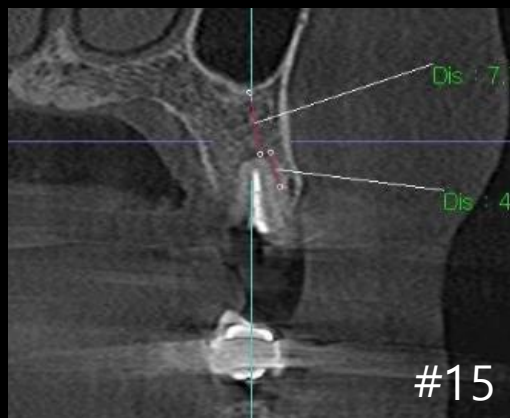Today's Surgery Plan

Surgical Plan

- Extraction on #15,12,11 and 23
- Immediate implant placement on #15,13,12 and 23
(bright Tissue Level Implant)
- Gap filling

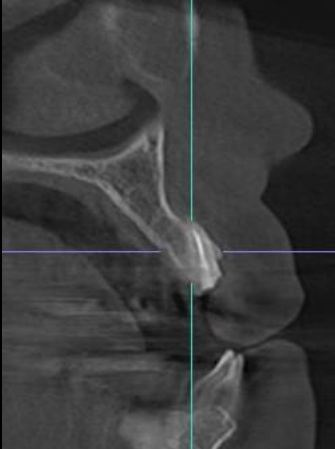
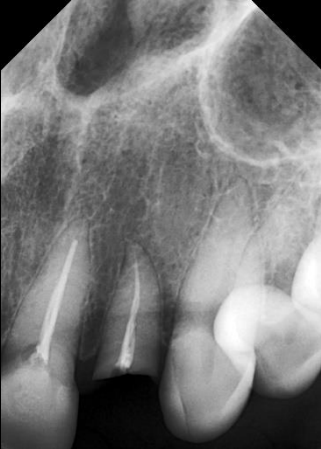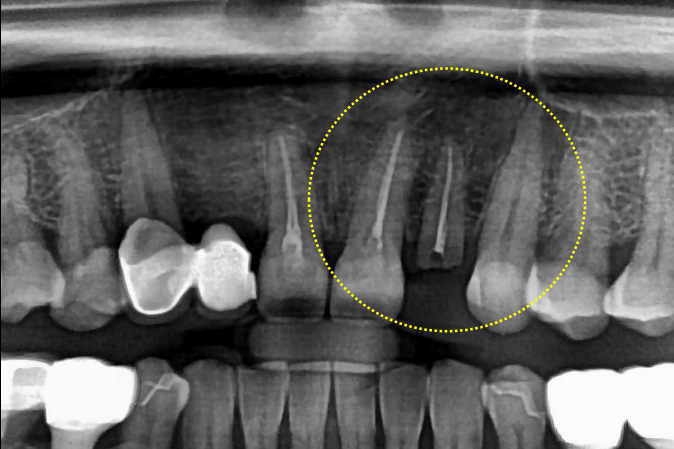

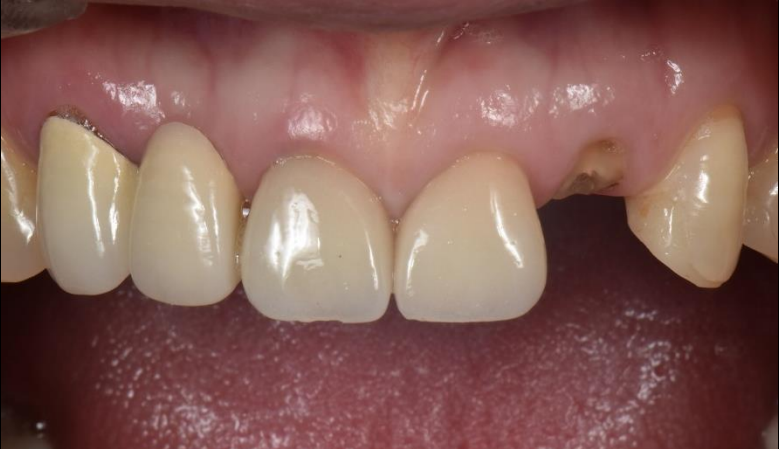
Pt. Jung (69/Male)



Similar case

Immediate implant placement using bright Tissue Level Implant

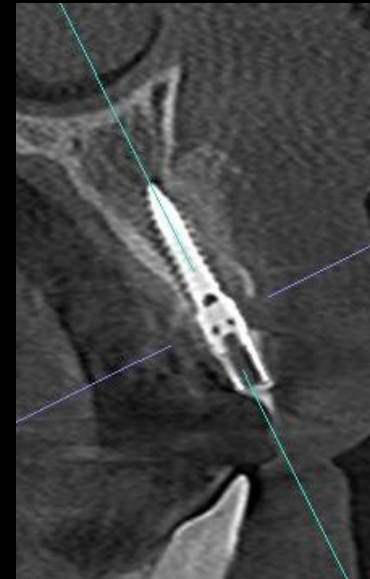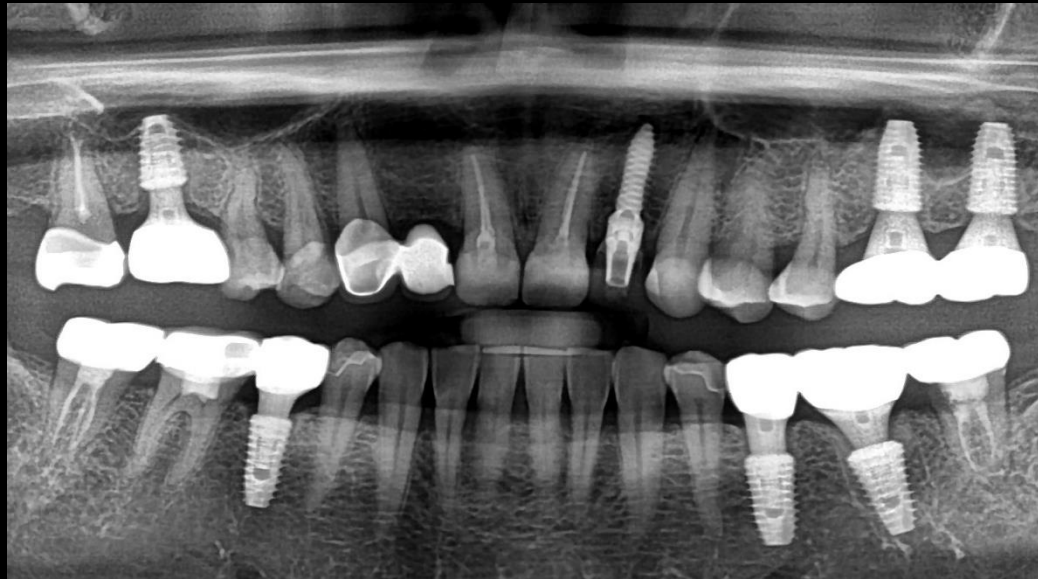


Crown fracture on #22

Similar case

Immediate implant placement using Bright Tissue Level Implant

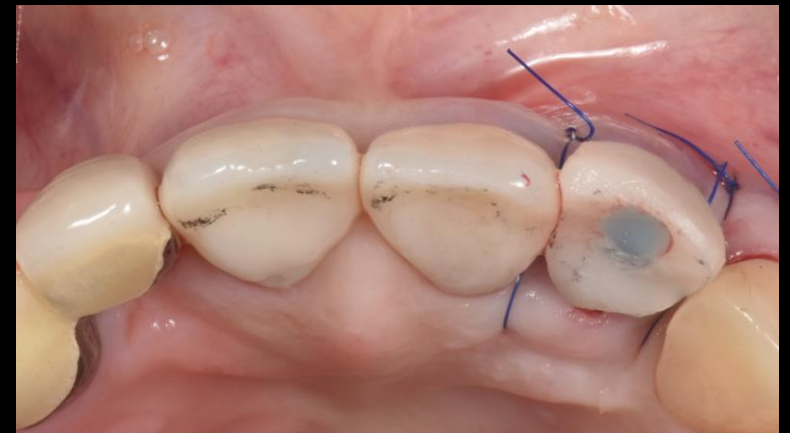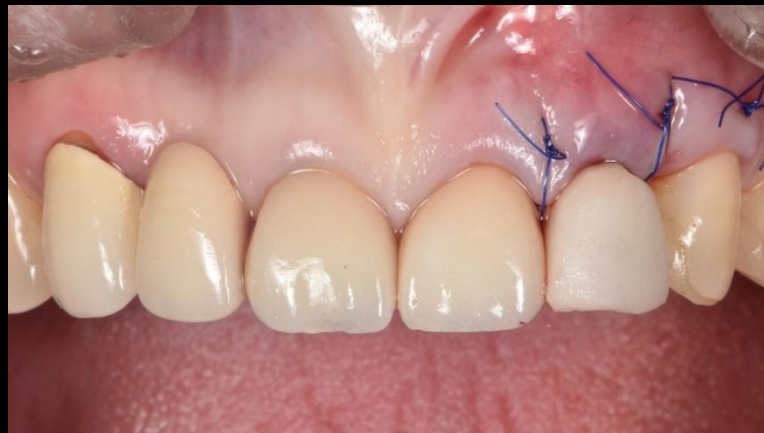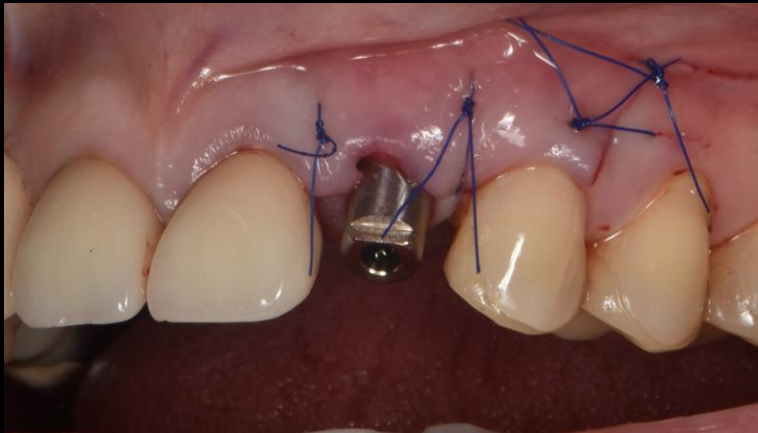Post-op



Similar case

Immediate implant placement using Bright Tissue Level Implant

Post-op



- bright Tissue Level 383011
- OSTEON™ Xeno Collagen
- Collagen graft 2

