



Surgey

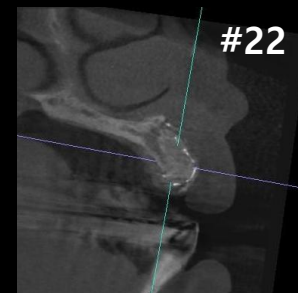
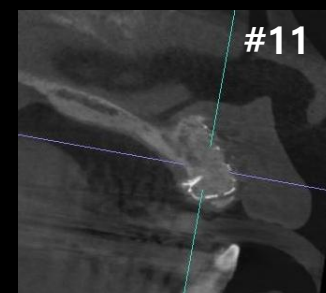
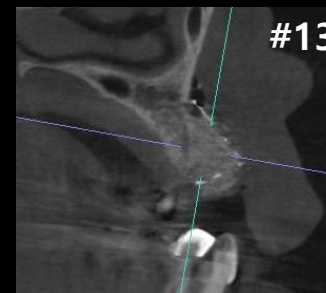
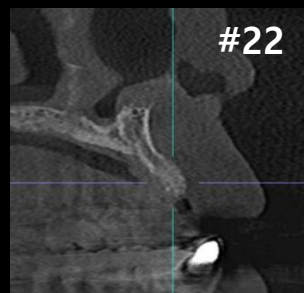
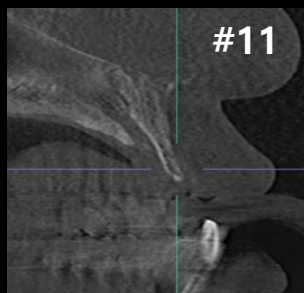
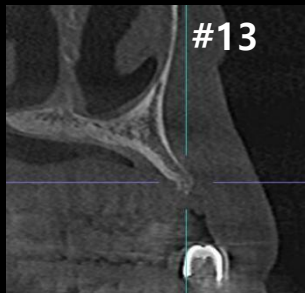
Dr.Byoung Kyou Park

2025. 05. 16(FRI.)



[Case Preview]

Soft Tissue Management After Extensive
Bone Grafting in the Esthetic Zone



Patient Information

Age : 53

Sex : Female

Chief Complaint

I would like to get implants to restore the broken teeth.

Past Dental History

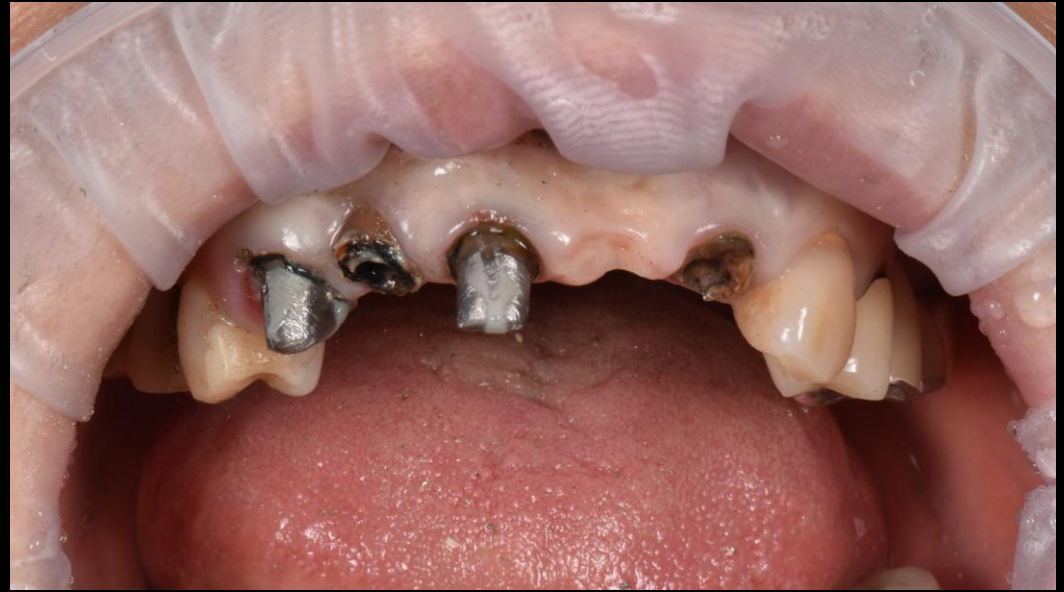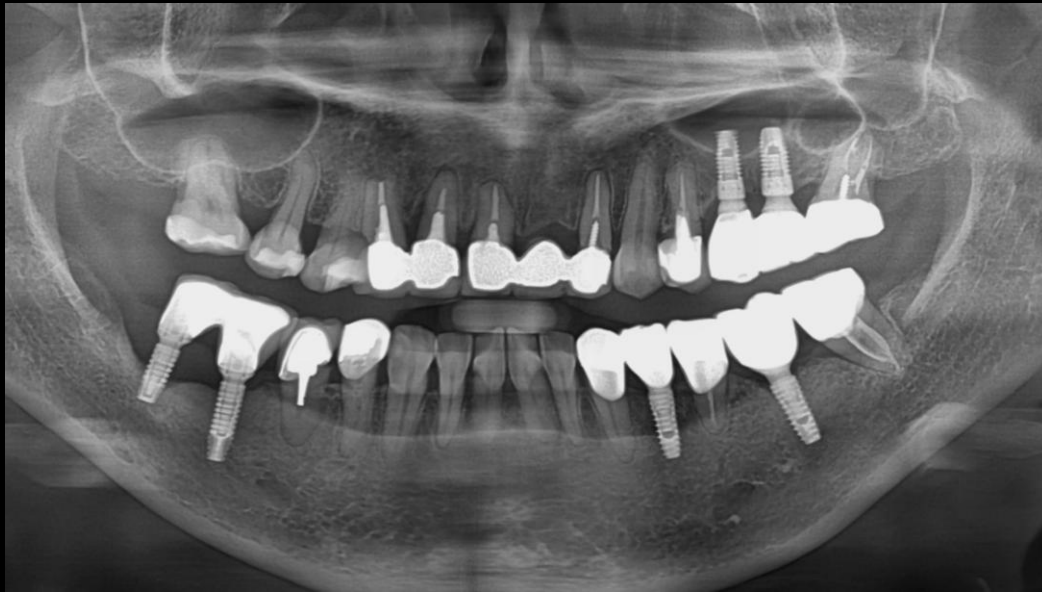- Old Cr Fracture (#13,12,11,21, 22)

Present illness

- #13,12,11,22 : Root caries
- #12,22 : Root rest state

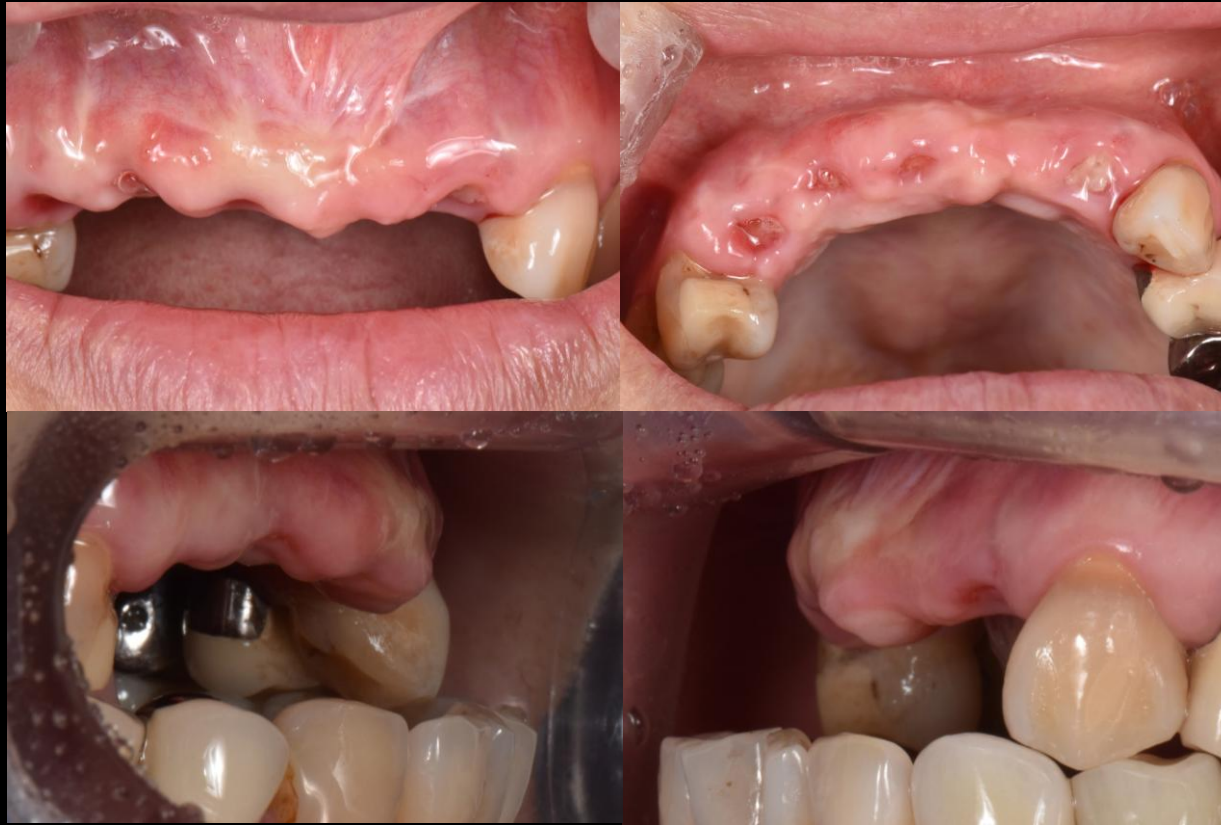Pt. Ham (53/Female)

Oral exam



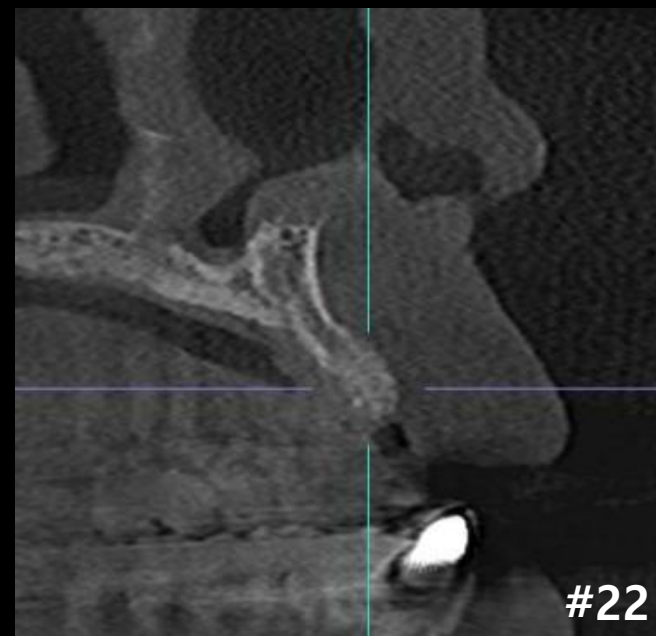
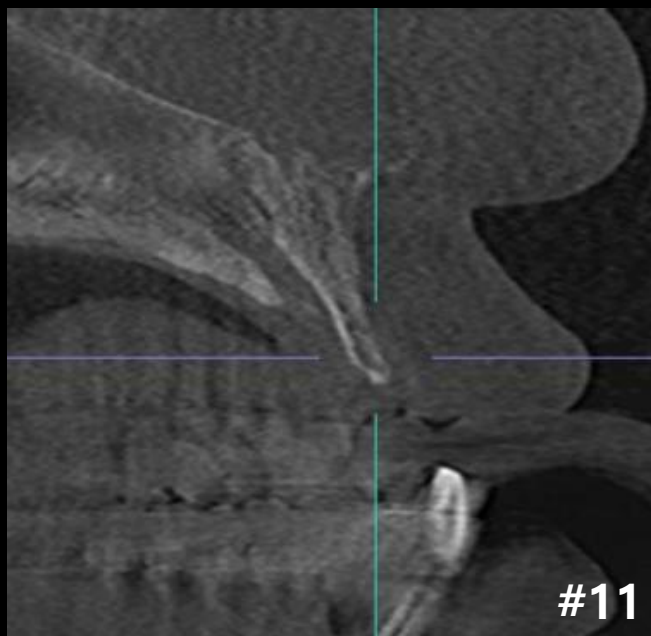
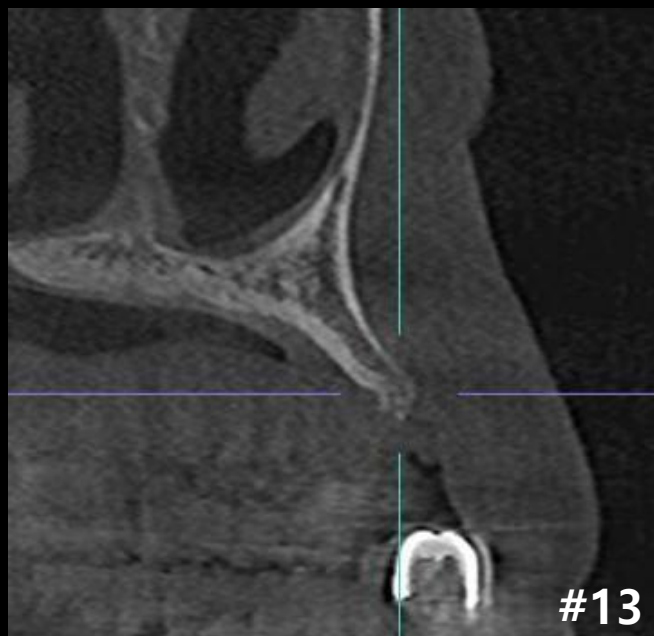
Pt. Ham (53/Female)

Pre-op



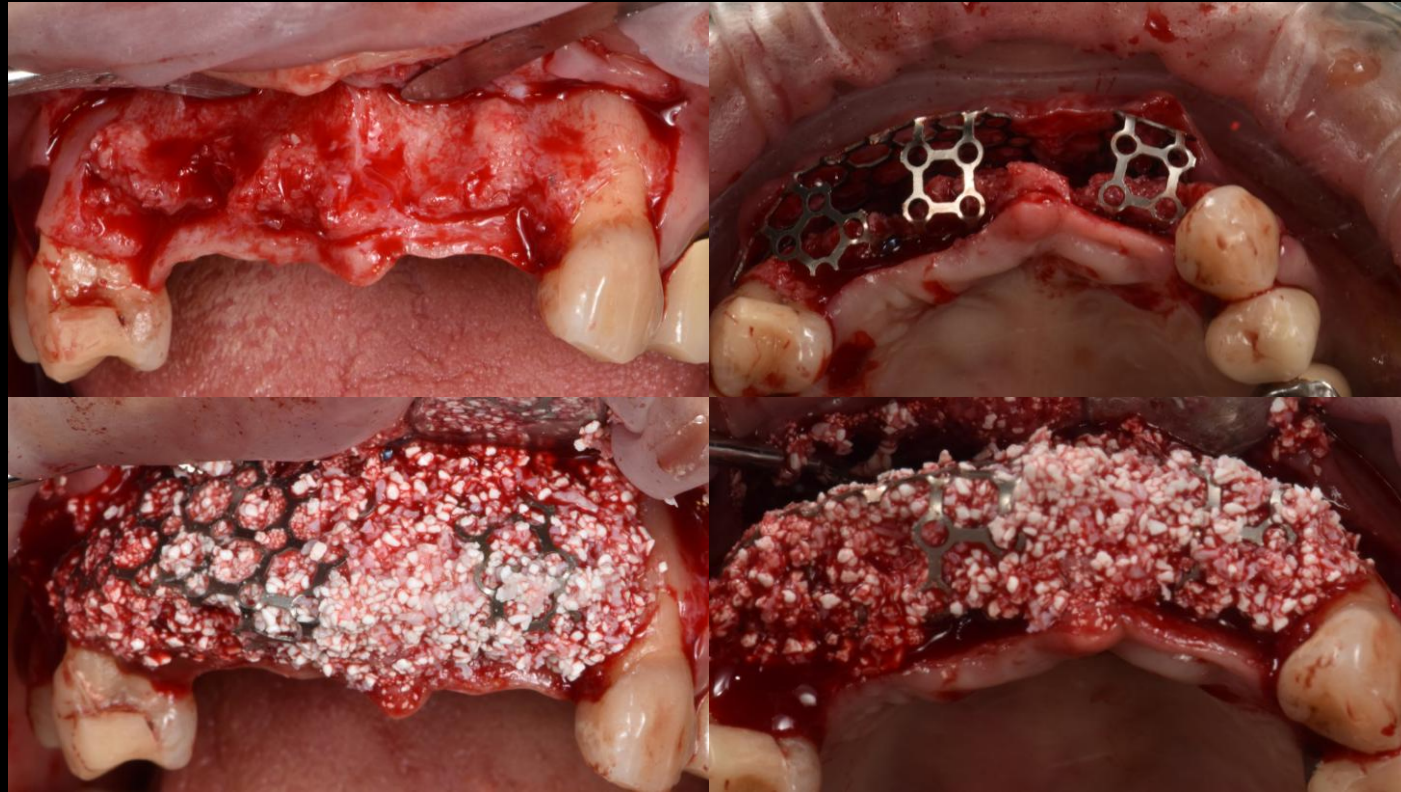
Pt. Ham (53/Female)

X ray exam



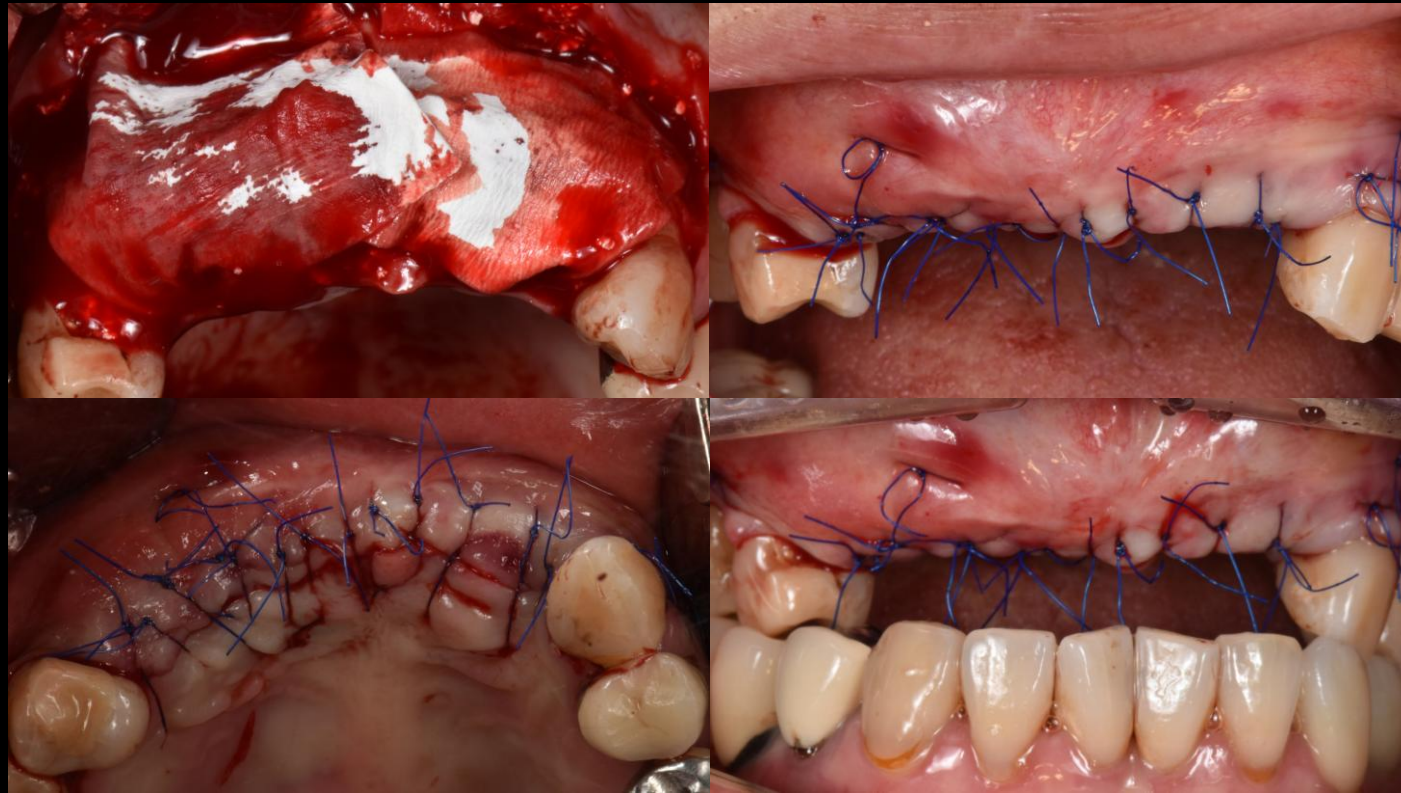
Pt. Ham (53/Female)

Pre-op



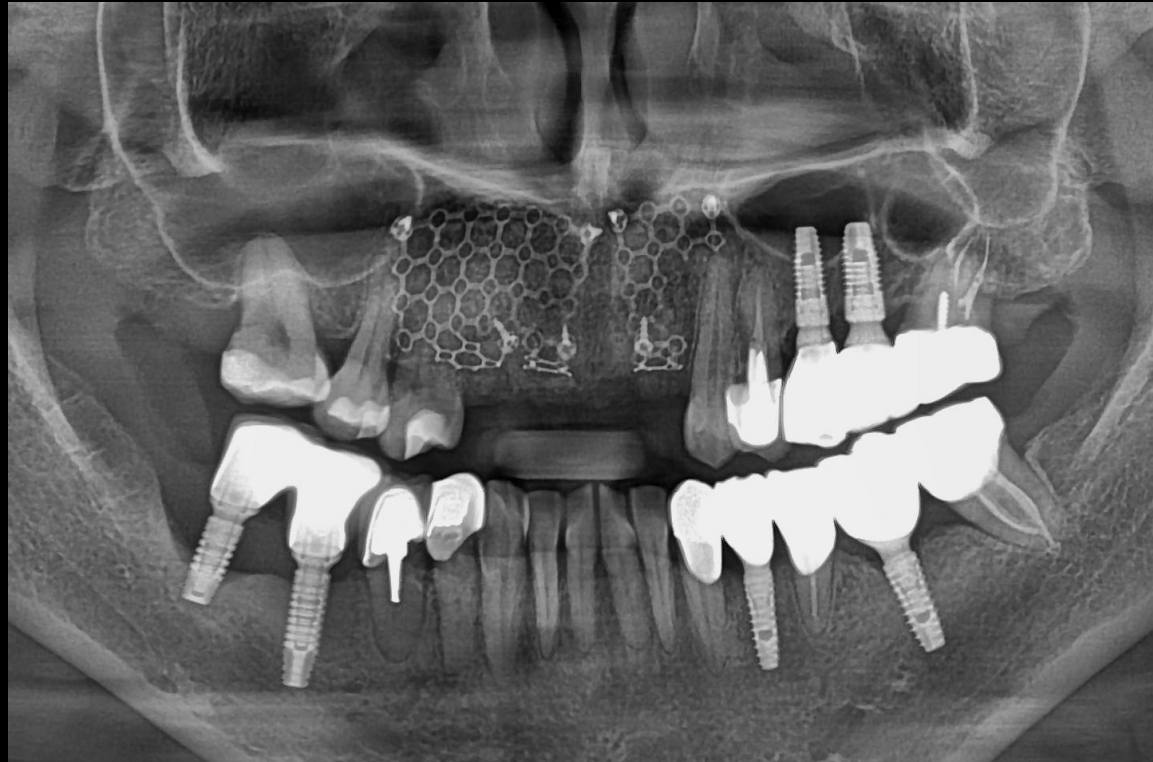
Pt. Ham (53/Female)

Pre-op



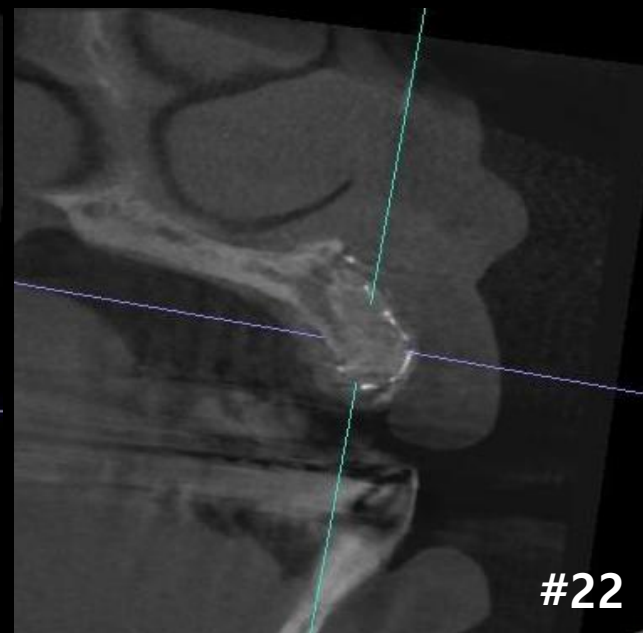
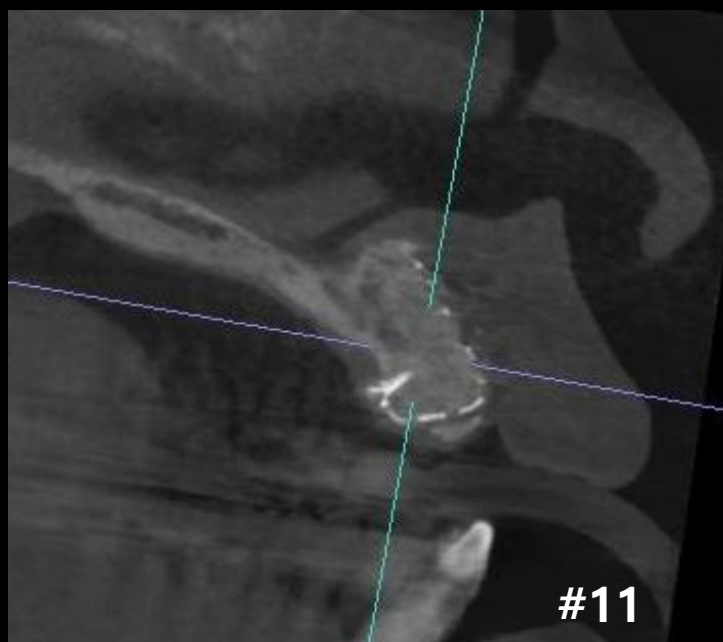
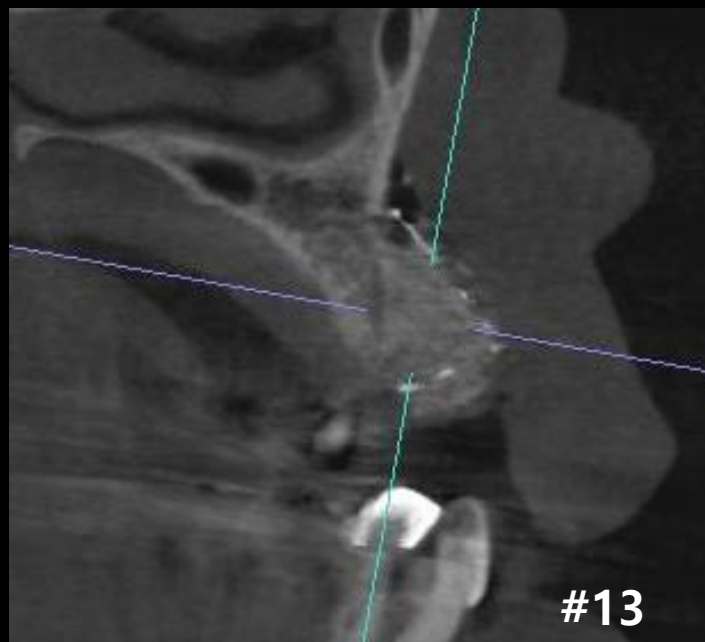
Pt. Ham (53/Female)

Pre-op



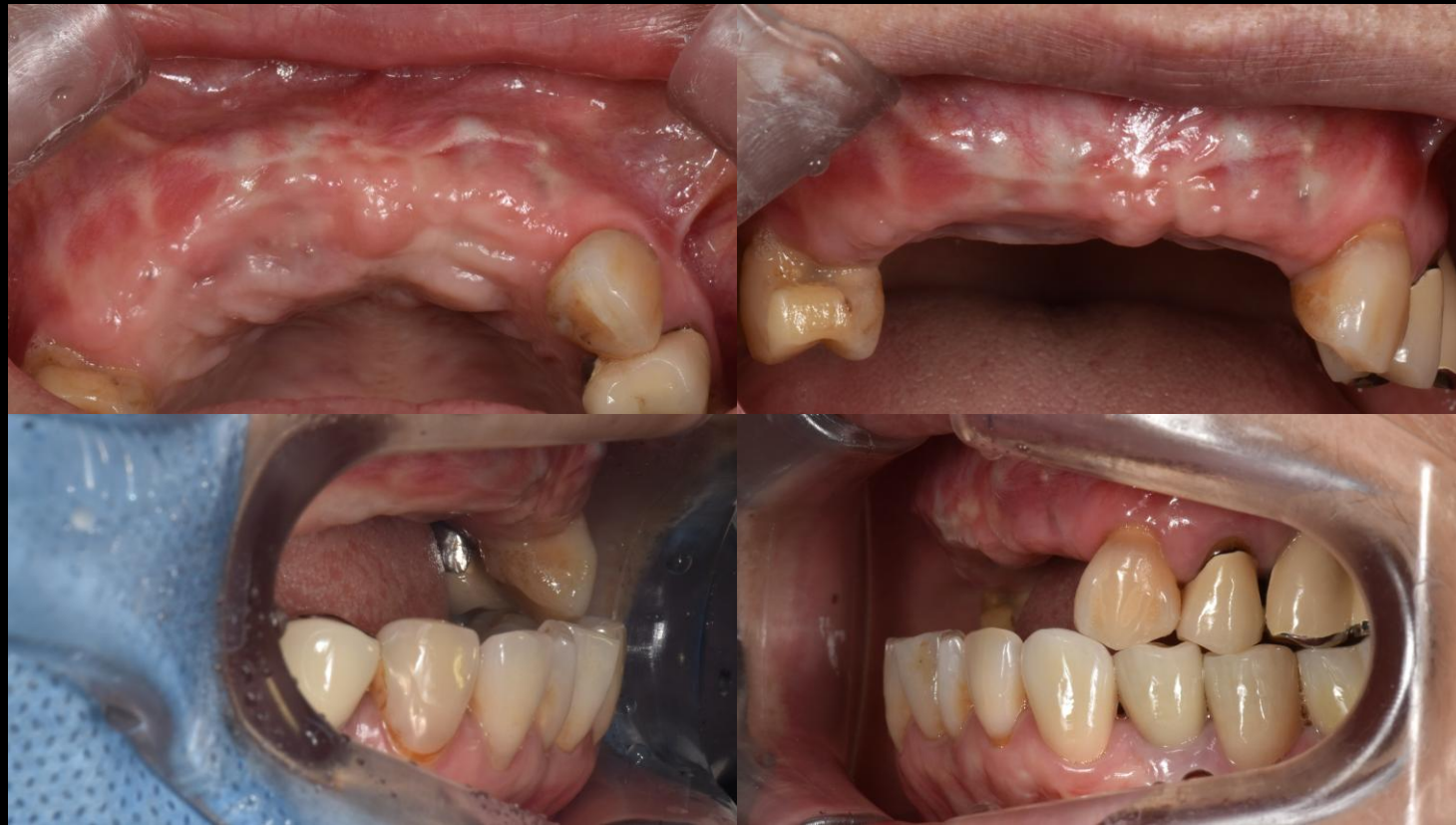Pt. Ham (53/Female)

Pre-op



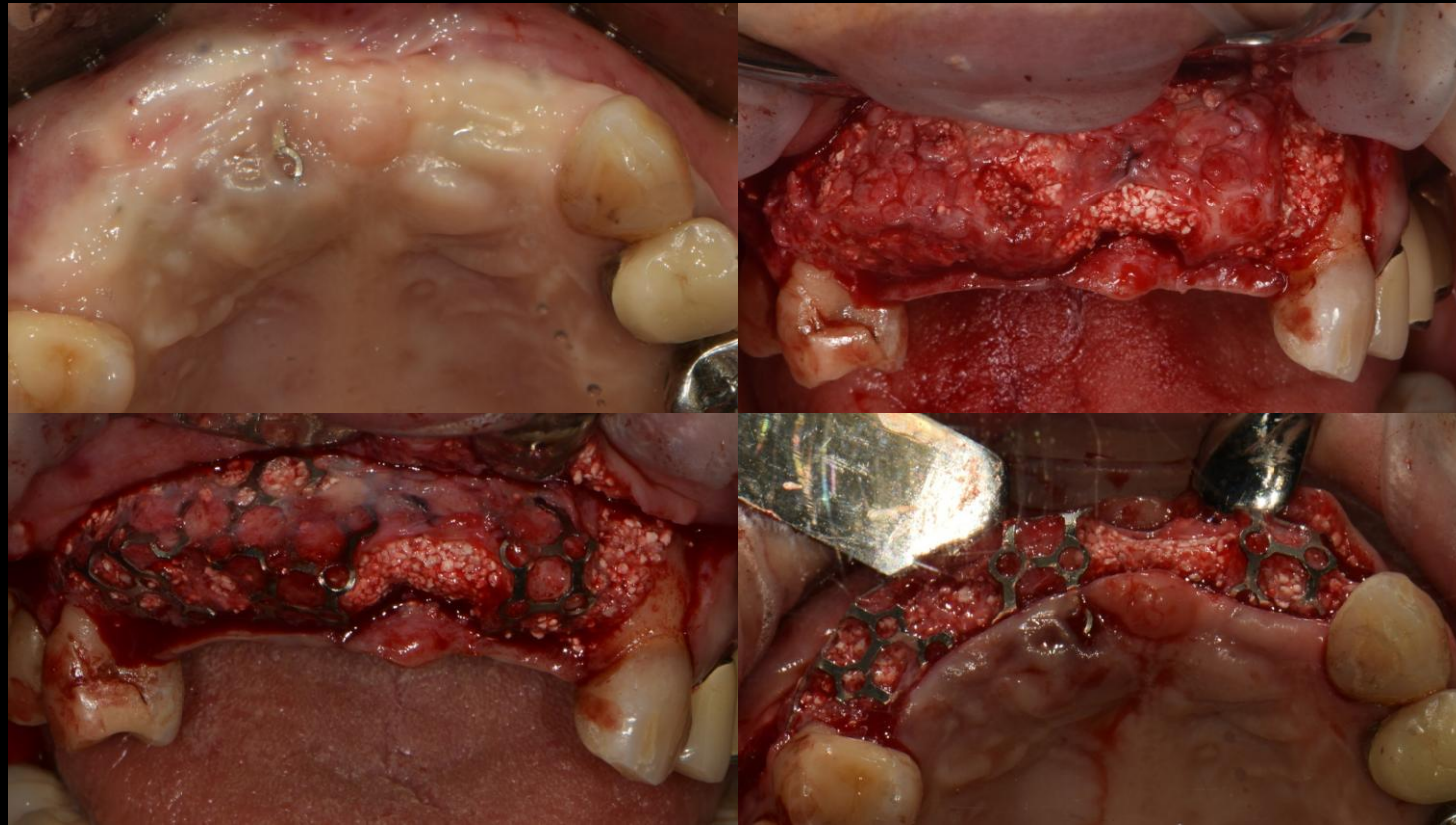
Pt. Ham (53/Female)

Pre-op



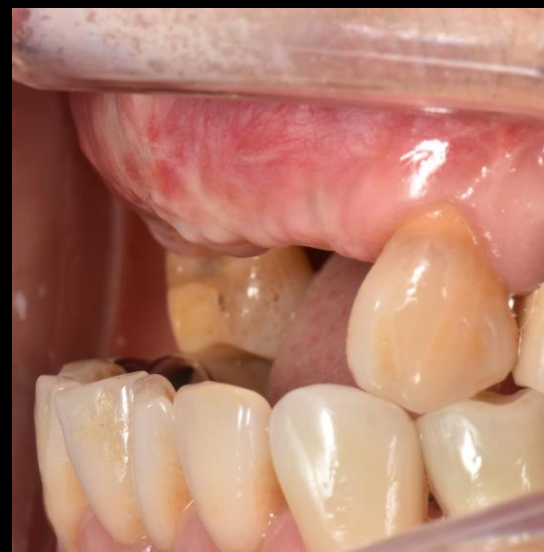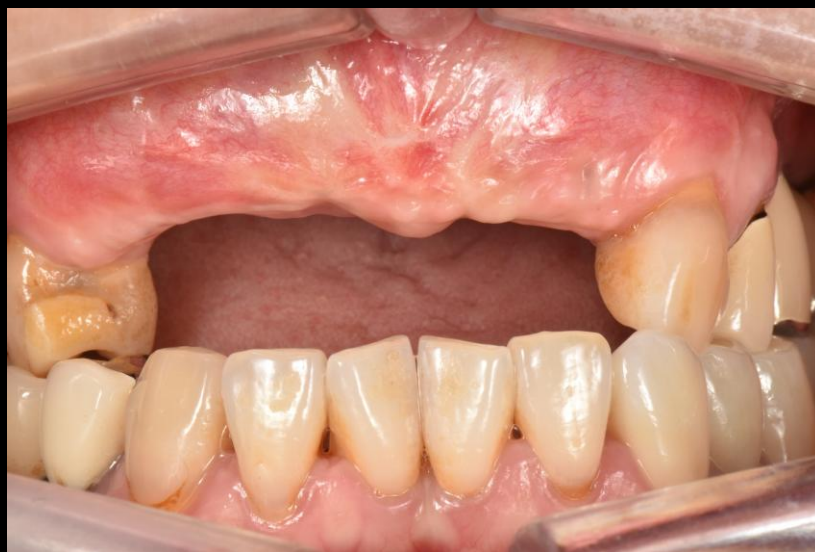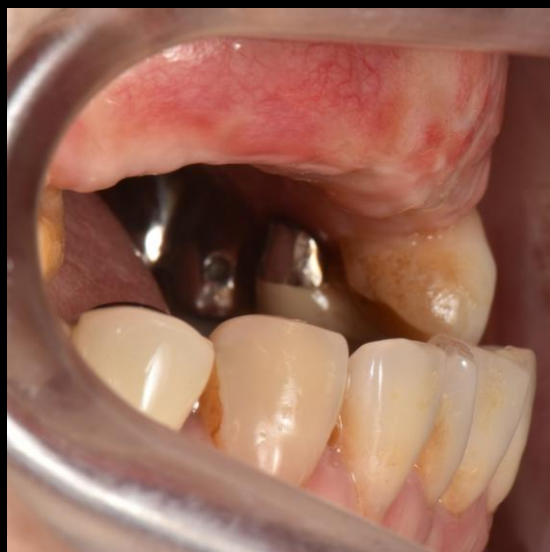Pt. Ham (53/Female)

5.5M Healing



Pt. Ham (53/Female)

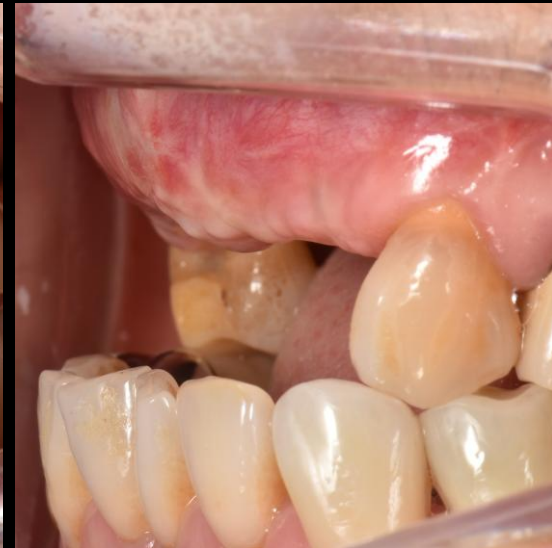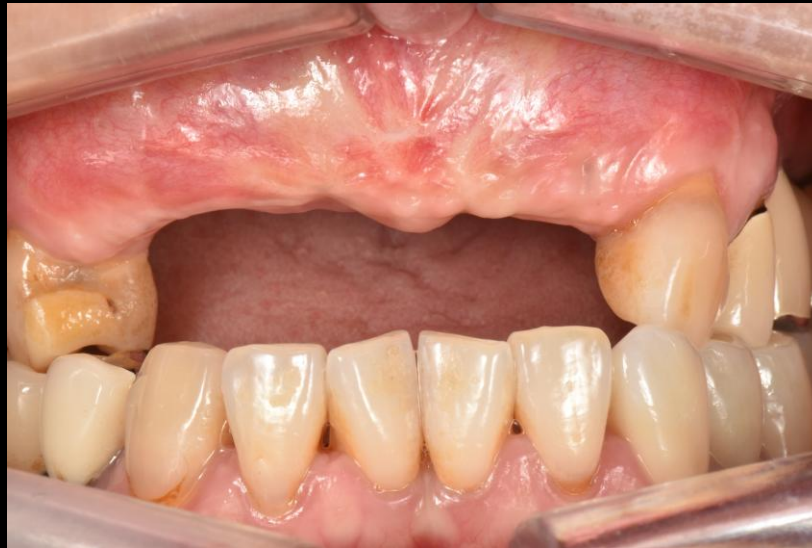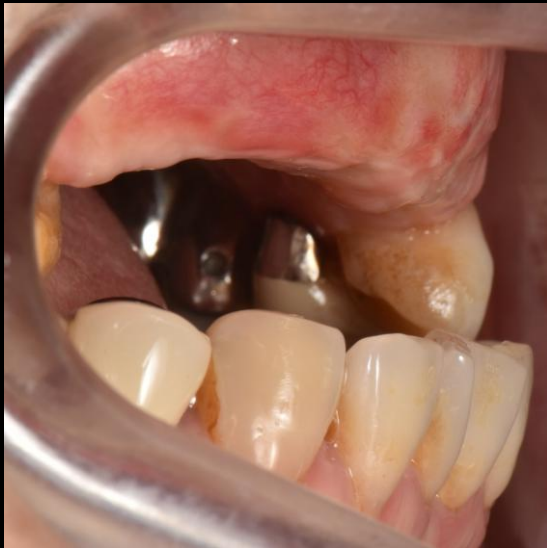Before today's surgery



Today's Surgery Plan

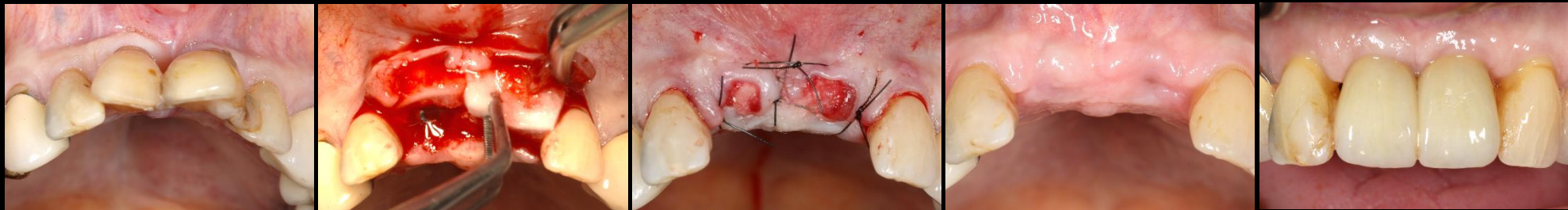
Surgical Plan

- Digital Guide Surgery (Flapless) with bright Surgical Lindemann kit
- Free Gingival Graft Alternative Using Collagen Graft 2



Collagen Graft 2


- Ridge preservation
- Porcine tendon derived type I collagen
- Faster soft tissue healing by epithelization



bright Tissue Level

For Simplify Surgical Procedure

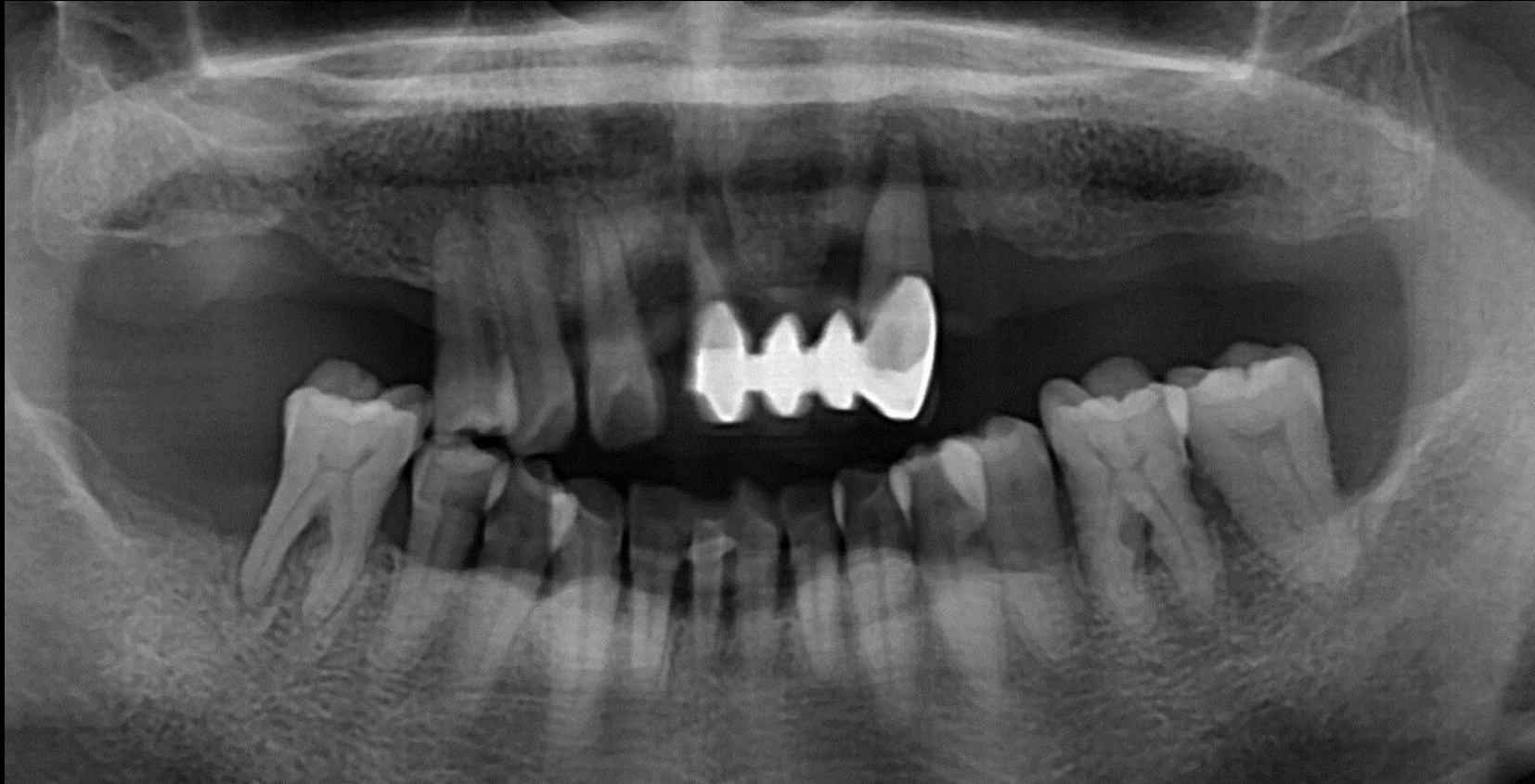- Thin, Deep & Sharp Thread
- Final Drill Only



Similar case

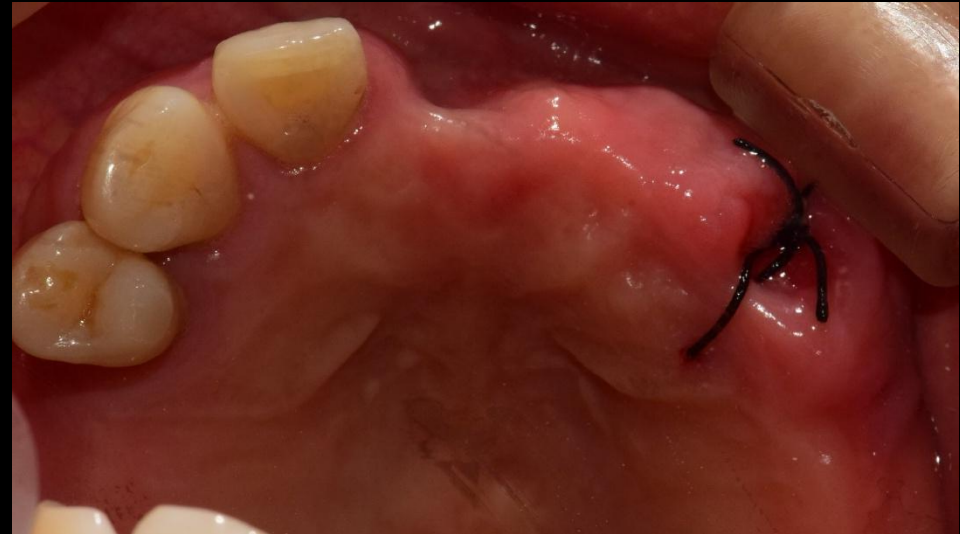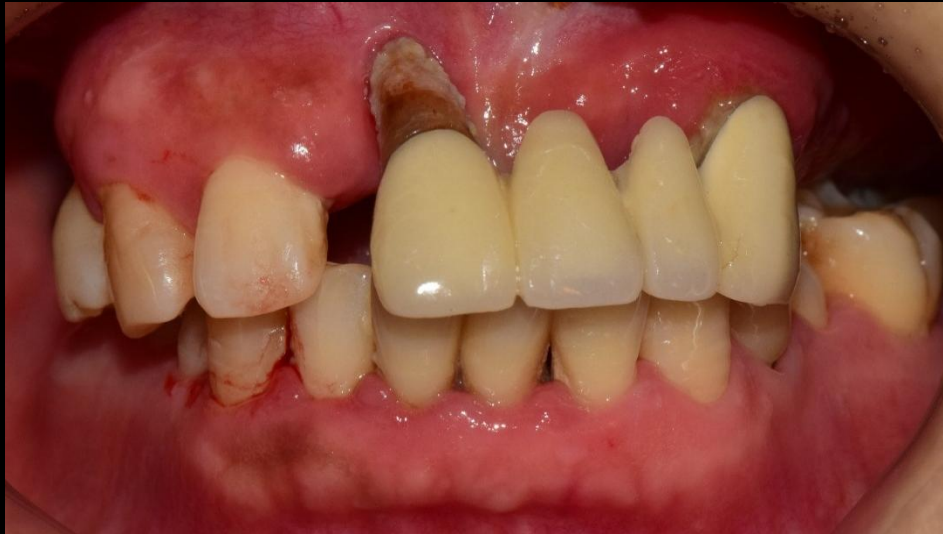Ridge split followed by APF case

Pre-op



Similar case

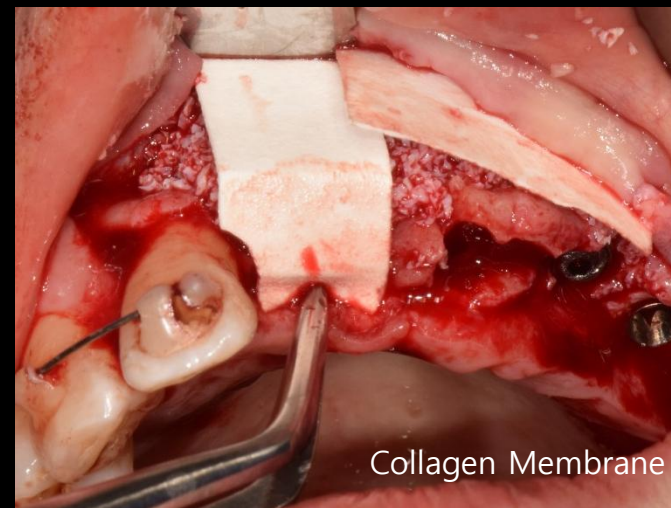
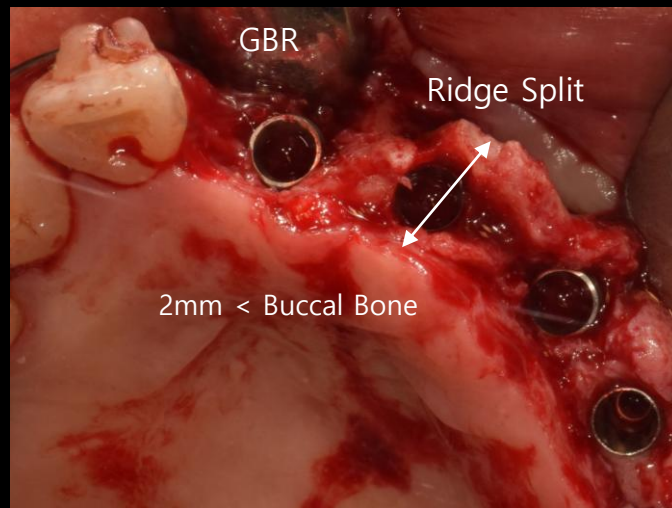
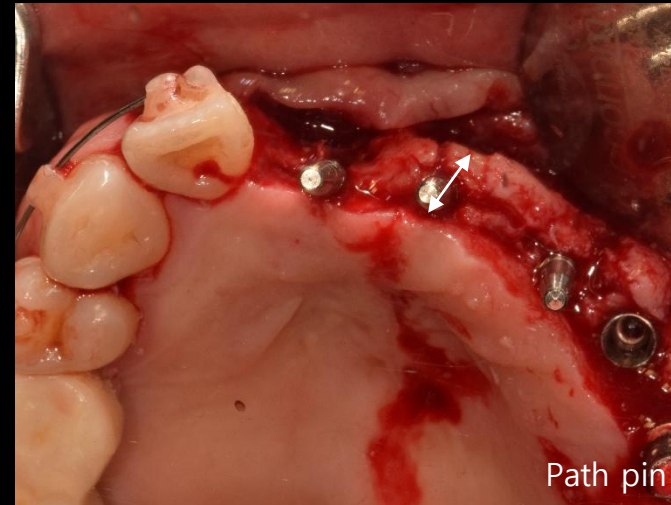
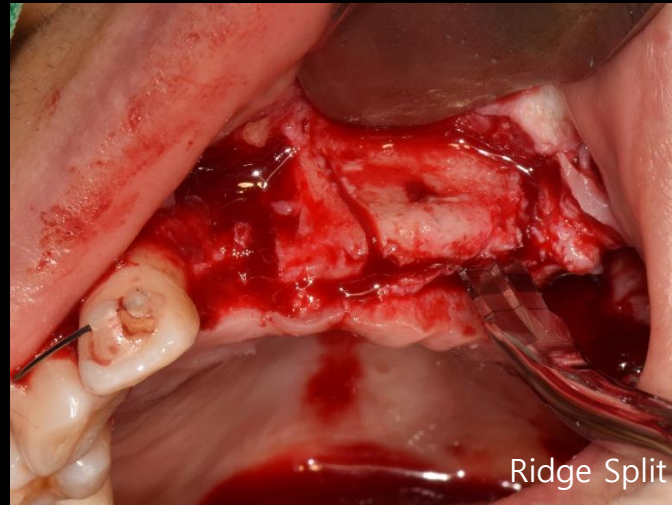Ridge split followed by APF case



Pre-op

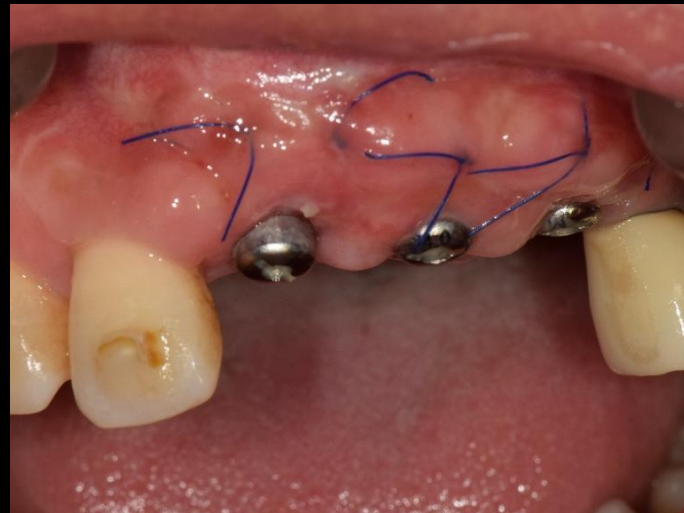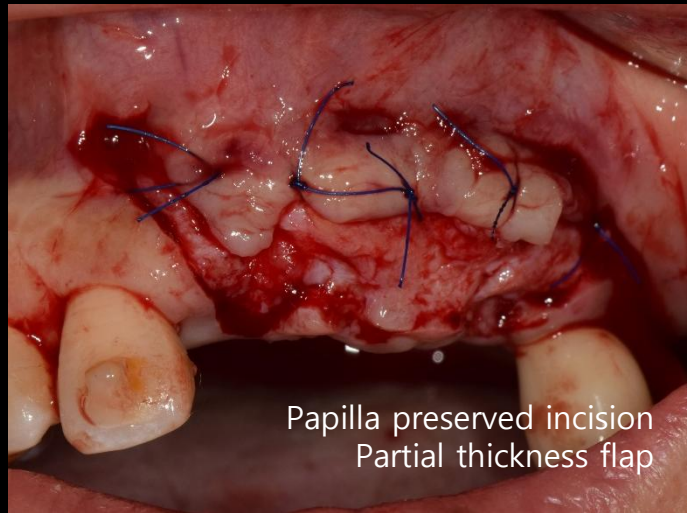
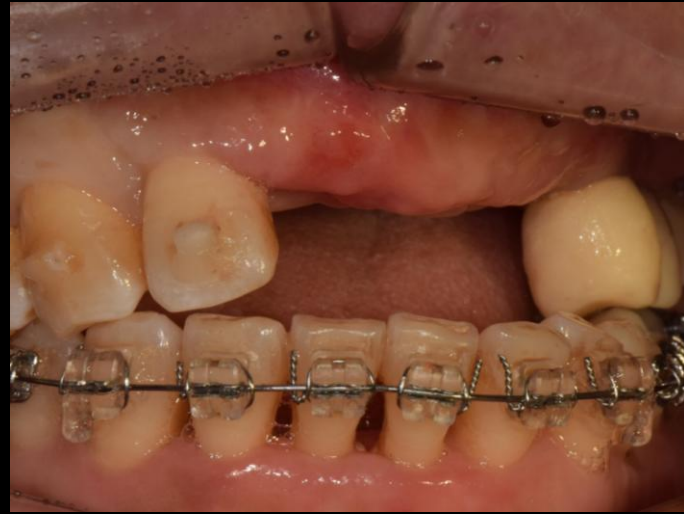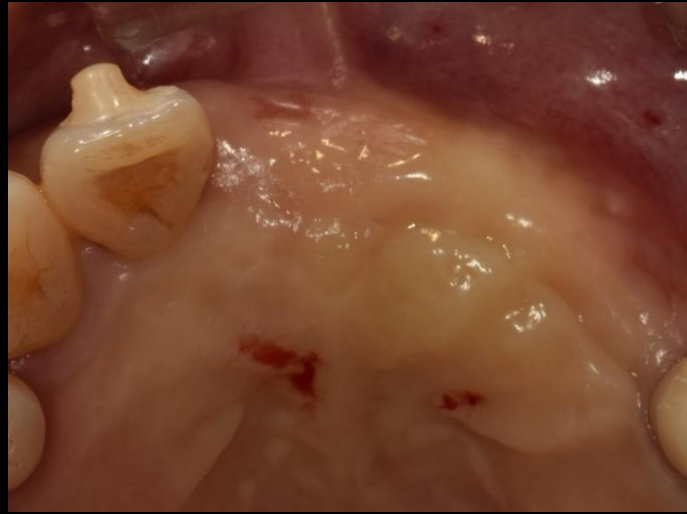
Similar case

Ridge split followed by APF case

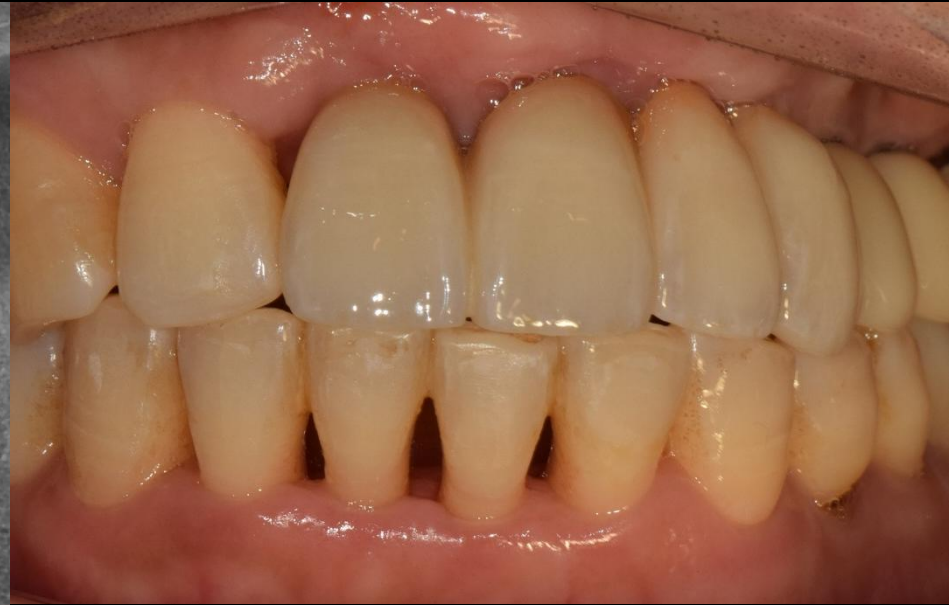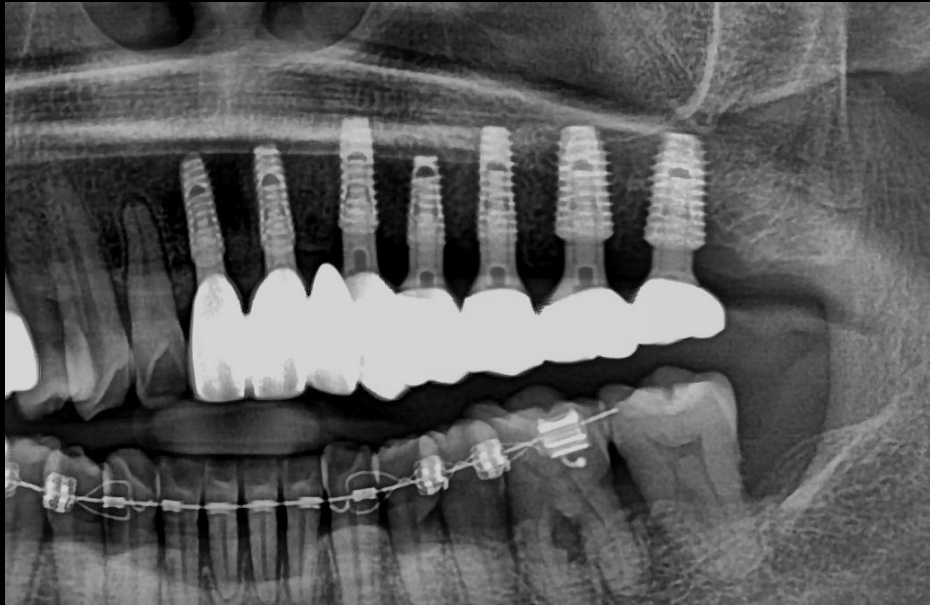


Similar case

Ridge split followed by APF case



Similar case



Post-op

