



**LIVE**

# Surgery

Prof. Soo-Hwan Byun

2021.09.24 (FRI.)



# [Case Preview]

Digital Guide Implant placement with GBR

# Patient Information

**Age** : 29

**Sex** : Female

## Chief Complaint

: My left facial is swelling(ER)

## Past Dental History

: Traffic accident 7 years ago

Numerous retained root and caries

Edentulous state at anterior mandible

## Past Medical History

N/S

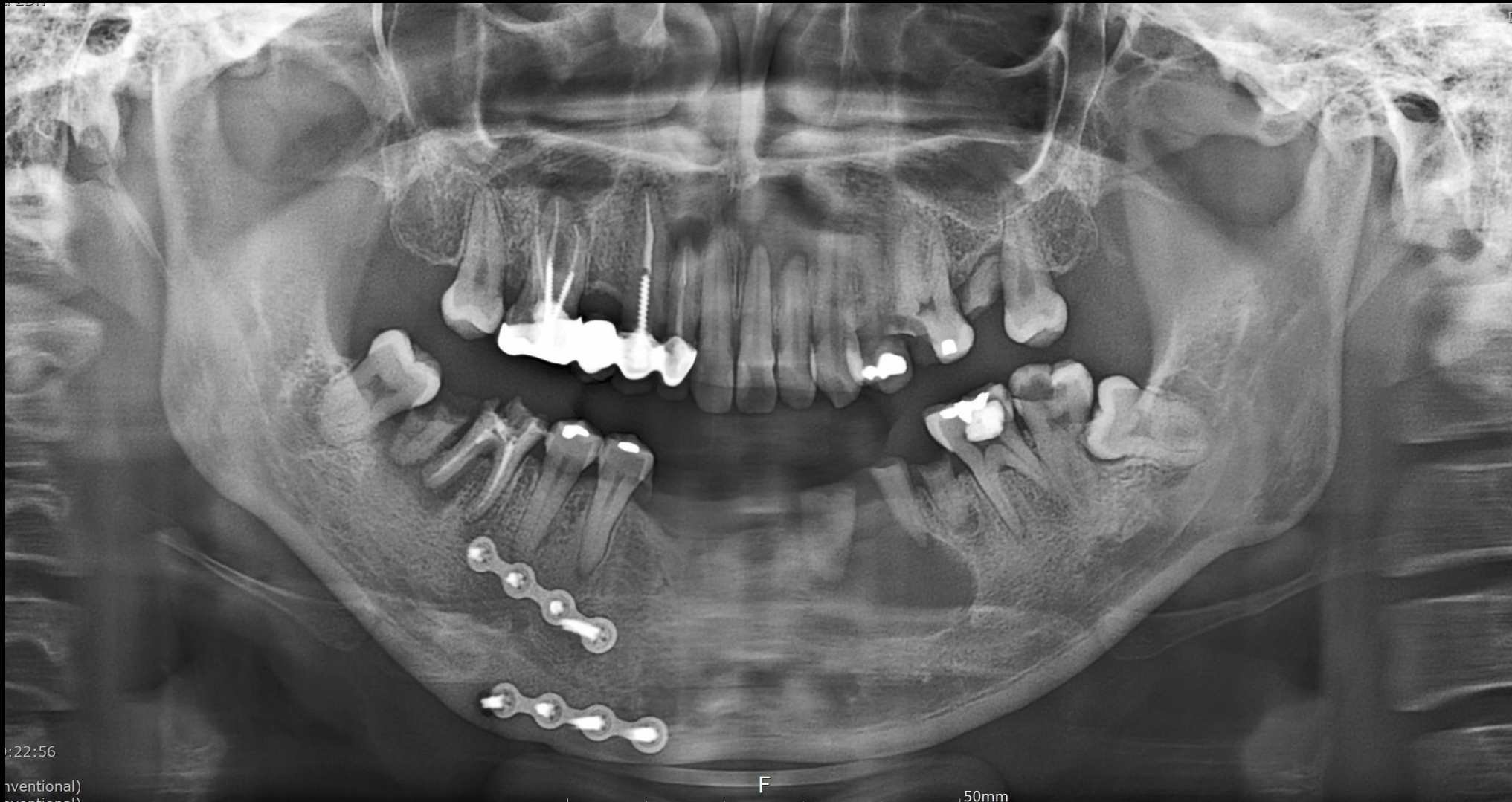## Systemic diseases

N/S



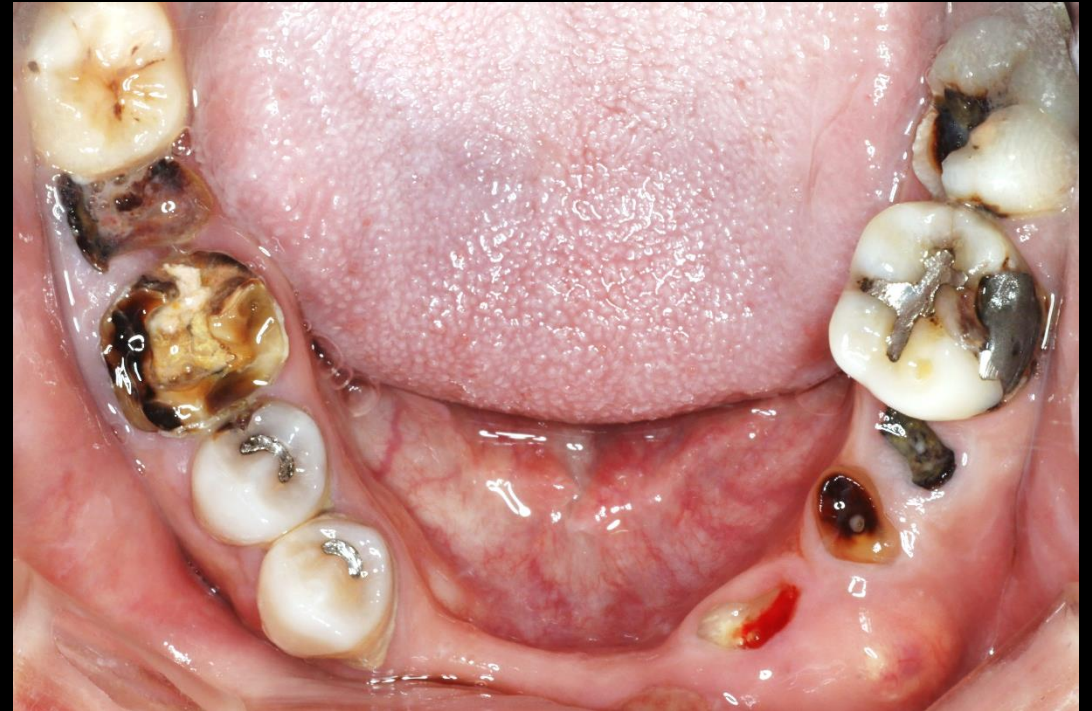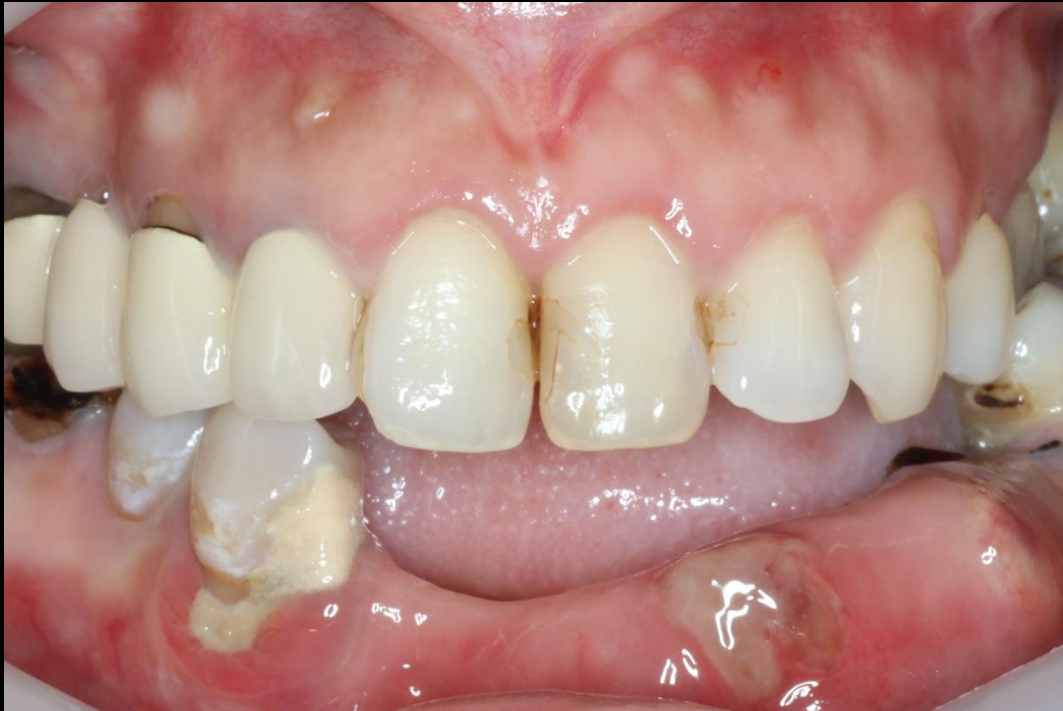# Past dental history

Oral exam (2021-03-02)



## Past dental history

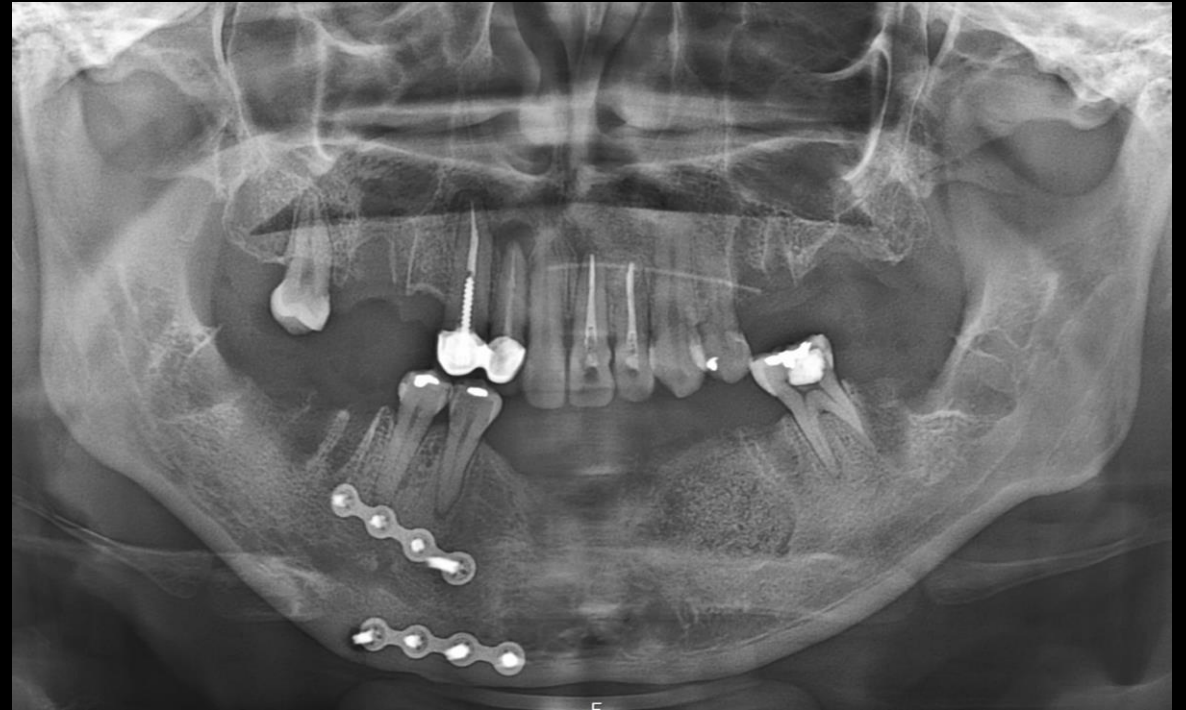
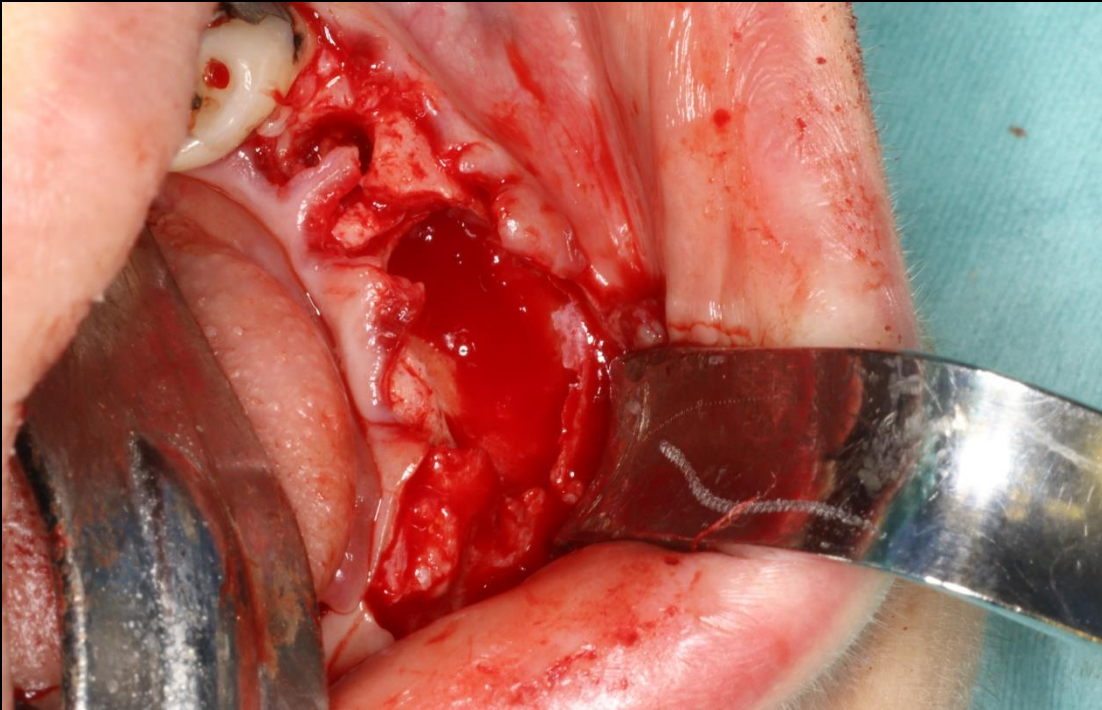
Oral exam (2021-03-02)





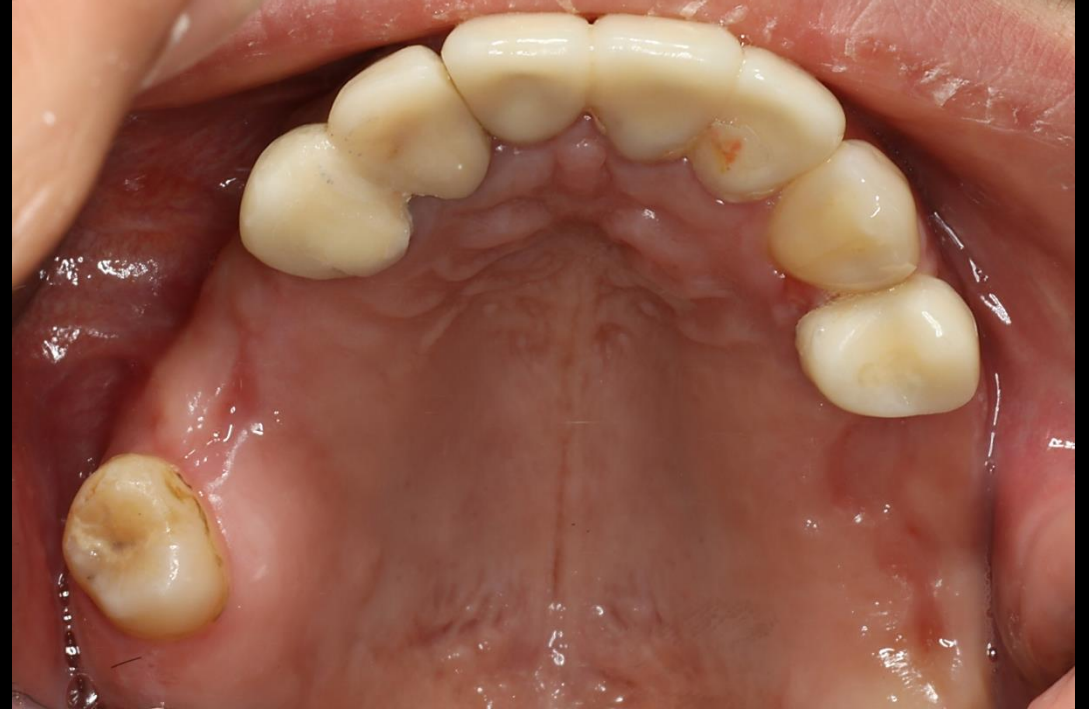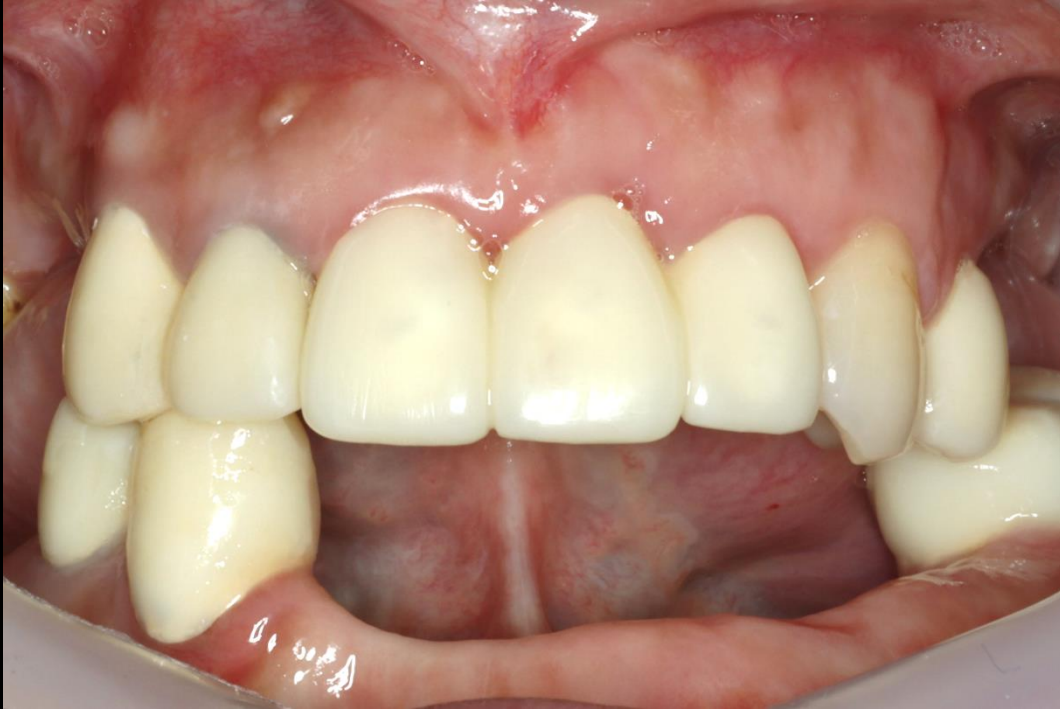## Past dental history

- Cyst enucleation of #21-22, #33-35 (2021-04-09)
- #16,#26-28,#33-38,#46-48 Extraction
- #33-35 Bone graft



## Past dental history

(2021-06-03)

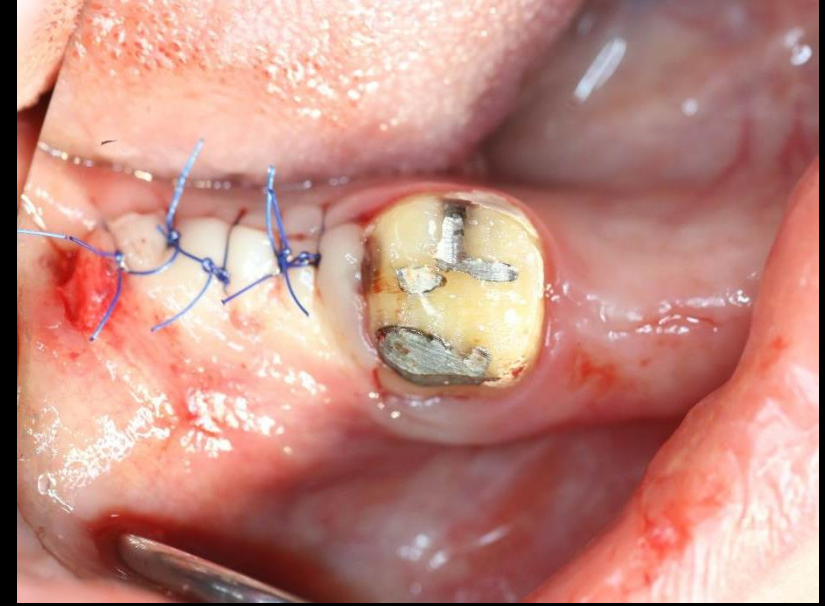
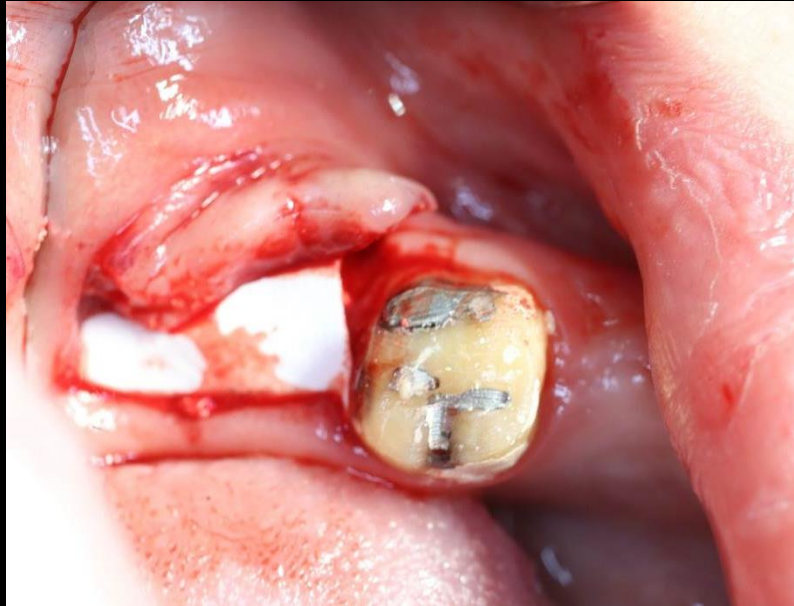
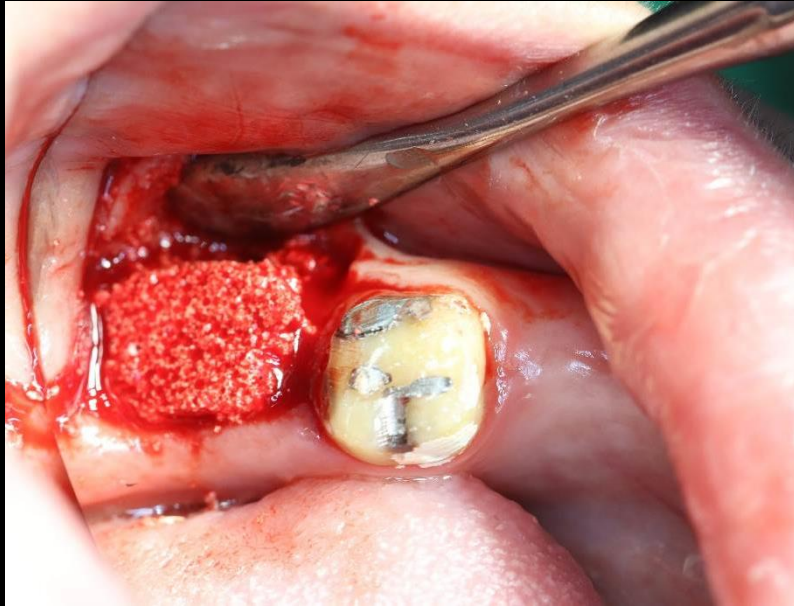


## Past dental history

- #37 vertical augmentation with OSTEON3 Block

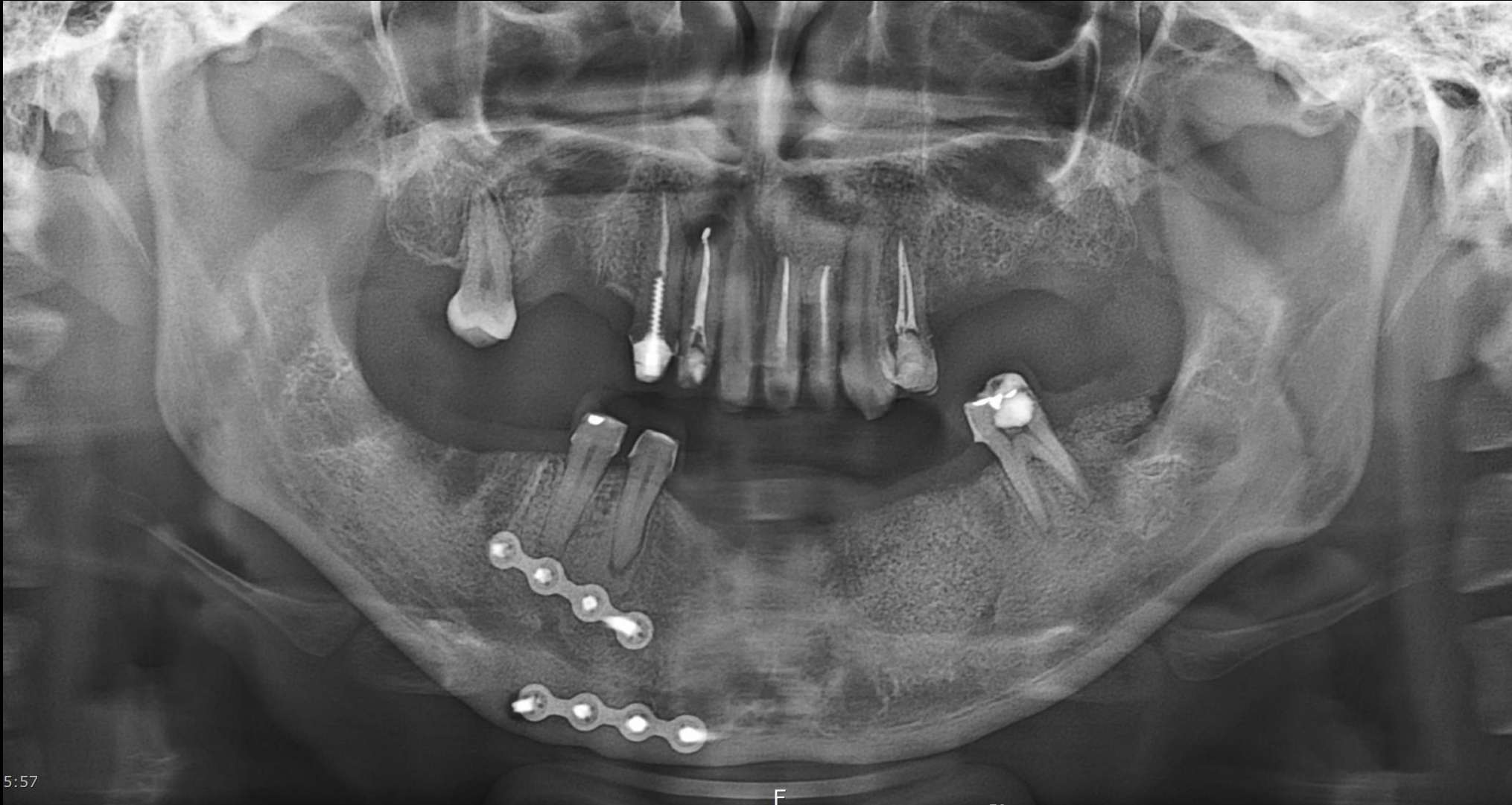
#37 (2021-06-22)





## Past dental history

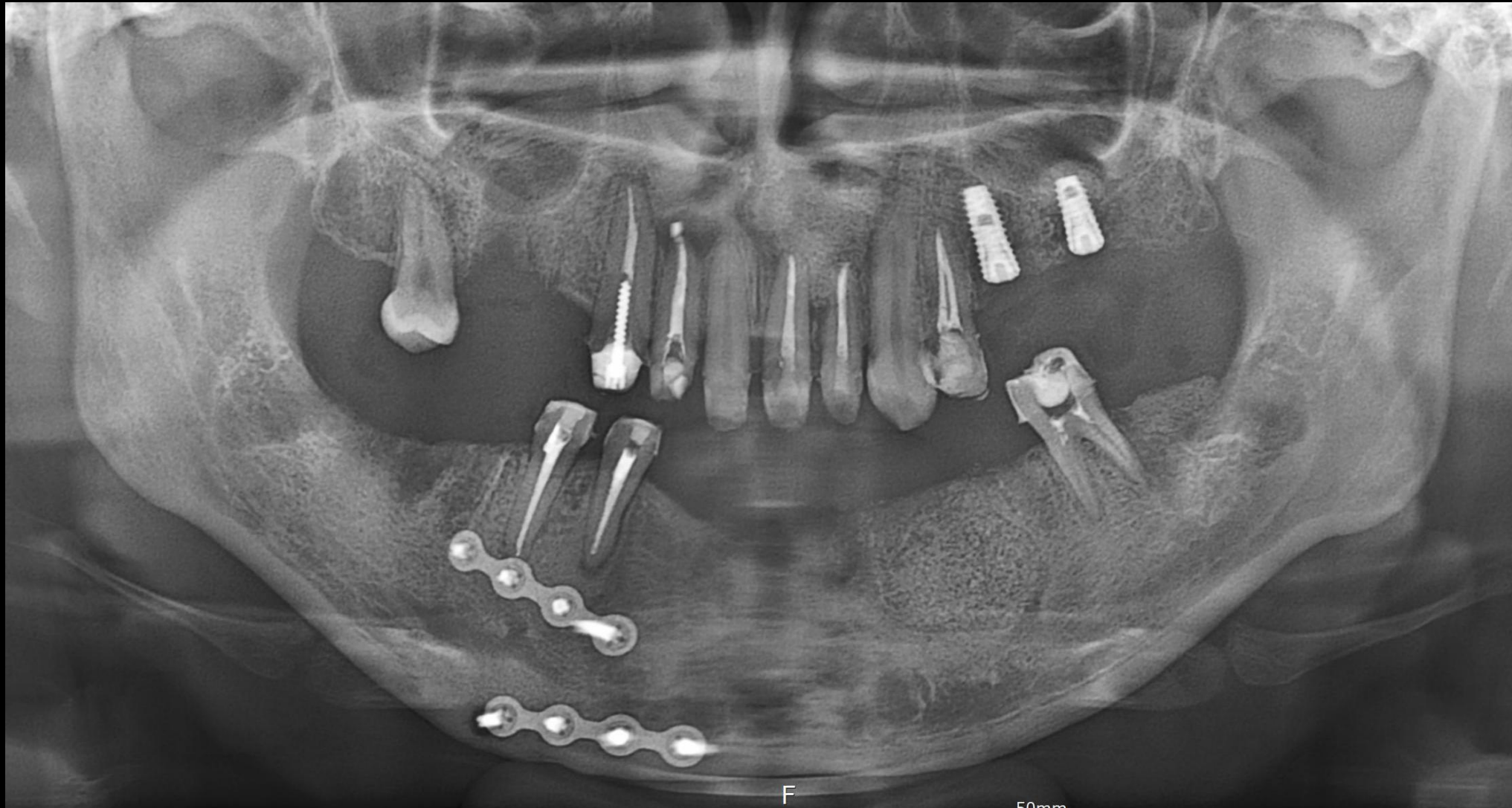- #37 vertical augmentation with OSTEON3 Block



## Past dental history

- #26, 27 Implant placement

(2021-07-20)

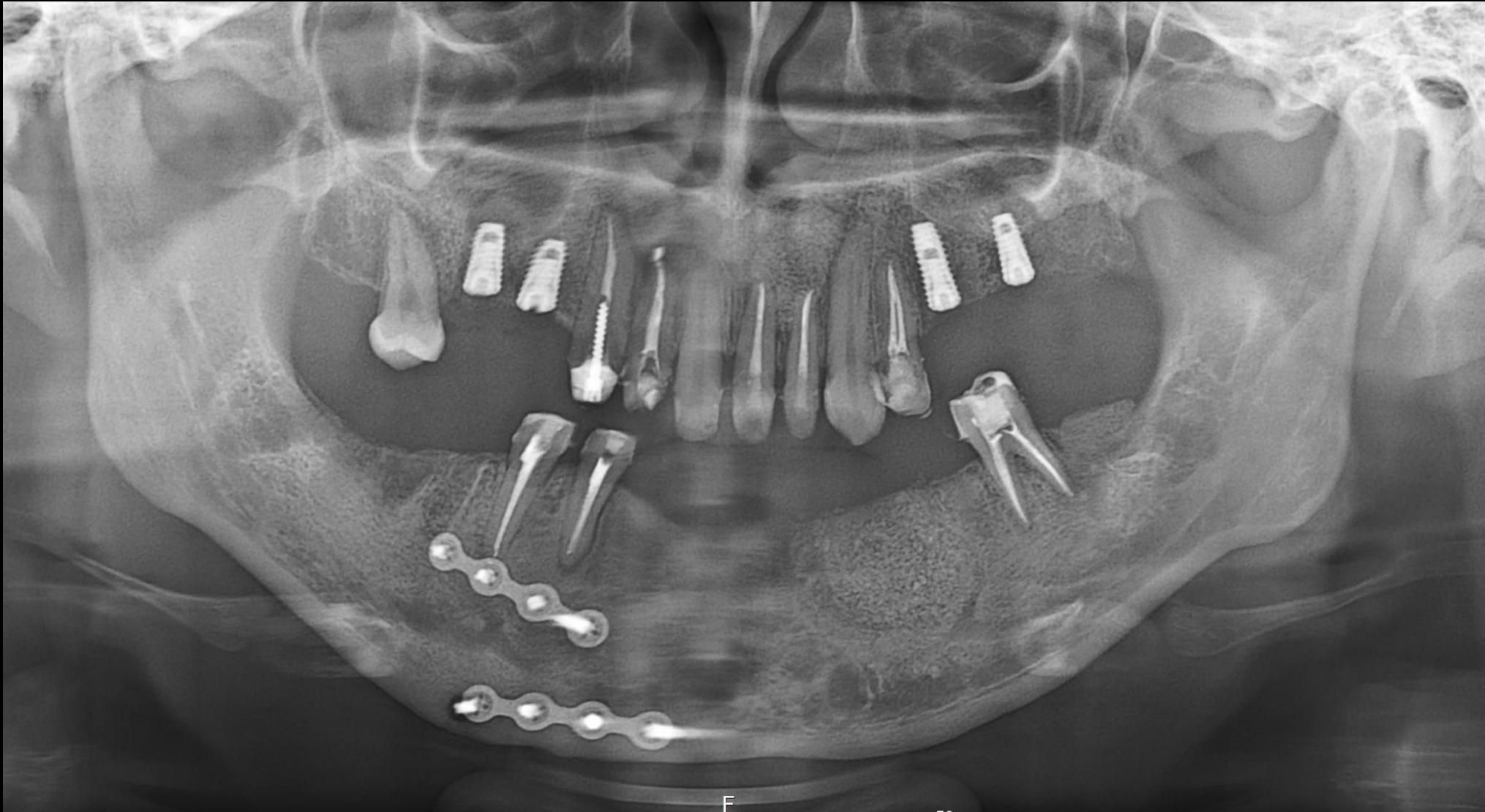



## Past dental history

- #15, 16 Implant placement

(2021-08-31)

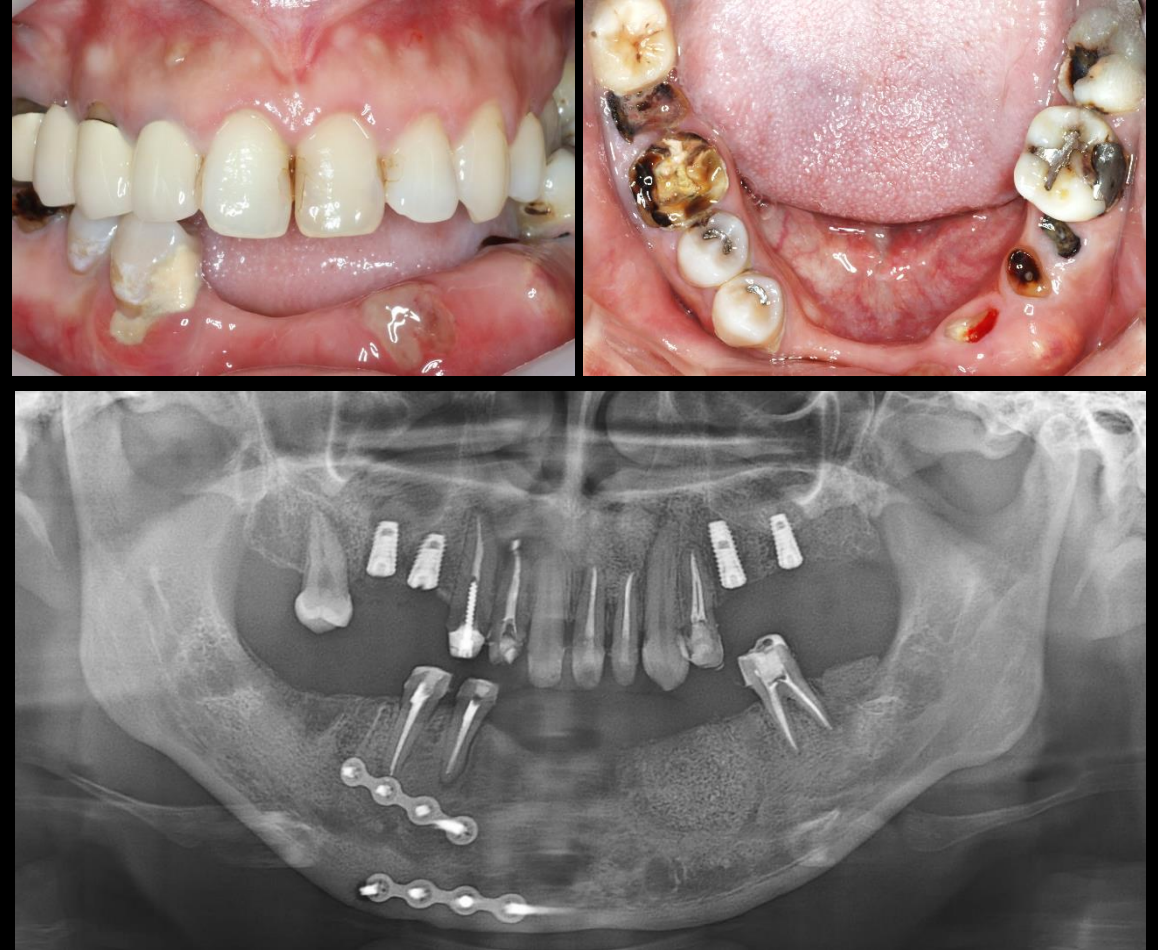




# Today's Surgery Plan

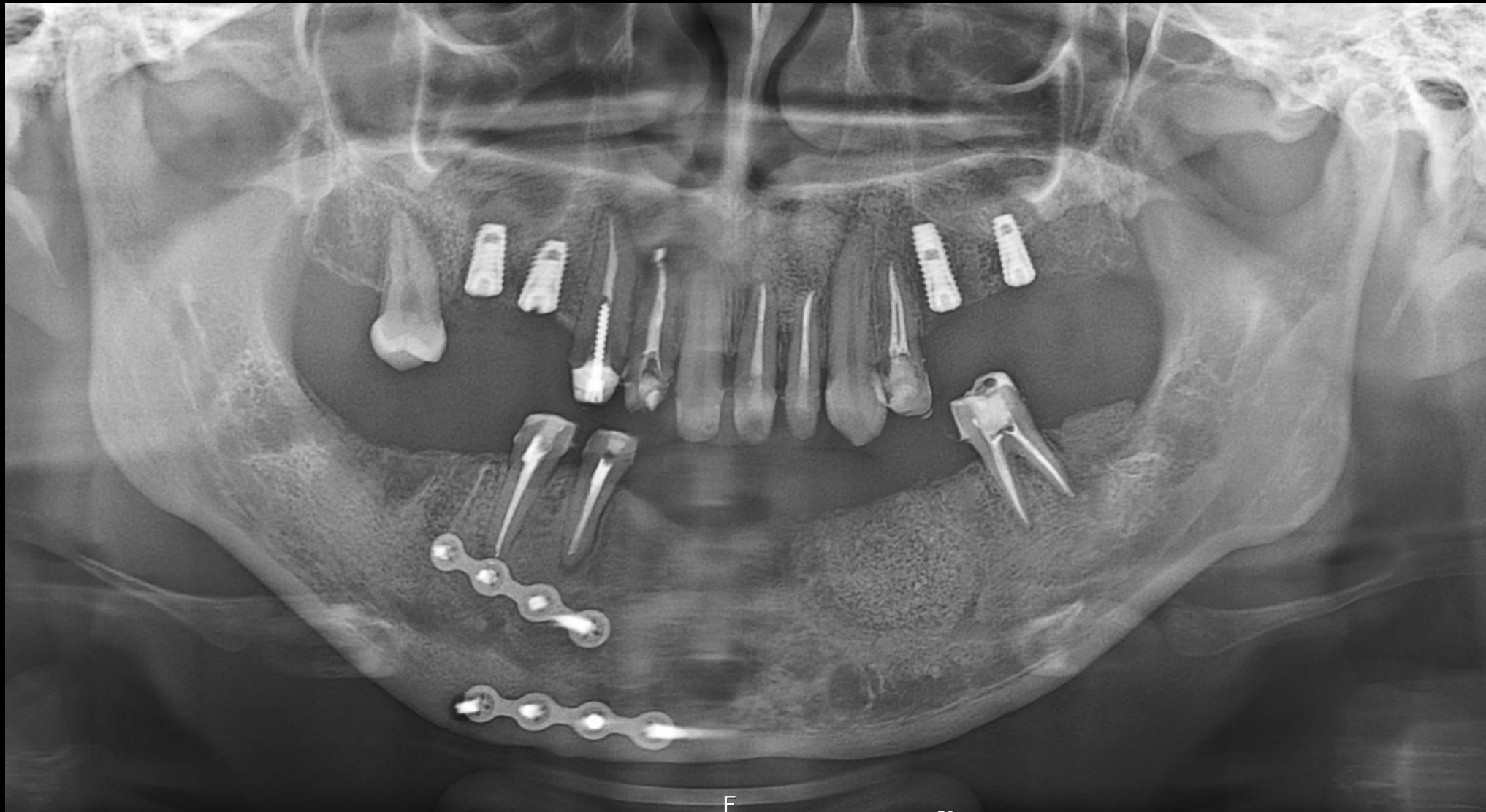**#47, 46, 43, 33, 35**

- Implant placement by using Dentium digital guide system
- Simultaneous GBR



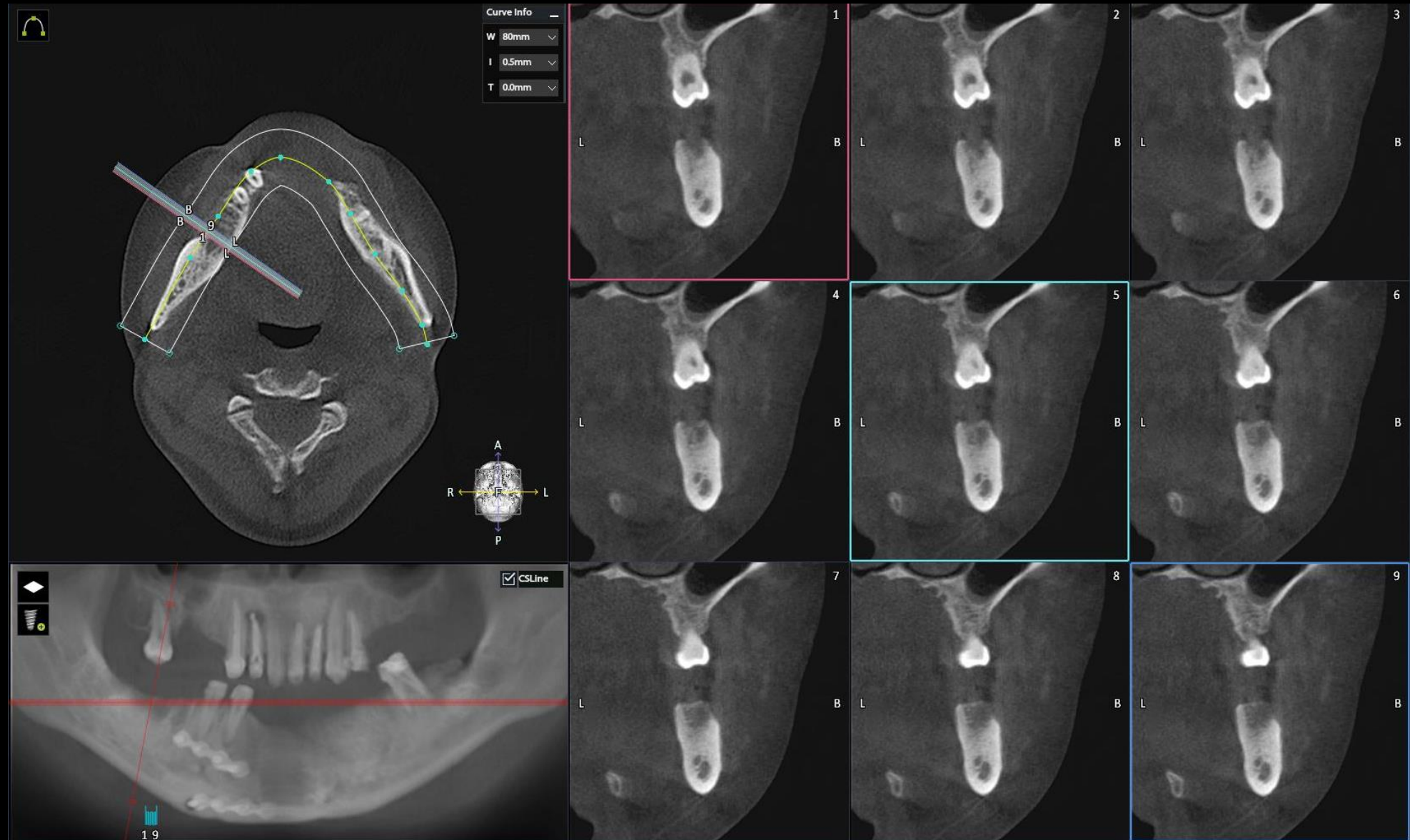
Pt. Yu (29/Female)

Pre-op (2021-08-31)



Pt. Yu (29/Female)

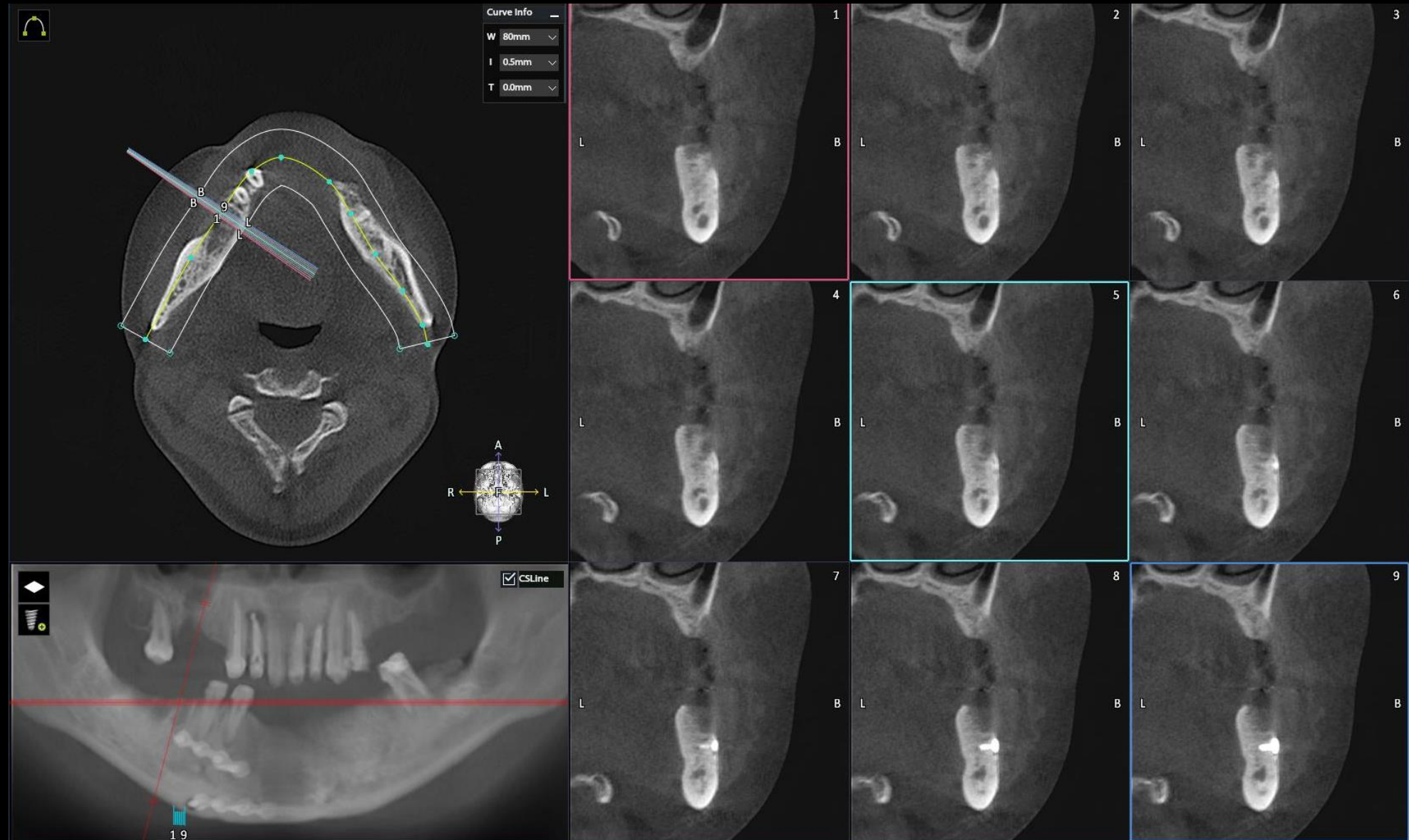
#47 Pre-op (2021-06-22)





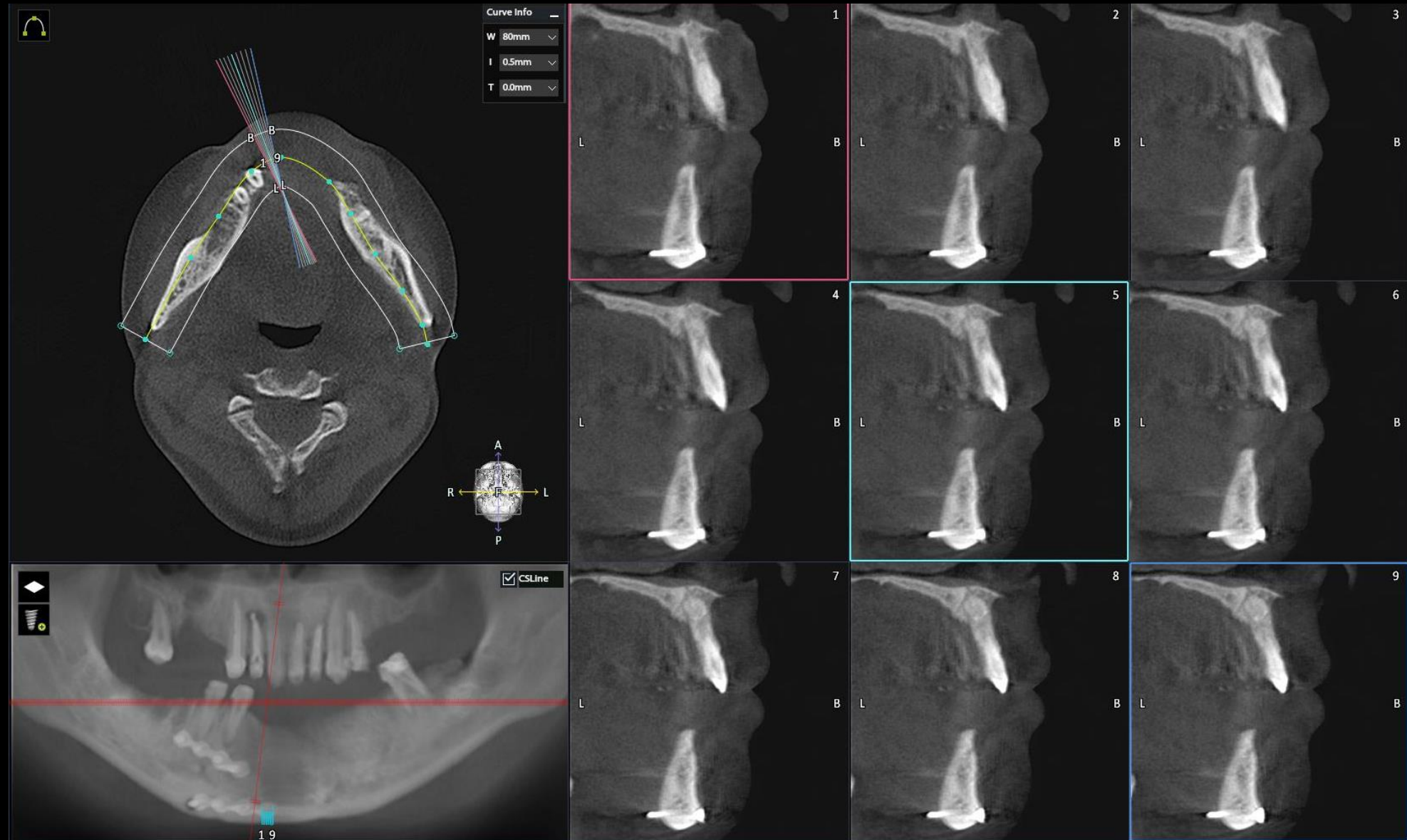
Pt. Yu (29/Female)

#46 Pre-op (2021-06-22)



Pt. Yu (29/Female)

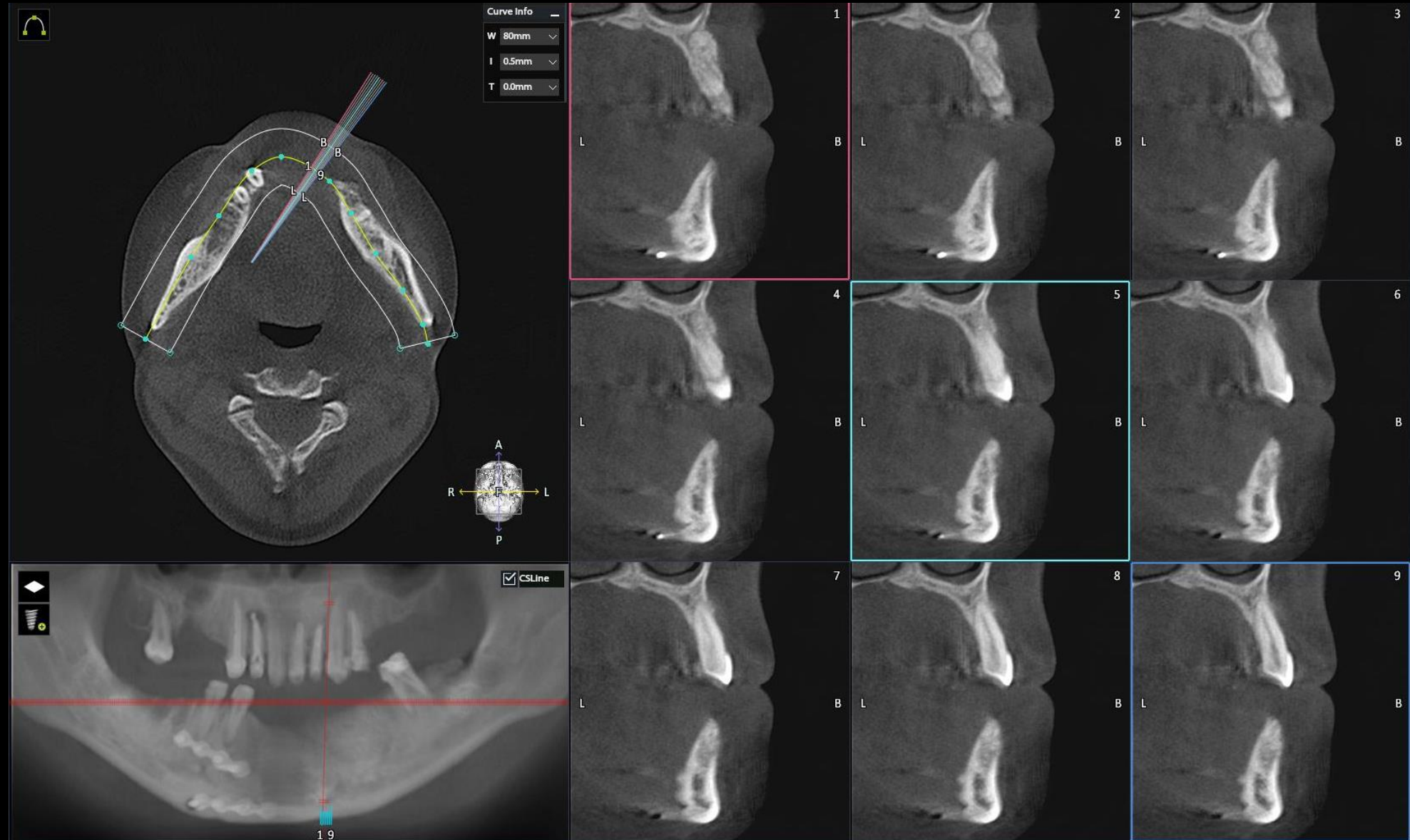
#43 Pre-op (2021-06-22)





Pt. Yu (29/Female)

#33 Pre-op (2021-06-22)





Pt. Yu (29/Female)

#35 Pre-op (2021-06-22)

